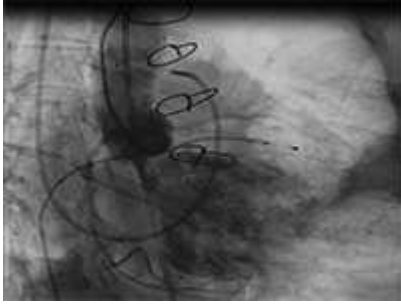


Video Legend.

Video. Caval-aortic access and TAVR. A sequence of annotated videos demonstrates caval-aortic access and TAVR in patient #1.

ACCEPTED MANUSCRIPT



ACCEPTED MANUSCRIPT