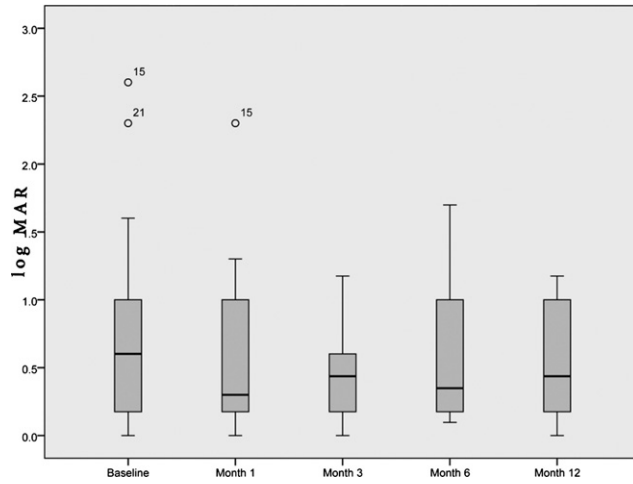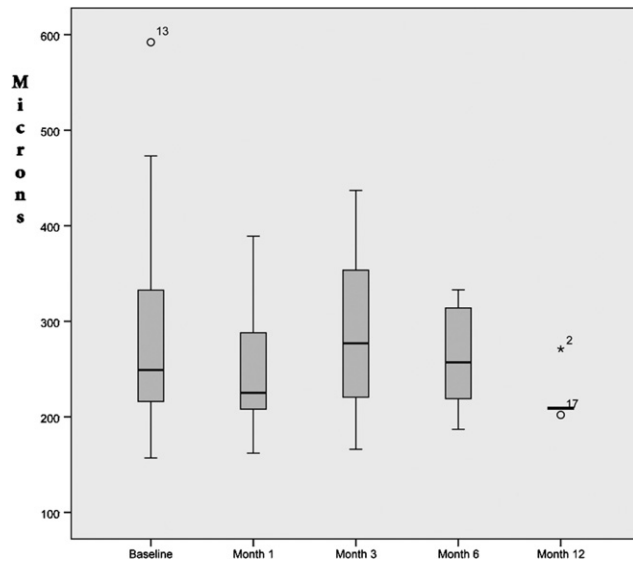
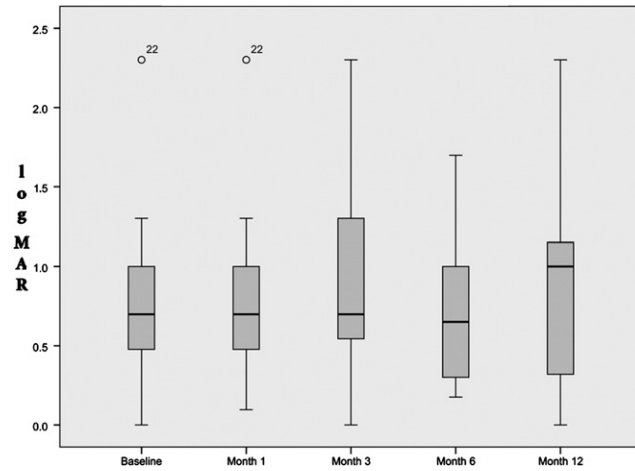


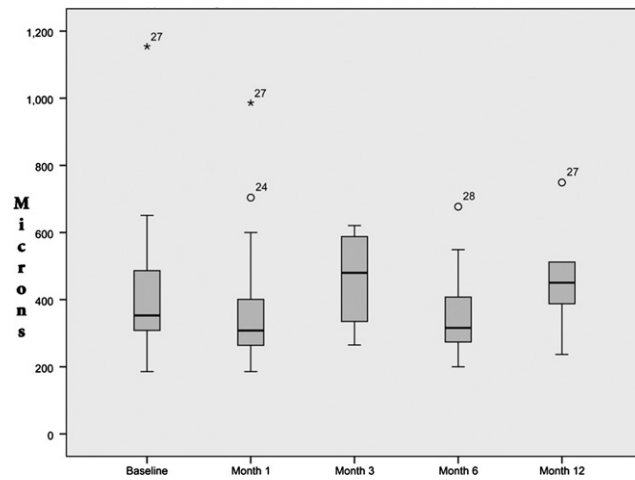
SUPPLEMENTAL FIGURE 1. Box plot illustrating the distribution of the visual acuities (VA) (logarithm of minimal angle of resolution [logMAR]) of eyes with inflammatory choroidal neovascularization (CNV) at baseline and at 1, 3, 6, and 12 months of follow-up.



SUPPLEMENTAL FIGURE 2. Box plot illustrating the distribution of the macular thicknesses (central subfield thicknesses [CST], as measured by optical coherence tomography [OCT]) of eyes with inflammatory CNV at baseline and at 1, 3, 6, and 12 months of follow-up.



SUPPLEMENTAL FIGURE 3. Box plot illustrating the distribution of the VAs (logMAR) of eyes with inflammatory cystoid macular edema (CME) at baseline and at 1, 3, 6, and 12 months of follow-up.



SUPPLEMENTAL FIGURE 4. Box plot illustrating the distribution of the macular thicknesses (CST, as measured by OCT) of eyes with inflammatory CME at baseline and at 1, 3, 6, and 12 months of follow-up.