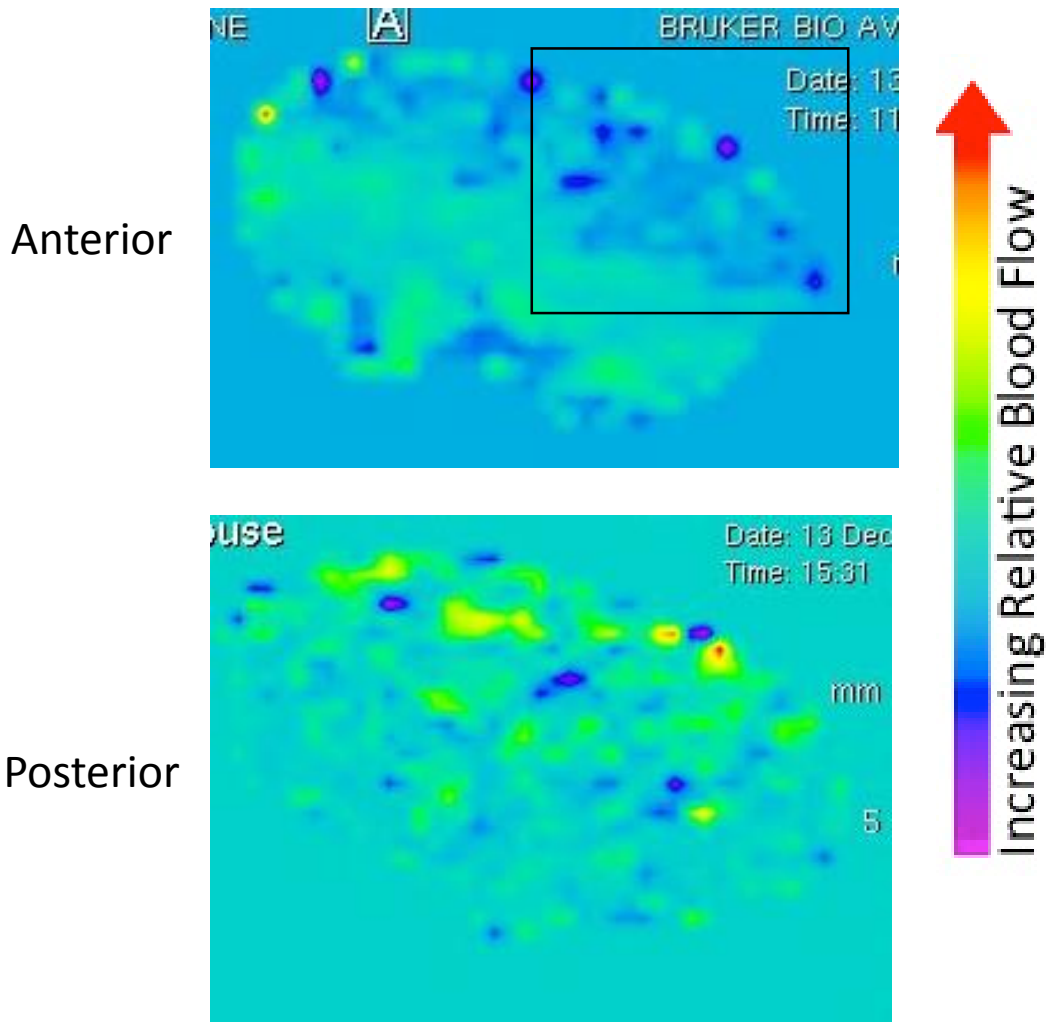


Additional file 3: MRI scan images of anterior and posterior region of a brain 1 week post-TAC surgery, showing hypoperfusion on the left hemisphere only at the anterior region of the brain.



Additional file 3: MRI scan images of anterior and posterior region of a brain 1 week post-TAC surgery. Doppler velocity of left to right ratio on carotid arteries is 1:9 on this mouse. The black rectangle in the upper images frames the hypoperfused area in the anterior region of the brain.