

Supplemental figures

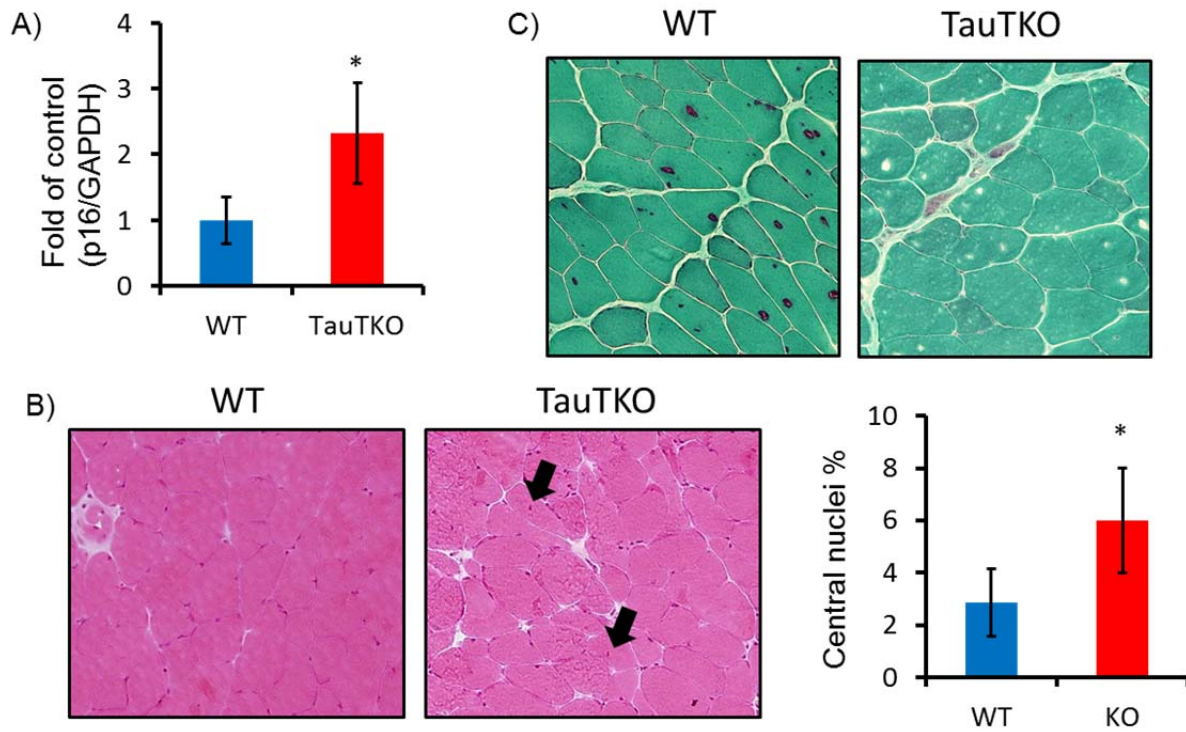


Fig. S1 A) Significant induction of p16INK4A in aged female TauTKO muscle. n=4 (WT), 3 (TauTKO) B) Significant increase in central nuclei-myotubes is detected in aged female TauTKO muscle. n=4 (WT), 5 (TauTKO). C) Gomori trichrome stain shows no red-ragged fibers in aged TauTKO muscle. Similar results were obtained from 3 independent experiments.