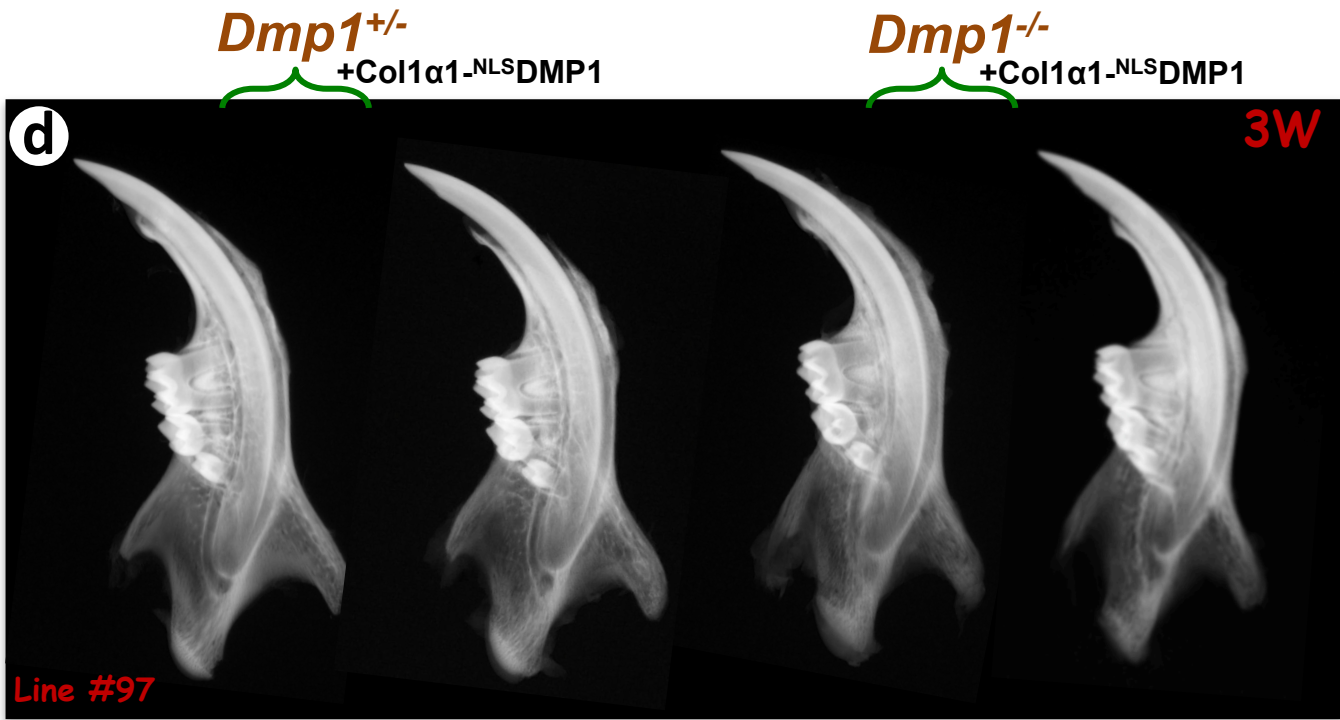
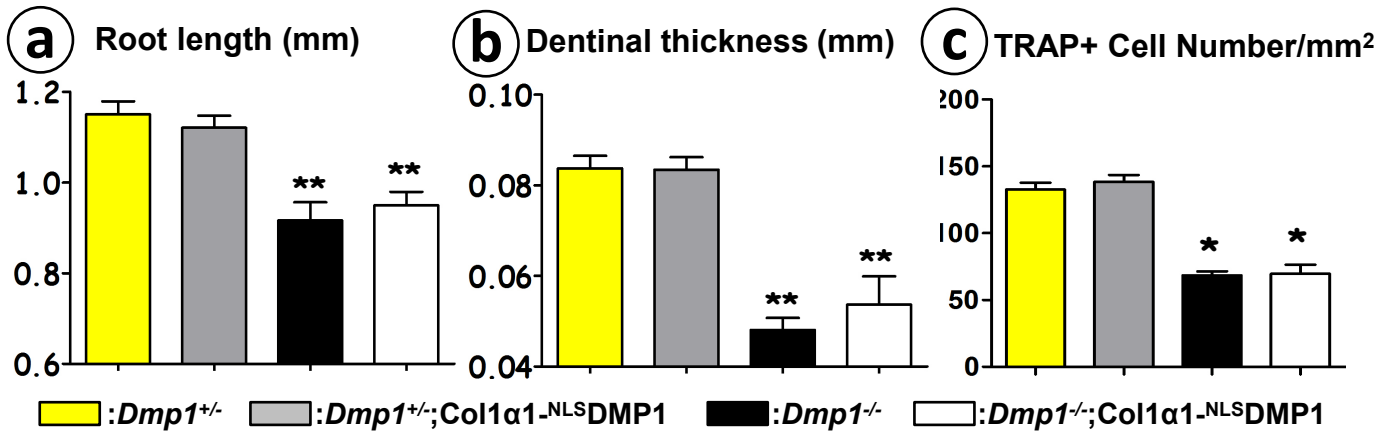


Supplementary Figure



Supplementary Figure (a-b) Shown are the length (mm) of the roots (a) and the thickness (mm) of the dentin layer (b) from 3-week-old mice. Data are mean ± SEM; n=6 in each group; *P<0.05; **P<0.01, compared to the control (HET). (c) Statistical analysis of the number of osteoclasts in 3-week-old mice. Data are mean ± SEM; n=4 in each group; *P<0.05, compared to the control. (d) Radiographs of the 3-week-old mandibles of another independent line (line #97). Typical dental and condylar defects can be found in the *Dmp1*^{-/-} and *Dmp1*^{-/-}; Col1α1-NLSDMP1 mice.