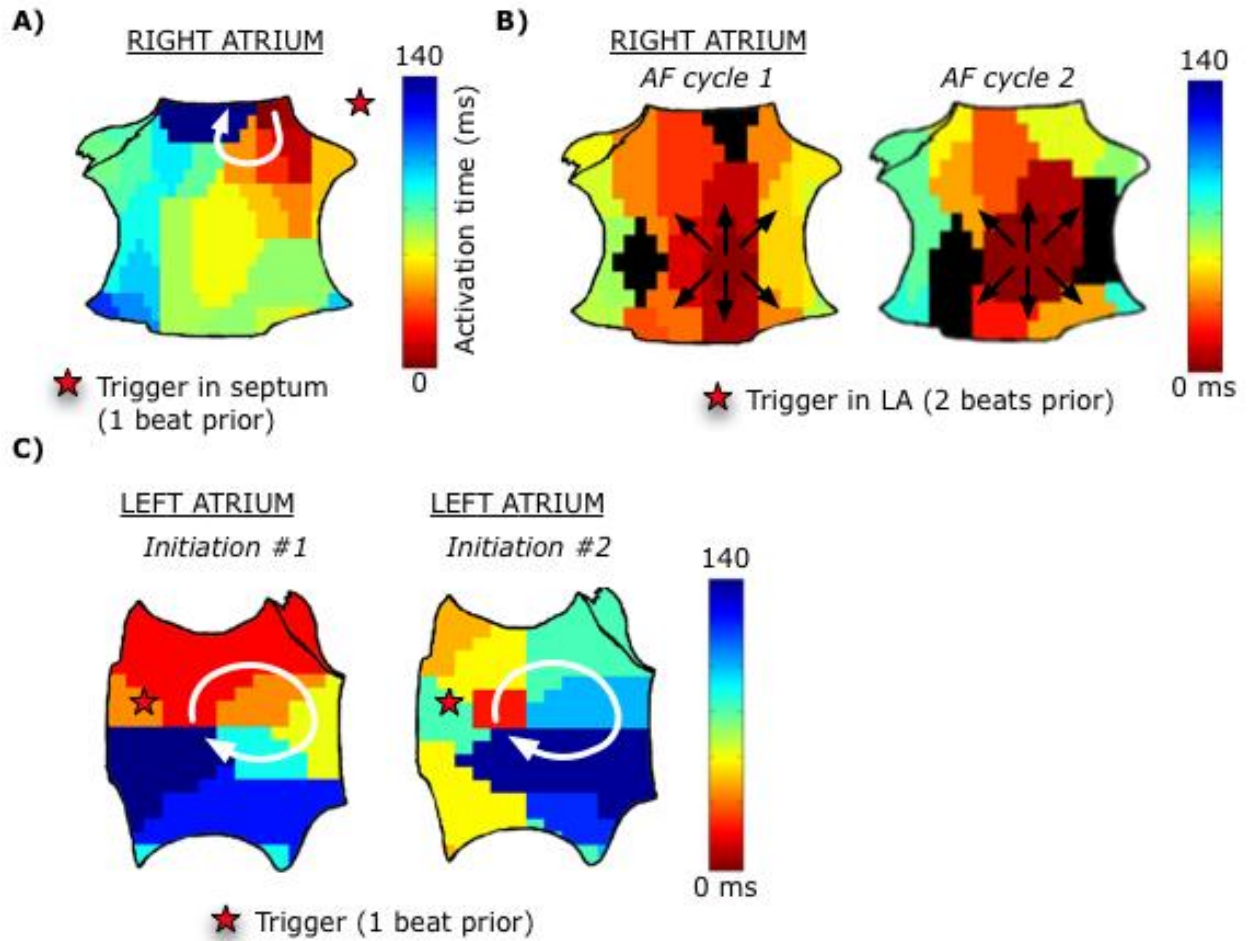


SUPPLEMENTAL MATERIAL

SUPPLEMENTAL FIGURES

Supplemental Figure 1



SUPPLEMENTAL FIGURE LEGENDS

Supplemental Figure 1:

Additional AF initiations. (a) Spontaneous AF initiation by a clockwise spiral wave in the high septal
10 right atrium in a 67-year-old man with persistent AF. (b) Spontaneous initiation of paroxysmal AF via a
repetitive focal driver in a 57-year-old man, in which the focal driver in the low posterior RA for the first
2 AF cycles continued into sustained AF. (c) Two pacing-induced initiations in a 61-year-old man with
paroxysmal AF. Each initiation demonstrates the same clockwise spiral wave in the mid posterior left
atrium that initiates AF. In this patient rapid burst pacing was performed in the right superior pulmonary
15 vein at cycle length 280 ms (214 bpm; initiation #1) and cycle length 500 ms (120 bpm; initiation #2).