

Epidemic Caprine Keratoconjunctivitis: Experimentally Induced Disease with a Pure Culture of *Mycoplasma conjunctivae*

S. L. TROTTER,¹ R. M. FRANKLIN,² E. J. BAAS,³ AND M. F. BARILE^{1*}

Bureau of Biologics, Division of Bacterial Products, Food and Drug Administration, Bethesda, Maryland 20014¹; The Wilmer Ophthalmological Institute, Johns Hopkins University School of Medicine, Baltimore, Maryland 21205²; and Division of Research Services, National Institutes of Health, Bethesda, Maryland 20014³

Received for publication 3 June 1977

The induction of caprine keratoconjunctivitis by the subconjunctival inoculation of a cloned culture of *Mycoplasma conjunctivae* is described. The clinical course of the experimental disease was similar to that noted in naturally occurring outbreaks of "pink-eye" among goats, and biopsies of inflamed conjunctivae showed similar histological response. *M. conjunctivae* was consistently recovered from the inflamed conjunctival tissues of inoculated animals that developed ocular disease, thus fulfilling Koch's postulates and establishing this organism as an etiological agent of caprine keratoconjunctivitis. Immunological studies suggested that cellular immune mechanisms may play a role in protecting animals from disease produced by this mycoplasma.

A variety of mycoplasmas have been isolated from goats with keratoconjunctivitis, including *Mycoplasma arginini*, *Mycoplasma conjunctivae*, and *Acholeplasma oculi* (1, 2, 4, 12). *M. conjunctivae* has been implicated as a cause of keratoconjunctivitis because it has been frequently isolated from the inflamed eyes of goats, sheep, and chamois during separate and distant epidemics occurring in Maryland (2, 4), Canada (11), Australia (14, 15), and Switzerland (10, 12, 13). However, definitive studies have not been done to establish the role of this agent in the etiology of this disease. This study describes the successful induction of severe keratoconjunctivitis in goats inoculated with a cloned culture of *M. conjunctivae*. The course of the experimentally induced disease was similar to the disease observed during two spontaneous outbreaks of caprine keratoconjunctivitis (2). The successful induction of disease has permitted us to meet Koch's postulates and to suggest that *M. conjunctivae* is one cause of epidemic caprine keratoconjunctivitis. A detailed study of the course of infection has provided a basis for establishing the role of *M. conjunctivae* in the cause of caprine keratoconjunctivitis.

MATERIALS AND METHODS

Goats. Nubian and Toggenberg male goats, ranging from 7 months to 3 years of age, were housed in large indoor stalls completely isolated from all other farm animals at the National Institutes of Health (NIH)

Animal Center, Poolesville, Md. Control animals were housed with the goat herd and handled independently from inoculated animals. The goats were fed a pelleted ration supplemented with hay.

Culture procedures. Specimens of the conjunctiva and nasopharynx of experimental goats were examined before inoculation and periodically throughout the study for the presence of mycoplasmas, bacteria, and fungi, using procedures described in the accompanying paper (2).

Challenge culture. Strain DBS 694, isolated from the inflamed eye of a goat with an acute case of typical keratoconjunctivitis, was purified by the triple-cloning procedure (3) and shown to be closely related or identical to the prototype strain HRC 581 (ATCC 25834) of *M. conjunctivae* isolated from the inflamed eye of a sheep with a typical case of keratoconjunctivitis (4). The third broth passage (p3) of strain DBS 694 was subcultured five times in primary Vervet monkey kidney (VMK) cell cultures (VMK, p5) before it was used as the challenge inoculum. Initially, it produced minimal cytopathic effects, but after five passages in VMK cell cultures, strain DBS 694 was able to produce severe cytopathic effects within 96 h. (The ability to produce severe cytopathic changes has been associated with virulence.) The inoculum was harvested by scraping a 96-h *M. conjunctivae*-infected VMK cell culture with a rubber spatula and centrifuging the suspension at $54,500 \times g$ for 60 min. The resulting pellet containing *M. conjunctivae*-infected VMK cell culture was resuspended in mycoplasma broth medium containing 2% PLO Serum Fraction (Difco Laboratories, Detroit, Mich.), frozen quickly in a bath of acetone and dry ice, and stored at -70°C until used. The challenge inoculum contained 2.8×10^8 colony-forming units of *M. conjunctivae* per ml (p3,

VMK, p5), as determined by the dilution colony count procedure. The noninfected VMK cell cultures, which served as control material, were prepared and maintained in the same manner and were examined and found to be free from mycoplasma and bacterial contamination.

Inoculation of animals. Before inoculation, the intact conjunctival tissues were anesthetized with a topical application of 0.5% proparacaine hydrochloride (Ophthaine, E. R. Squibb & Sons, New York, N.Y.), and the upper bulbar conjunctiva of the right eye was injected subconjunctivally with 0.3 to 0.4 ml of the *M. conjunctivae*-VMK suspension, using a tuberculin syringe and a 26-gauge needle. In addition, 0.3 to 0.4 ml of the mycoplasma suspension was dropped into the conjunctival cul-de-sac. The left eye was not inoculated. Two goats served as controls and received the noninoculated VMK cell culture material in the same manner.

Physical examination of animals. The goats were examined before inoculation and daily thereafter for changes in their general physical condition and for signs of disease. Physical examinations included recording their temperature, respiration rate, pulse, weight, physical appearance, and general attitude, and examining the goats for signs of respiratory illness and/or congestion, lameness, and/or other signs of arthritis and urethritis. Eyes were examined closely for signs of keratoconjunctivitis, including increased lacrimation, hyperemia of conjunctival tissues, and increased vascularization and opacity of the cornea. Indirect ophthalmoscopy was performed on selected animals throughout the study. On each day of examination, control goats were examined before inoculated animals.

Histological examinations. Biopsies were taken from the bulbar conjunctivae of control goat 596C and mycoplasma-infected goats 646 and 657 and were prepared for histological examination as described previously (2).

Examination of blood. Blood drawn before inoculation and weekly thereafter was used for complete blood count determinations and for lymphocyte transformation studies. Serum was collected for protein determinations, electrophoretic mobility patterns, and serological study.

Serum antibody studies. Sera were tested for the presence of specific neutralizing antibody to *M. conjunctivae* strain DBS 694, originally isolated from a goat with keratoconjunctivitis (4), using the metabolic inhibition test (17).

Lymphocyte transformation. A 20-ml sample of venous blood was processed for lymphocyte culture studies, using aqueous heparin as the anticoagulant. The erythrocytes were removed with ammonium chloride, and the lymphocytes were collected and used at a concentration of 10^6 cells/ml resuspended in RPMI 1640 cell culture medium supplemented with 10% fetal calf serum, 0.3% glutamine, and neomycin. A 0.1-ml volume of antigen was added to 1-ml samples of the lymphocyte suspension, in triplicate, and these were incubated for 5 days in a 5% CO₂-in-air atmosphere. Several antigens were tested, including heat-killed mycoplasma-infected VMK cell culture (the same preparation that was used as the inoculum) suspensions

diluted 1:10 and 1:100; heat-killed, non-infected VMK control (inoculum) suspensions diluted 1:10; and phytohemagglutinin (Difco) diluted 1:160. Sixteen hours before harvest, the lymphocytes were pulsed with 1 μ Ci of sterile, aqueous, tritiated thymidine (Amersham/Searle Corp., Arlington Heights, Ill.), and the results were recorded as a comparative ratio of counts obtained with antigen-stimulated lymphocytes over counts obtained with unstimulated cell suspensions. A value of 3 or greater was considered significant (8).

Lacrimal antibody studies. Tears were obtained weekly by gently collecting the tear pool at the medial canthus with a 100- μ l capillary tube. An approximate 50- μ l volume of lacrimal secretion was collected, diluted 1:5 with mycoplasma broth medium containing penicillin (100 U/ml) and thallium acetate (0.025%), and tested for the presence of specific neutralizing antibody to *M. conjunctivae* by use of the metabolic inhibition test.

RESULTS

Clinical findings. Six goats (five adults and one kid) were inoculated subconjunctivally with suspensions of *M. conjunctivae*-infected VMK cell cultures, and two goats (one adult and one kid) received the VMK control material. Of six goats inoculated with *M. conjunctivae*, three goats (646, 596, 482) developed frank, severe keratoconjunctivitis, and two goats (505, 513) developed a mild conjunctivitis. Three of the goats (kid 657, inoculated with mycoplasma; and goats 596C and 656, given control VMK suspension) showed no signs of illness.

The clinical features of experimentally induced keratoconjunctivitis are summarized in Table 1 and illustrated in Fig. 1A. The disease was characterized by increased lacrimation and injection of vessels of the bulbar and palpebral conjunctiva. The disease increased in severity for 12 to 14 days and then lessened for the next 6 days. During the height of the disease, a fine brush border of vessels extended from the conjunctiva into the cornea. Associated with the vascularization was the development of corneal opacity, localized initially to the upper periphery of the cornea. One animal showed signs of severe photophobia. The localized corneal vascularization and opacity progressed to a circumlimbal vascularization and opacity, involving more than two-thirds of the entire cornea (Fig. 2). Bilateral disease was seen in two of the three goats, appearing approximately 6 days after or coincident with the onset of right-eye disease. The left eyes of both animals developed conjunctival and then corneal lesions, which were essentially the same as described for the disease in right eyes. All eyes returned to normal by 6 weeks after inoculation without the aid of drug therapy.

Two of the *M. conjunctivae*-infected goats produced a mild conjunctivitis, characterized by

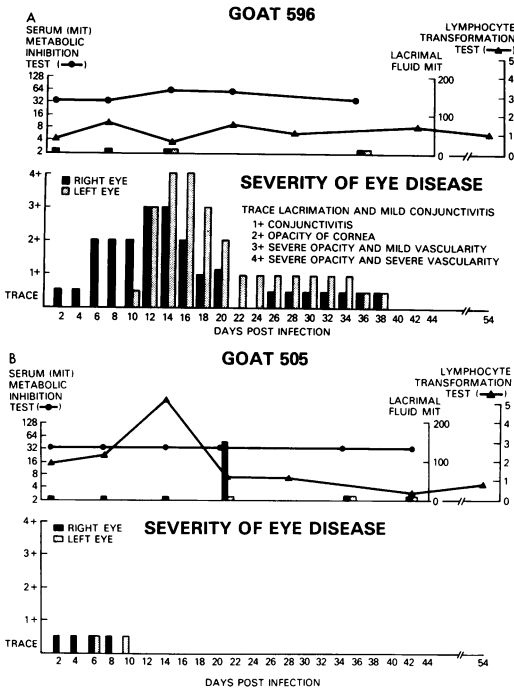


FIG. 1. Representative goats illustrating the progression of disease in five goats infected in the right eye with *M. conjunctivae* strain DBS 694. Three animals developed an intense keratoconjunctivitis as exemplified by goat 596 (A), and the remaining two goats developed a mild conjunctivitis as exemplified by goat 505 (B).

increased lacrimation, hyperemia, and enlargement of the conjunctival vessels (Fig. 1B). The disease did not progress, and the two goats appeared normal at 12 and 28 days later, respectively. The infected goat, 657, which did not develop eye disease, died during week 8 of the study with a urinary tract infection. The immediate cause of death was not determined. Tissues examined from two of the goats, 482 and 657, showed development of glomerulonephritis.

The experimentally infected animals showed a reduction in physical activity, and their coats had a ruffled appearance during the most severe phase of the eye disease. No changes were observed in temperature, pulse, weight, respiratory function, or in their serum protein and electrophoretic patterns. Only minimal fluctuations were observed in blood cell counts.

Histological findings. Biopsies of the non-infected, control goat conjunctiva were normal, with the usual complement of subepithelial mononuclear cells (Fig. 3). The biopsies of the infected right and left eyes of goat 646 taken 7 days after onset of disease showed a heavy, mixed mononuclear-cell infiltration with some polymorphonuclear cells (Fig. 4). Bacteria were

not observed in either the normal control or infected goat tissues, using the Brown and Brenn staining procedure (5).

Microbiological findings. Cultures of the conjunctival tissues obtained before inoculation were free of mycoplasmas, but did show the presence of occasional saprophytic fungi and commensal bacteria, including strains of *Staphylococcus*, *Streptococcus*, and *Pseudomonas*. Subsequently, eyes were cultured again at 1 and 3 weeks after the regression of illness. At both time periods, cultures of the control animals and cultures of inoculated goat 657 were negative for mycoplasma. Cultures from the eyes of goats 505 and 513, which had developed only conjunctivitis, were also negative for mycoplasma. However, mycoplasmas were isolated from the inflamed ocular tissues of all three animals with keratoconjunctivitis; *M. conjunctivae* was found in both eyes of goats 646 and 596 and in the left eye of goat 482. A continued surveillance of goat 646 found that this animal carried *M. conjunctivae* in the left eye for 3 months after clinical cessation of disease. There was no recurrence of disease.

Serum and lacrimal antibody response. No significant differences were noted in serum antibody response to *M. conjunctivae* either in the goats inoculated with control VMK material or those inoculated with *M. conjunctivae* (Table 1; Fig. 1A and B). The mean metabolic inhibition titer for all animals was 1:32. Fourfold rises in serum antibody response were seen in only one of five infected goats and one of two control goats; both of the responding animals showed increases in titer from 1:16 to 1:64. However, three goats (505, 513, and 482) did produce a transient lacrimal antibody rise to *M. conjunctivae* during weeks 2 and 3 postinoculation (Table 1; Fig. 1B). These lacrimal metabolic inhibition titers ranged from 1:10 to 1:160 but did not correlate with the clinical severity or course of disease.

Lymphocyte transformation. The lymphocytes from two goats (505 and 513) that developed only conjunctivitis produced a significant fivefold titer increase in response to stimulation by *M. conjunctivae*, whereas the lymphocytes of goat 596 that developed keratoconjunctivitis showed no significant titer response to the mycoplasma antigen (Table 1; Fig. 1A and B). The lymphocytes of goat 513 showed a threefold response for *M. conjunctivae* before challenge, suggesting a previous experience with the organism, which may have influenced the resulting mild course of the induced infection.

DISCUSSION

M. conjunctivae has been isolated by a number of investigators from the inflamed eyes of

goats, sheep, and chamois with keratoconjunctivitis during epidemics in geographically distant countries (2, 4, 10-15). In 1969, Klingler et al. (10) isolated a mycoplasma from the eye of a chamois with keratoconjunctivitis. The organism was grown in broth culture and then used experimentally to induce keratoconjunctivitis.

Five years later, the organism was identified as *M. conjunctivae* (12). In 1973, Surman (15) successfully induced keratoconjunctivitis, using the conjunctival scrapings of an infected sheep with naturally occurring disease. These scrapings were shown to contain a mixed culture of mycoplasmas. Some scrapings grew out *M. arginini*

TABLE 1. Characteristics and fate of goats used in the study

Goats	Characteristic ^a								
	Challenge inoculum, <i>M. conjunctivae</i> (CFU)	Age (mo)	Eye involved	Severity of disease	Length of disease (days)	Mycoplasma colonization of eye	Significant serological response	Significant lacrimal antibody response	Significant lymphocyte stimulation
<i>M. conjunctivae</i> infected									
482 ^b	1 × 10 ⁸	48	R	KC	14	+	0	+	ND
646	1 × 10 ⁸	24	R, L	KC	17	+	0	ND	ND
596	1 × 10 ⁸	24	R, L	KC	13	+	0	0	0
505	6 × 10 ⁷	24	R	C	12	0	0	+	+
513	6 × 10 ⁷	24	R	C	28	0	+	+	+
657	1 × 10 ⁸	7	0	0	0	0	0	ND	ND
Control									
596C	0	24	0	0	0	0	+	0	0
656	0	7	0	0	0	0	0	ND	ND

^a Abbreviations: CFU, Colony-forming units; R, right eye; L, left eye; KC, kerato-conjunctivitis; C, conjunctivitis; ND, not done. 0, None; +, positive.

^b Goat identification number.

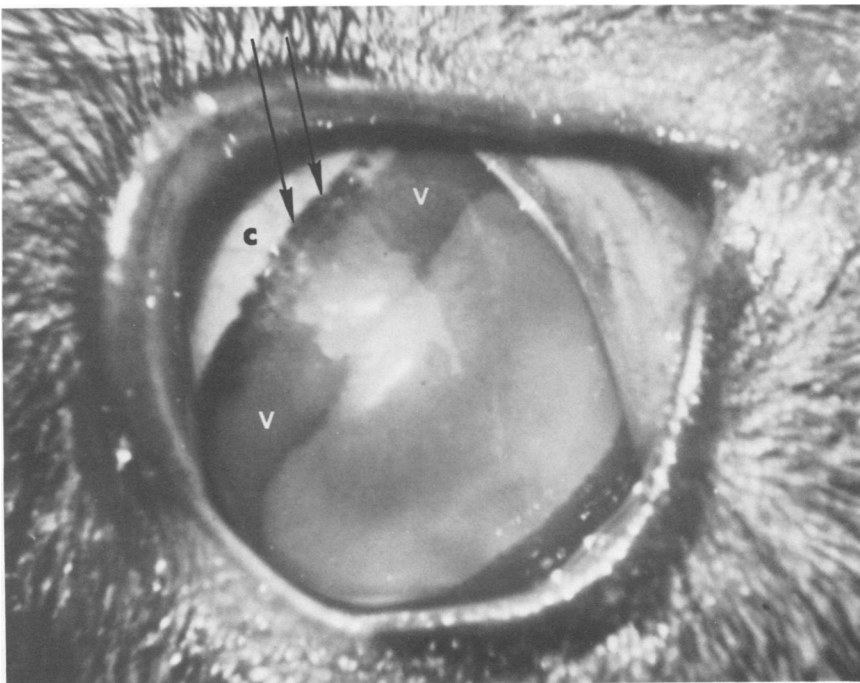


FIG. 2. *M. conjunctivae*-induced keratoconjunctivitis. The intense reaction has progressed to a cloudy cornea through which internal eye structures are barely visible, and to invasion of the cornea by blood vessels (v). Conjunctiva (c). Arrows designate pigment band at corneoscleral junction.

alone, some grew out *M. conjunctivae* alone, and others grew out both *Mycoplasma* species (4).

The present study describes the successful induction of eye disease in five of six goats inoculated with a pure culture of *M. conjunctivae*. The clinical courses of the experimentally induced and naturally occurring disease (2) were similar and were characterized by increased lacrimation, hyperemia of conjunctival tissues, and vascularization and cloudiness of the cornea. Moreover, the rate of recovery of *M. conjunctivae* from the inflamed conjunctival tissues of the experimentally infected goats was similar to mycoplasma colonization of infected tissues observed in the natural disease. In both cases, *M. conjunctivae* colonized and was frequently isolated from the inflamed eyes of animals with keratoconjunctivitis, but the organism could not be isolated from animals with the milder form of the disease. No other microorganisms were consistently recovered from the inflamed conjunctival tissues.

In one of the experimental goats, 646, the organism was recovered from conjunctival tissues 3 months after the cessation of clinical disease and apparent recovery. The colonization and recovery of mycoplasma after cessation of

clinical disease has also been noted in a number of other naturally occurring mycoplasma diseases of man and animals. For example, *M. pneumoniae* can persist in the lungs of infected hamsters (and in the lungs of patients with naturally occurring disease) for many weeks after clinical recovery (6, 7). The factors that permit mycoplasmas to colonize tissues for extended periods of time are not well understood. However, persistence may help to explain the occurrence of sporadic endemic disease and also of relapse in some animals, phenomena observed during our study of the disease (2).

Low levels of specific neutralizing antibody titers to *M. conjunctivae* were present in all of the experimental animals before inoculation, and it was not possible to find seronegative goats in the herd for experimental study. Two epidemics of caprine keratoconjunctivitis had occurred in the NIH herd earlier (2), but the animals selected for this study were not present in the herd at that time. The presence of specific antibody in the herd suggests prior exposure to *M. conjunctivae* and indicates that the presence of low titers of specific serum antibody does not necessarily protect these animals against *M. conjunctivae* infection.

The difference in severity of the experimental

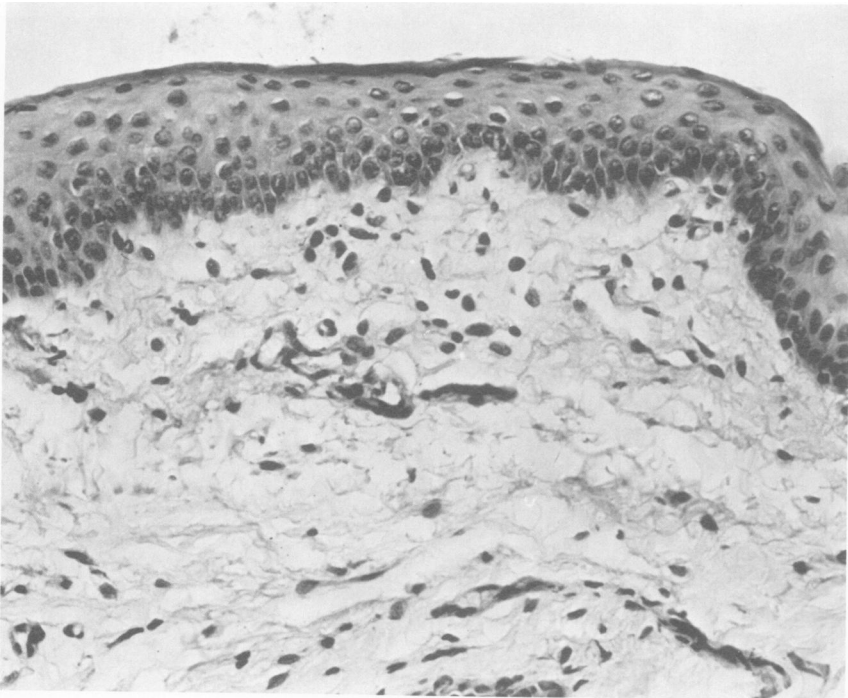


FIG. 3. Conjunctival biopsy obtained from an uninfected, clinically normal control animal shows scattered subepithelial mononuclear cells. (Hematoxylin and eosin, $\times 270$.)

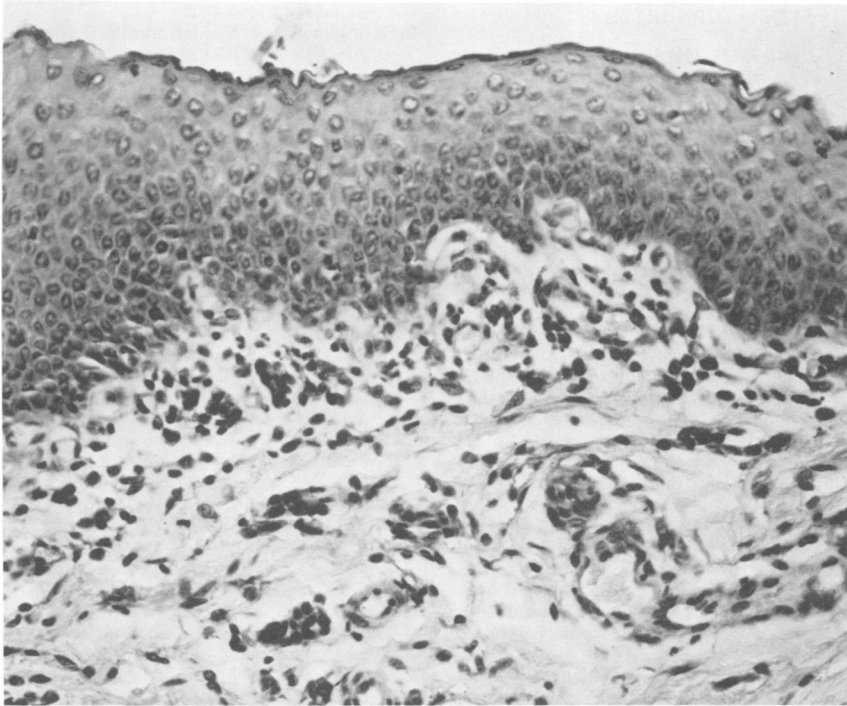


FIG. 4. Conjunctival biopsy from goat 646 7 days after onset of keratoconjunctivitis shows a heavy, subepithelial, mixed mononuclear-cell infiltrate with an occasional polymorphonuclear leukocyte. (Hematoxylin and eosin, $\times 240$.)

disease may reflect the size of the initial infective dose or some prior degree of sensitization. The three goats that developed keratoconjunctivitis received 10^8 colony-forming units, whereas the two animals with mild conjunctivitis received 6×10^7 colony-forming units (Table 1). The significance of this small difference in the inoculum is unknown and requires complete dose-response curves for evaluation.

The failure of experimentally infected goats to produce a strong serum antibody response to *M. conjunctivae* was similar to the serological findings in naturally occurring animal epidemics (2). This lack of serum antibody response during acute eye disease suggests that the keratoconjunctivitis induced was a localized infection with little, if any, systemic involvement. Indeed, the respiratory disease, associated with increased serum antibody noted during the natural epidemics (2), was not seen in these experimentally infected goats. The increase in serum antibody titer observed in control goat 596C cannot be fully explained. However, since the control animals were maintained with the goat herd, it is possible that they may have been exposed to infected animals. Insufficient data were obtained to define a role for lacrimal antibody with this eye disease.

Although the magnitude of the cell-mediated response to *M. conjunctivae* was low (fivefold or less), significant stimulation did occur in the two animals with mild disease. The findings in these animals may be analogous to the serum antibody response seen only in animals that developed respiratory signs (2). They also suggest that the cell-mediated response may be required for immunological protection to eye disease. Thus, the two goats with responsive lymphocytes may have had a prior systemic infection, although we are unaware that this occurred. The animals with more severe disease may then represent a localized encounter with the organism, activating cellular mechanisms reflected in the subconjunctival mononuclear-cell infiltrate, but not yielding a measurable systemic sensitization.

This mechanism of surface localization of mycoplasma with resultant subjacent tissue damage is consistent with findings in studies of mycoplasma-infected human and animal respiratory epithelium (6, 7). Furthermore, cell-mediated immune mechanisms have been implicated in protection of epithelial surfaces from both mycoplasmas (9) and viruses (18), in a manner similar to that suggested by the present study.

LITERATURE CITED

1. Al-Aubaidi, J. M., A. H. Dardiri, C. C. Muscoplatt, and E. H. McCauley. 1973. Identification and characterization of *Acholeplasma oculusi spec. nov.* from the eyes of goats with keratoconjunctivitis. *Cornell Vet.* **63**:117-129.
2. Baas, E. J., S. L. Trotter, R. M. Franklin, and M. F. Barile. 1977. Epidemic caprine keratoconjunctivitis: recovery of *Mycoplasma conjunctivae* and its possible role in pathogenesis. *Infect. Immun.* **18**:806-815.
3. Barile, M. F., and R. A. DelGiudice. 1972. Isolation of mycoplasmas and their rapid identification by plate epi-immunofluorescence, p. 165-181. *In Pathogenic mycoplasmas*, Ciba Foundation symposium. Elsevier, Amsterdam.
4. Barile, M. F., R. A. DelGiudice, and J. G. Tully. 1972. Isolation and characterization of *Mycoplasma conjunctivae* sp. n. from sheep and goats with keratoconjunctivitis. *Infect. Immun.* **5**:70-76.
5. Brown, J. H., and L. Brenn. 1931. A method for the differential staining of gram-positive and gram-negative bacteria in tissue sections. *Bull. Johns Hopkins Hosp.* **48**:69-73.
6. Dajani, A. S., W. A. Clyde, Jr., and F. W. Denny. 1965. Experimental infection with *Mycoplasma pneumoniae* (Eaton's agent). *J. Exp. Med.* **121**:1071-1084.
7. Denny, F. W., W. A. Clyde, Jr., and W. P. Glezen. 1971. *Mycoplasma pneumoniae* disease: clinical spectrum, pathophysiology, epidemiology, and control. *J. Infect. Dis.* **123**:74-92.
8. Fernald, G. W. 1972. In vitro response of human lymphocytes to *Mycoplasma pneumoniae*. *Infect. Immun.* **5**:552-558.
9. Fernald, G. W., W. A. Clyde, Jr., and J. Bienenstock. 1972. Immunoglobulin-containing cells in lungs of hamsters infected with *Mycoplasma pneumoniae*. *J. Immunol.* **108**:1400-1408.
10. Klingler, K., J. Nicolet, and E. Schipper. 1969. Neue Befunde über Gemsblindheit. *Schweiz. Arch. Tierheilkd.* **111**:587-602.
11. Langford, E. V. 1971. *Mycoplasma* and associated bacteria isolated from ovine pink-eye. *Can. J. Comp. Med.* **35**:18-21.
12. Nicolet, J., and E. A. Freundt. 1975. Isolation of *Mycoplasma conjunctivae* from chamois and sheep affected with kerato-conjunctivitis. *Zentralbl. Veterinärmed. Reihe B* **22**:302-307.
13. Nicolet, J., M. Wanner, N. Sturzenegger, J. Messerli, and P. A. de Meuron. 1974. Die infektiöse Keratokonjunctivitis des Schafes. Mögliche ätiologische Rolle von Mykoplasmen. *Schweiz. Arch. Tierheilkd.* **116**:435-446.
14. Surman, P. G. 1968. Cytology of "pink-eye" of sheep, including a reference to trachoma of man, by employing acridine orange and iodine stains, and isolation of mycoplasma agents from infected sheep eyes. *Aust. J. Biol. Sci.* **21**:447-467.
15. Surman, P. G. 1973. *Mycoplasma* aetiology of keratoconjunctivitis ("pink-eye") in domestic ruminants. *Aust. J. Exp. Biol. Med. Sci.* **51**:589-607.
16. Taylor-Robinson, D., F. W. Denny, A. C. Allison, G. W. Thompson, and G. Taylor. 1972. Cell-mediated immunity and the response to mycoplasma infections, p. 349-362. *In Pathogenic mycoplasmas*, Ciba Foundation symposium. Elsevier, Amsterdam.
17. Taylor-Robinson, D., R. H. Purcell, D. C. Wong, and R. M. Chanock. 1966. A colour test for the measurement of antibody to certain mycoplasma species based upon the inhibition of acid production. *J. Hyg.* **65**:91-104.
18. Waldman, R. H., and C. S. Henney. 1971. Cell-mediated immunity and antibody responses in the respiratory tract after local and systemic immunization. *J. Exp. Med.* **134**:482-494.