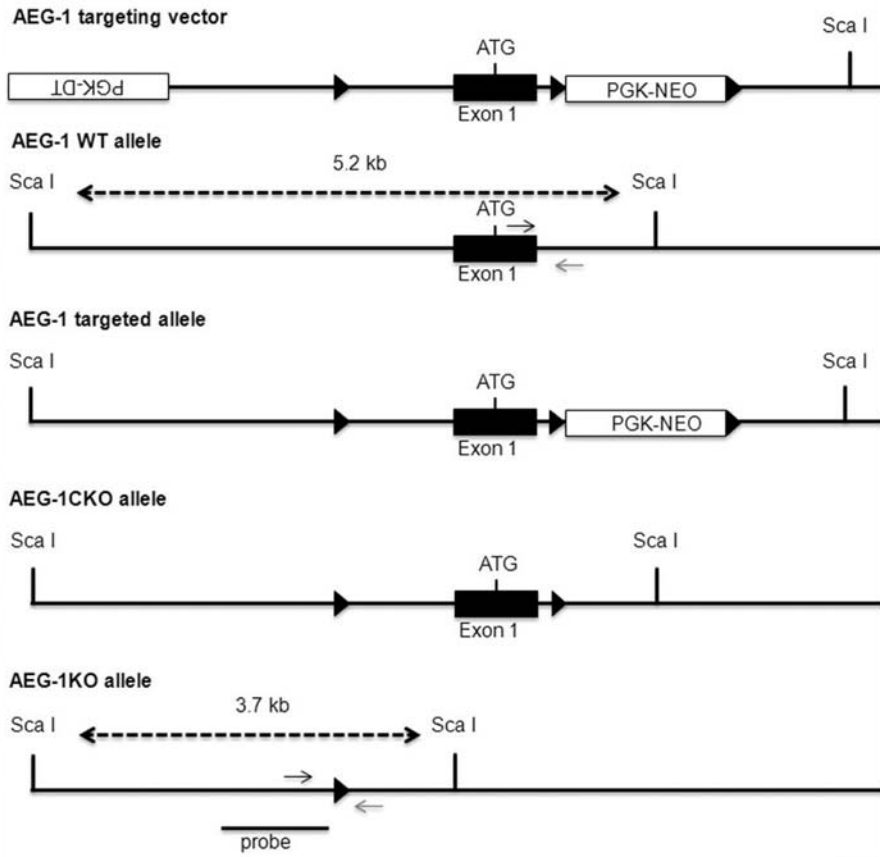
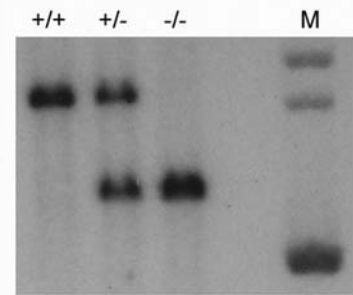


Robertson et al. Fig. S1

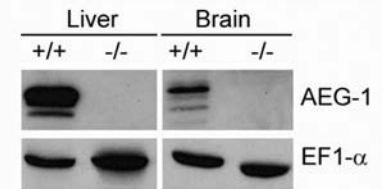
A.



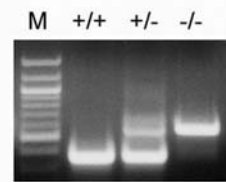
B.



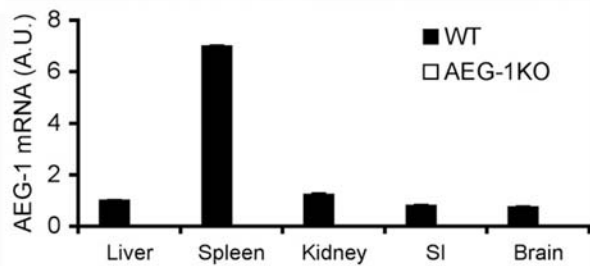
E.



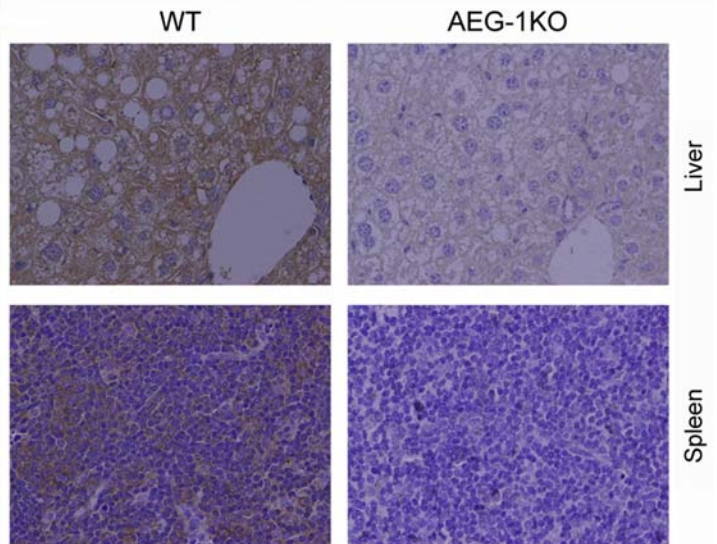
C.



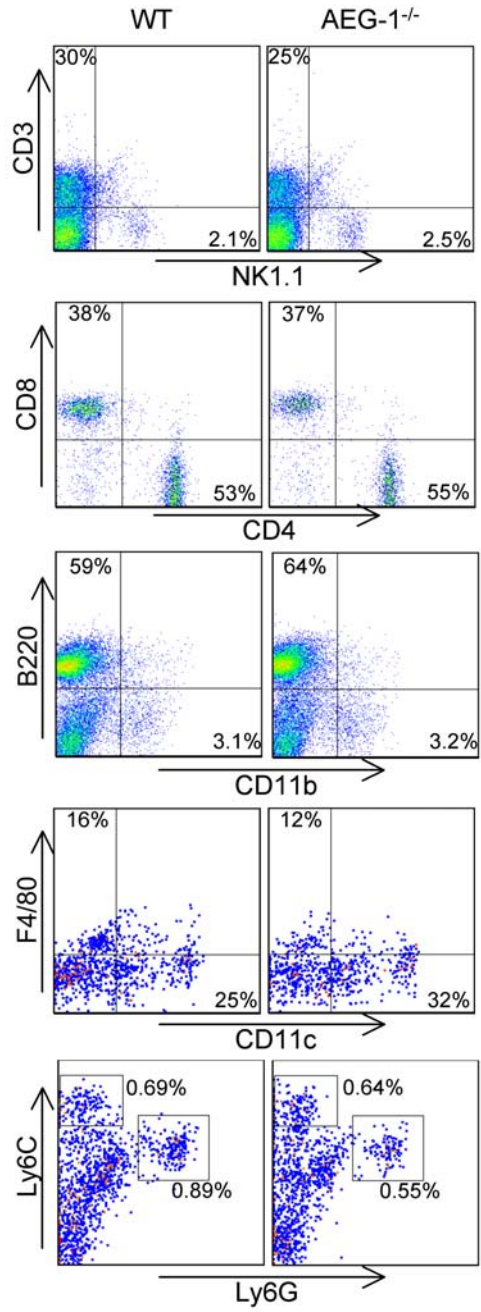
D.



F.

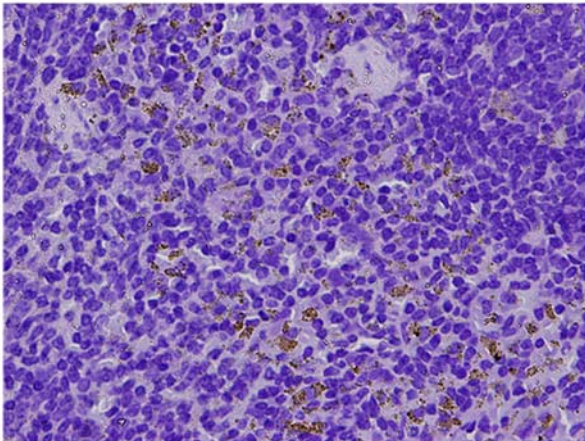


Robertson et al. Fig. S2

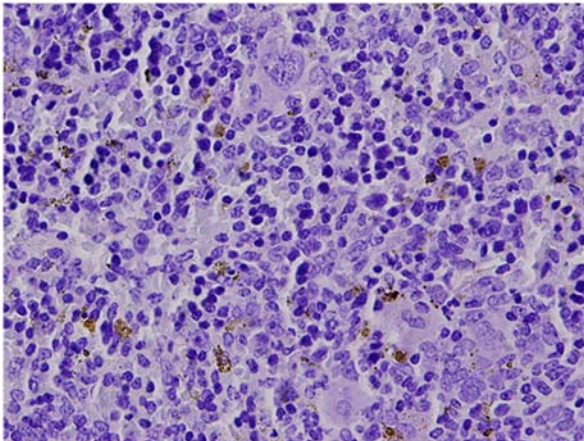


Robertson et al. Fig. S3

WT

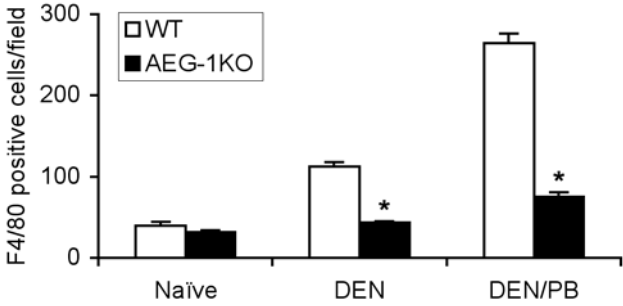


AEG-1KO

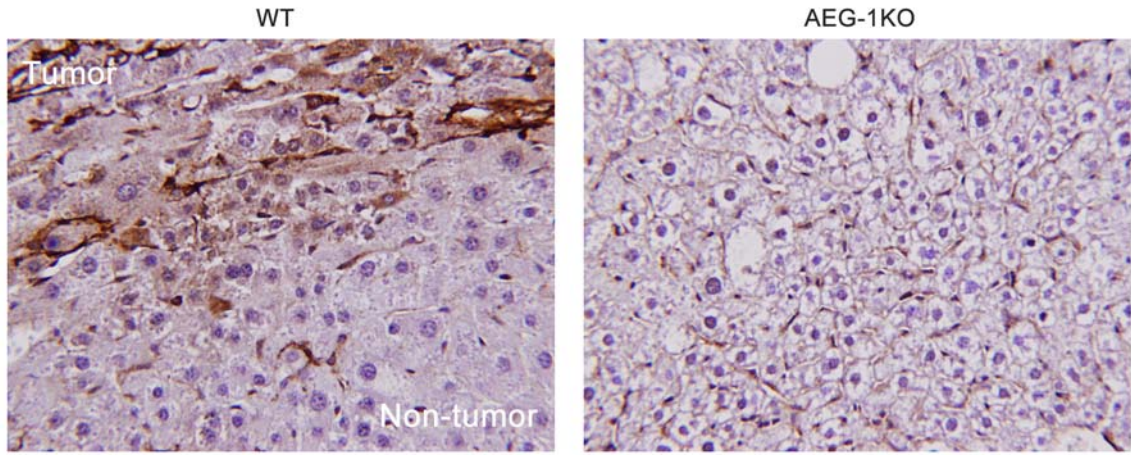


F4/80 staining in aged spleen (16 m old)

Robertson et al. Fig. S4



Robertson et al. Fig. S5



α -SMA staining in WT liver showing tumor and non-tumor region and AEG-1KO liver