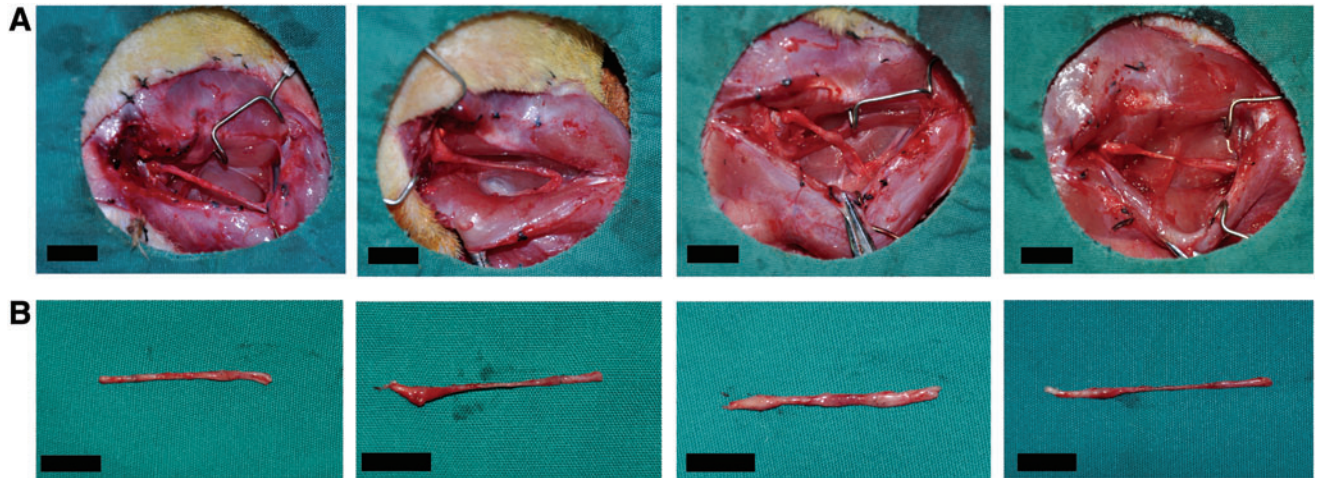


Supplementary Data



SUPPLEMENTARY FIG. S1. The sciatic nerve graft site at 12 weeks after implantation. (A) A macroscopic view captured *in situ* and (B) the nerve guide after explantation. Scale bar= 1 cm.