

## **SUPPLEMENTARY MATERIAL**

Figures S1 and S2

Tables S1 to S11 (in a separate Excel document)

### **FIGURE LEGENDS**

#### **Figure S1: Immunohistochemistry for the neuroendocrine marker CPE in eight FL-HCC cases.**

Representative images from multiple fields. Sections were counterstained with Hematoxylin (light blue) and the signal for CPE immunostaining is brown. Scale bars, 400  $\mu$ m.

#### **Figure S2: Immunohistochemistry for CREB and phospho-CREB in eight FL-HCC cases.**

Representative images from multiple fields. Sections were counterstained with Hematoxylin (light blue) and the signal for CREB (left) or p-CREB (center and magnified areas on the right) immunostaining is brown. Scale bars, 400  $\mu$ m.

Figure S1

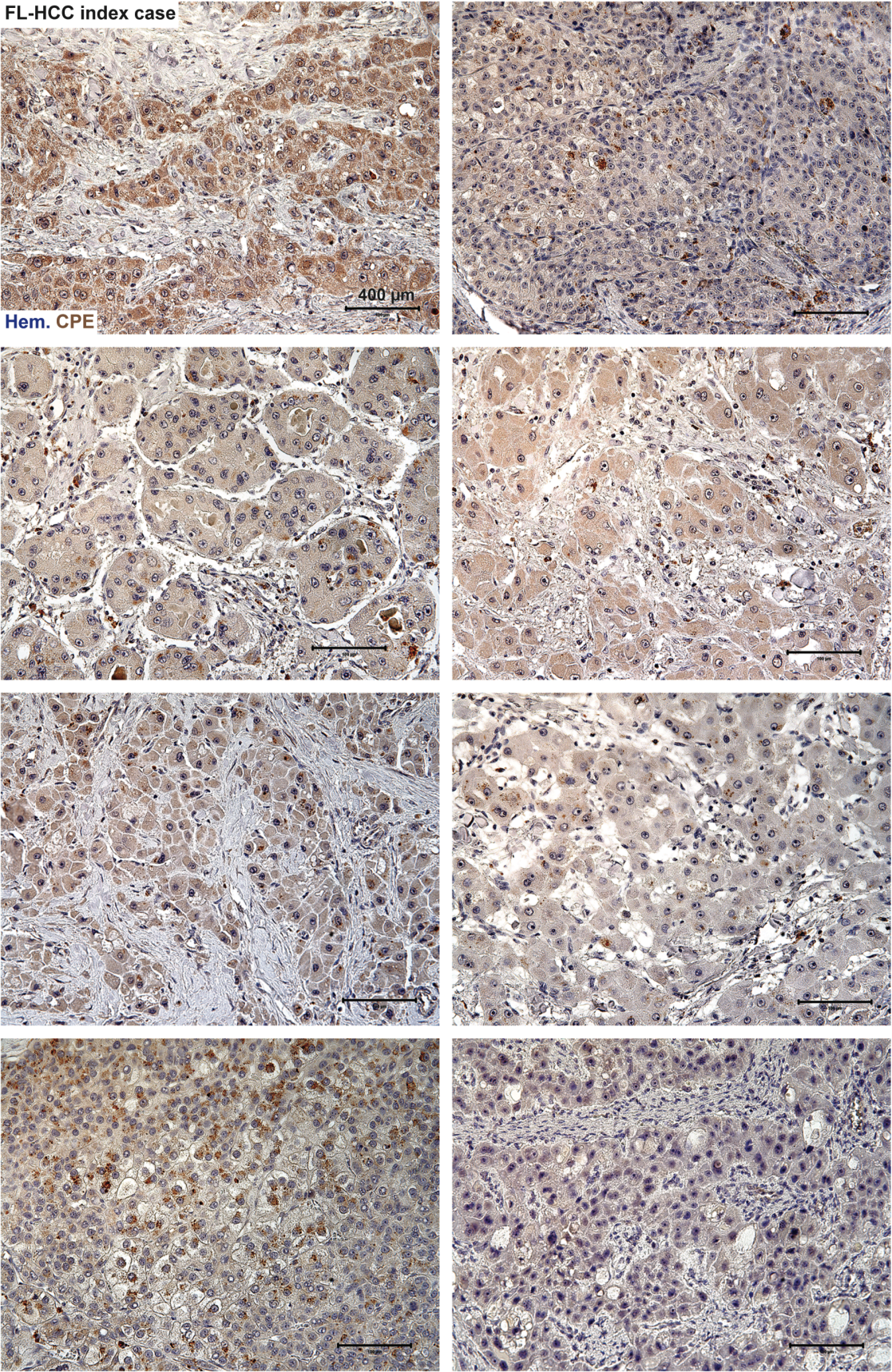


Figure S2

