

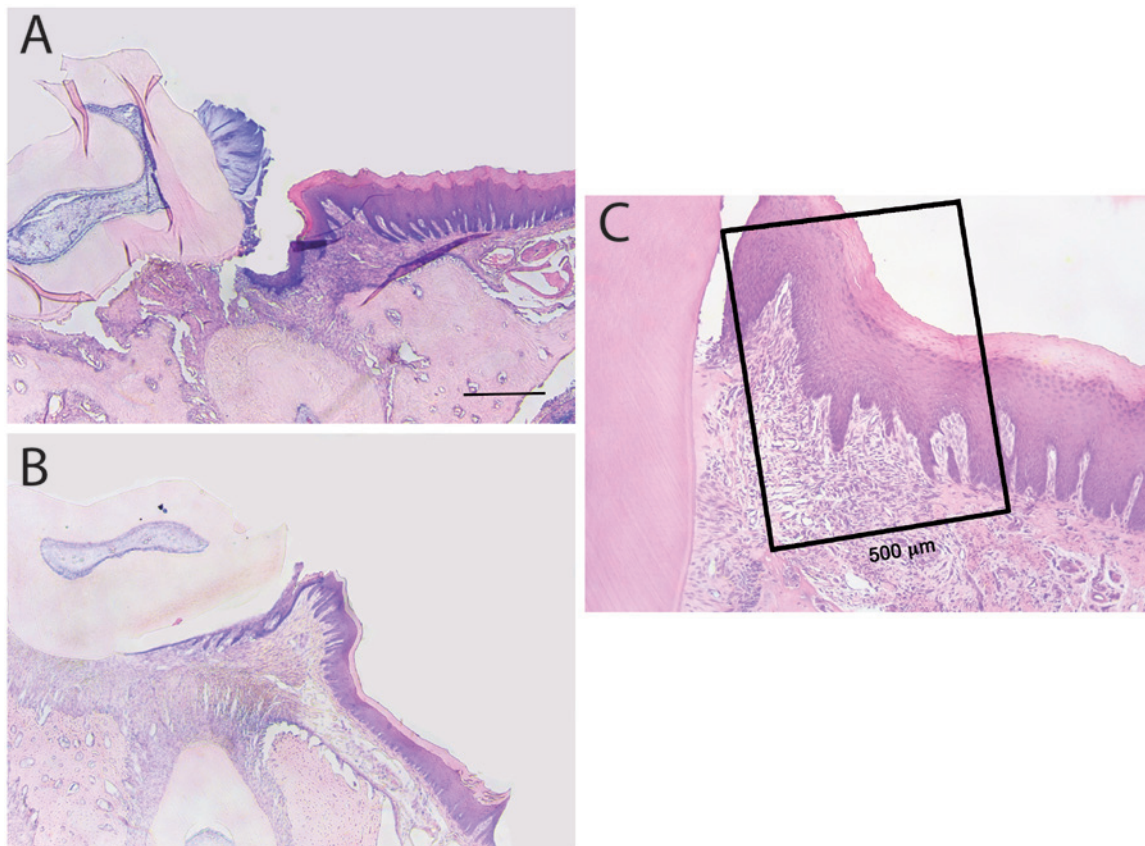
M. Cáceres^{1*}, A. Oyarzun², and P.C. Smith³

¹Molecular and Cell Biology Program, Facultad de Medicina, Universidad de Chile, Santiago, Chile; ²Faculty of Dentistry, Universidad Finis Terrae, Santiago, Chile; and ³School of Dentistry, Facultad de Medicina, Pontificia Universidad Católica de Chile, Santiago, Chile; *corresponding author, monicacaceres@med.uchile.cl

J Dent Res DOI: 10.1177/0022034514533126

Defective Wound-healing in Aging Gingival Tissue

APPENDIX



Appendix Figure. Wound-healing features of gingival tissues. **(A)** Histological section of wounded tissues 2 days after injury. Giemsa staining. Bar equals 100 μm. **(B)** Histological section of wounded tissues 14 days after injury. Giemsa staining. **(C)** Histological section of wounded tissues 7 days after injury. Giemsa staining. Square indicates the area defined to quantify the percentage of epithelial and connective tissue growth after injury.