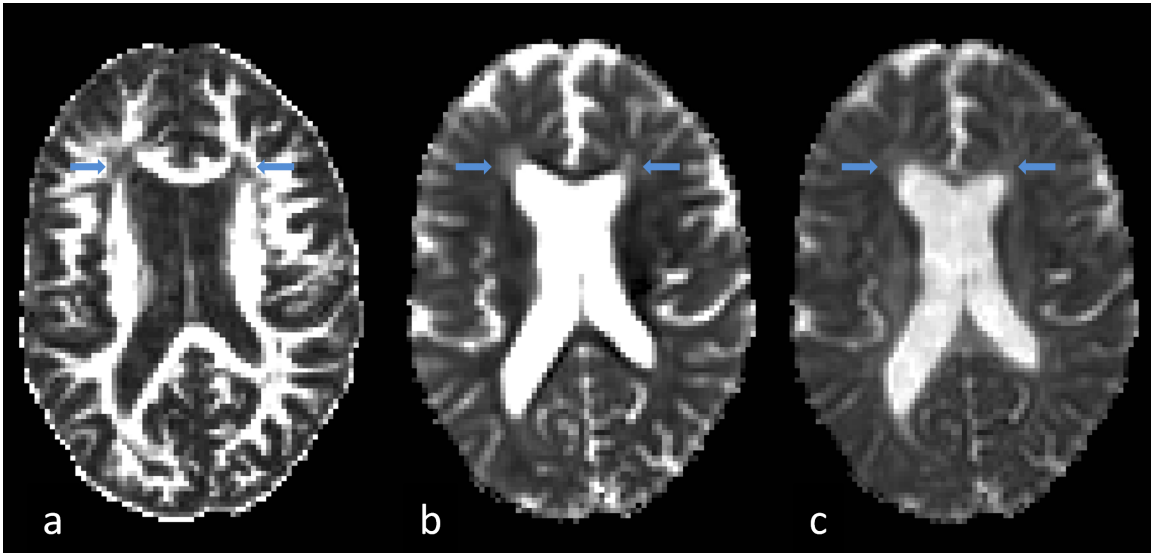
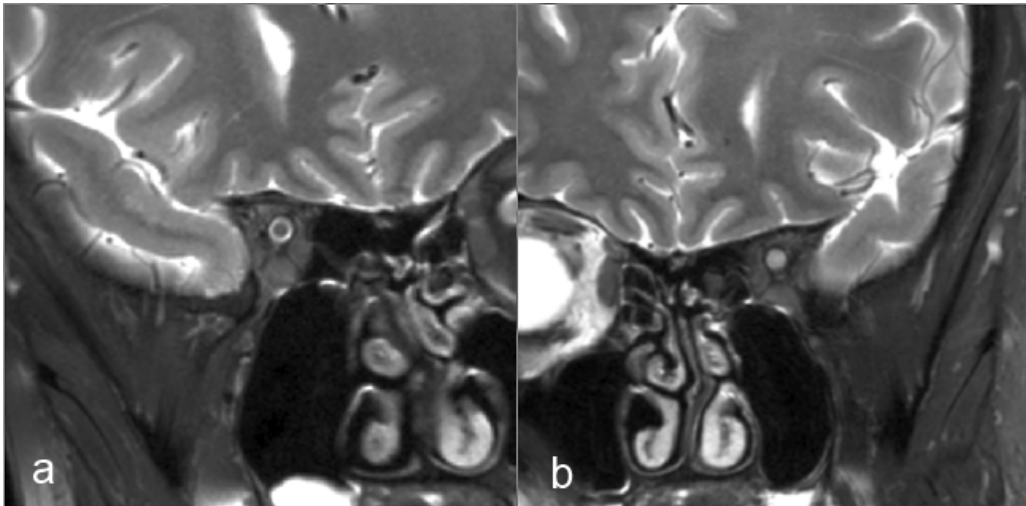


Supplementary Figure 1: Axial DTI of corresponding slices of the brain of an MS patient demonstrating a) fractional anisotropy; b) radial diffusivity; c) axial diffusivity. Arrows highlight corresponding lesions on each sequence.



Supplementary Figure 2: Optic nerve imaging, using a T2-weighted (fat-suppressed) coronal-oblique sequence, demonstrating a) normal right optic nerve; b) left optic nerve with a lesion.



Supplementary Figure 3: Coronal-oblique magnetisation transfer imaging of the right optic nerve demonstrating a) MToff; b) MTon; c) MTR map

