

Unlocking the mysteries of TDP-43

Keith A. Josephs, MD,
MST, MSc
Peter T. Nelson, MD,
PhD

Correspondence to
Dr. Josephs:
josephs.keith@mayo.edu

Neurology® 2015;84:870–871

The neuropathology of dementia may not be in the consciousness of clinicians while evaluating patients with dementia. However, all clinicians should be aware of the importance of neuropathology to dementia diagnosis. For decades, β -amyloid deposited in senile plaques and tau in neurofibrillary tangles has dominated the dementia world, α -synuclein Lewy bodies being their sidekick. We now have a new member of the inner circle.

In 2006, investigators from the University of Pennsylvania reported that the transactive response DNA binding protein 43 (TDP-43) was aberrantly deposited in the brains of patients with amyotrophic lateral sclerosis and frontotemporal lobar degeneration (FTLD).¹ Little did they know how ubiquitous pathologic TDP-43 really was. A year later, investigators from the Mayo Clinic showed that pathologic TDP-43 was also present in the brains of patients with the most common cause of dementia, Alzheimer disease (AD).² TDP-43 is a nucleotide binding protein that is present in the cell nuclei of normal brain cells (figure) and helps to regulate RNA processing. When TDP-43 is hyperphosphorylated, it accumulates in the cytoplasm of the cells (figure), a process that is cytotoxic via gain- or loss-of-toxic function mechanisms. In AD, pathologic TDP-43 follows a stereotypical pattern of deposition that has been captured by the TDP-43 in AD (TAD) staging scheme³: TDP-43 first deposits in the amygdala (stage I), followed by hippocampus, limbic, temporal, and finally frontostriatum (stage V). The presence and burden of TDP-43 deposition modifies clinical and radiologic phenotype and are strongly associated with memory loss and hippocampal atrophy,^{4,5} the 2 cardinal clinical features of AD. This observed stereotypical pattern of deposition, and the clinical–pathologic correlation, suggest that TDP-43 should join the inner circle of neurodegenerative misfolded proteins that now include β -amyloid, tau, and α -synuclein.

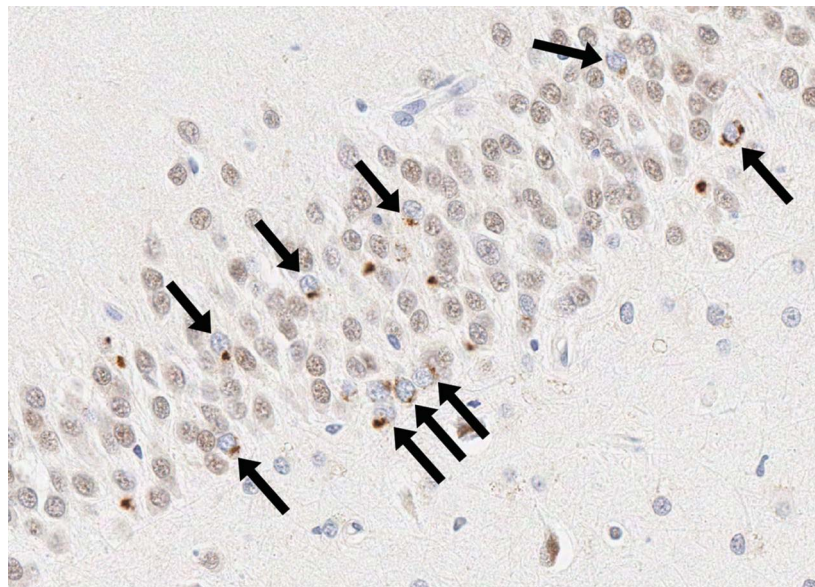
The sheer prevalence and influence of TDP-43 pathology are remarkable. This pathology occurs in almost 60% of brains of patients with AD,⁴ and also in 90% of cases of dementia associated with progressive neuronal loss and gliosis of the CA1 and subicular regions of the hippocampus,⁶ a phenomenon known as hippocampal sclerosis. Genetic risk factors for

hippocampal sclerosis in aged persons, recently characterized, reveal new insights into disease mechanisms. In contrast to AD, *APOE* alleles are not implicated in hippocampal sclerosis, whereas alleles in the genes *GRN*, *TMEM106B*, *ABCC9*, and *KCNMB2* are linked to this age-related hippocampal TDP-43 pathology.^{7–9}

In this issue of *Neurology*®, Yu et al.¹⁰ from Rush University Medical Center provide an important contribution related to the pathogenesis of TDP-43 pathology in older persons. This study focuses on the transmembrane protein 106B gene (*TMEM106B*), a genetic risk factor for the accumulation of abnormal TDP-43 in FTLD, AD, and hippocampal sclerosis. In their study of 544 autopsied participants from 2 community-based studies of aging, the authors confirmed that common variants in *TMEM106B* were indeed a distinct risk factor for TDP-43 pathology in older patients. This observation again underscores the importance of pathology-based endophenotypes in studies related to genetic risk factors. Capitalizing on their outstanding clinically and pathologically evaluated research cohort, the study delves into the complex interrelationships among comorbid pathologies of older persons that include AD, α -synucleinopathy, hippocampal sclerosis, and TDP-43 pathology. The authors also aimed to better understand the biological mechanisms underlying the relationship between *TMEM106B* variants and the deposition of TDP-43. This study breaks new ground by exploring novel pathways involving DNA methylation and miRNA and mRNA expression. Their data and analyses provide key support for the hypothesis that *TMEM106B* variants are pathogenetically important and exert their influence upstream of expression of *GRN*, a gene that is also strongly implicated in FTLD pathogenesis. A more theoretical mechanism is hypothesized related to increased inflammation of the brain although the exact mechanism remains elusive. The big picture is that heritable factors have strong influence on late-life neurologic conditions. While daunting to consider the importance of genes in dementia risk, this story could have a silver lining, whereby therapeutic intervention could occur at the preclinical stage in individuals genetically determined to be at risk of having TDP-43-associated dementias.

See page 927

From the Department of Neurology (K.A.J.), Mayo Clinic, Rochester, MN; and Department of Pathology (P.T.N.), University of Kentucky, Lexington. Go to Neurology.org for full disclosures. Funding information and disclosures deemed relevant by the authors, if any, are provided at the end of the editorial.



Transactive response DNA binding protein 43 (TDP-43) immunohistochemistry in the brain of a patient with dementia shows normal nuclear TDP-43 staining in many cells, as well as pathologic TDP-43 in the cytoplasm of some cells (arrows). Note the absence of normal nuclear TDP-43 staining in the cell when pathologic TDP-43 is observed in the cytoplasm. Image taken from the dentate gyrus of the hippocampus.

There is no turning back from this developing story of dementia due to multiple proteins and mixed pathologies. It is the rule, and not the exception, for older persons' brains to harbor multiple comorbid pathologies, and TDP-43 is a prime player. This important new study highlights the importance of better delineation of the currently indistinct boundary areas among AD, hippocampal sclerosis, and TDP-43 pathology in advanced old age. Future studies are also needed to determine whether there are other risk factors for the deposition of TDP-43, to better understand the mechanism of TDP-43 transformation to pathologic TDP-43, for the development of biomarkers that can detect TDP-43 antemortem, and the ultimate goal of therapeutic interventions that target pathologic TDP-43.

STUDY FUNDING

No targeted funding reported.

DISCLOSURE

K. Josephs receives research support from the NIH (NIA and NIDCD) and the Alzheimer's Association. P. Nelson receives research support from the NIH (NIA and NINDS) and the Alzheimer's Drug Discovery Foundation. Go to Neurology.org for full disclosures.

REFERENCES

1. Neumann M, Sampathu DM, Kwong LK, et al. Ubiquitinated TDP-43 in frontotemporal lobar degeneration

and amyotrophic lateral sclerosis. *Science* 2006;314:130–133.

2. Amador-Ortiz C, Lin WL, Ahmed Z, et al. TDP-43 immunoreactivity in hippocampal sclerosis and Alzheimer's disease. *Ann Neurol* 2007;61:435–445.
3. Josephs KA, Murray ME, Whitwell JL, et al. Staging TDP-43 pathology in Alzheimer's disease. *Acta Neuropathol* 2014;127:441–450.
4. Josephs KA, Whitwell JL, Weigand SD, et al. TDP-43 is a key player in the clinical features associated with Alzheimer's disease. *Acta Neuropathol* 2014;127:811–824.
5. Wilson RS, Yu L, Trojanowski JQ, et al. TDP-43 pathology, cognitive decline, and dementia in old age. *JAMA Neurol* 2013;70:1418–1424.
6. Nelson PT, Schmitt FA, Lin Y, et al. Hippocampal sclerosis in advanced age: clinical and pathological features. *Brain* 2011;134:1506–1518.
7. Nelson PT, Estus S, Abner EL, et al. *ABCC9* gene polymorphism is associated with hippocampal sclerosis of aging pathology. *Acta Neuropathol* 2014;127:825–843.
8. Murray ME, Cannon A, Graff-Radford NR, et al. Differential clinicopathologic and genetic features of late-onset amnesic dementias. *Acta Neuropathol* 2014;128:411–421.
9. Beecham GW, Hamilton K, Naj AC, et al. Genome-wide association meta-analysis of neuropathologic features of Alzheimer's disease and related dementias. *PLoS Genet* 2014;10:e1004606.
10. Yu L, De Jager PL, Yang J, Trojanowski JQ, Bennett DA, Schneider JA. The *TMEM106B* locus and TDP-43 pathology in older persons without FTL. *Neurology* 2015;84:927–934.