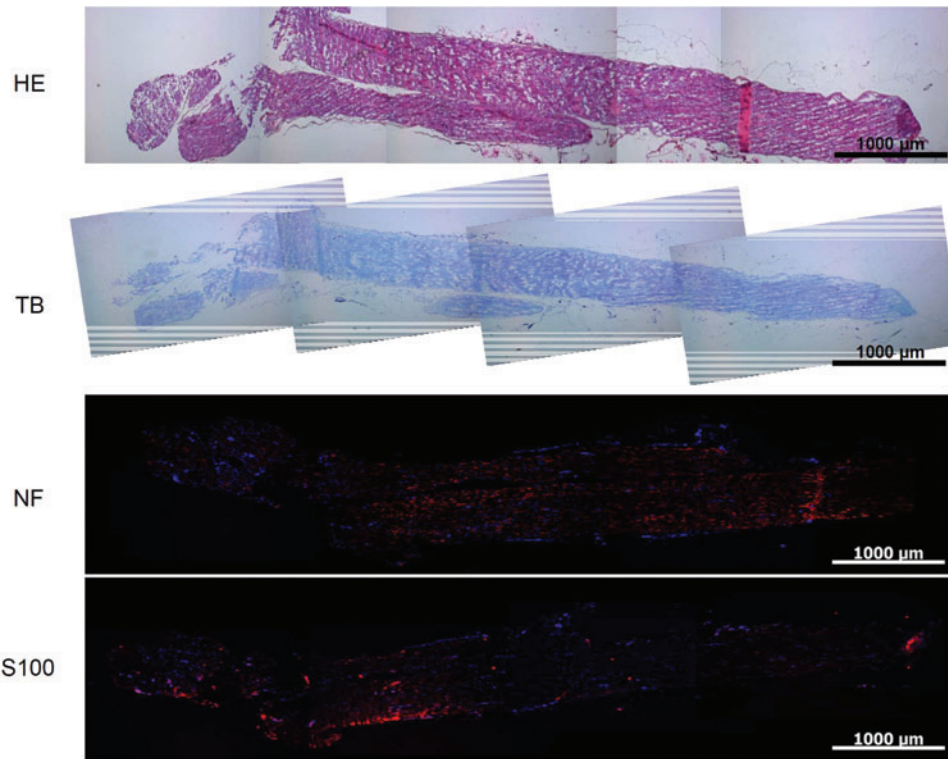


Supplementary Data



SUPPLEMENTARY FIG. S1. H&E, TB, NF, and S100 staining of normal sciatic nerve. H&E, Hematoxylin and Eosin; NF, neurofilament; TB, Toluidine Blue.