

INCREASED ELASTIC TENSION OF THE LUNG IN EXPERIMENTAL PNEUMONIA

BY C. M. VAN ALLEN AND C. WU

*(From the Departments of Surgery and Radiology, Peiping Union Medical College,
Peiping, China)*

(Received for publication January 30, 1932)

A well recognized phenomenon of pneumonia is reduction of respiratory motion on the side of the chest occupied by the lesion. Restriction of costal movement is usually plainly apparent to the bedside observer, and this together with elevation and restriction of the hemidiaphragm may be distinguished by aid of the x-ray (1, 2, 3, 4). Our own observations of these signs in man, which are to be published elsewhere, were assisted considerably by the use of a double-exposure roentgenographic method (5) whereby the shadows of the pulmonary environs at inspiration and at expiration were superimposed on the same film for comparison. The ribs and diaphragm on the side of the lesion were shown characteristically to move less than normal and to confine their excursions to the expiratory portions of their normal ranges of motion, even during maximum efforts to inspire. When pneumonia was limited to one lobe, the ribs overlying that part were often more restricted than were those over the normal lobes on the same side. The diaphragmatic dysfunction was usually greater when the lesion was in the lower lobe than when it was in the upper, and was greatest when the entire hemilung was consolidated to some extent. On the other hand, the diaphragm moved normally in many cases when only one lobe, whether the upper or the lower, was involved. Sometimes the heart shifted slightly toward the diseased lung at inspiration, while it occupied a normal position at expiration.

Three causes have generally been assigned for the abnormalities of respiratory movement in pneumonia, namely, reflex spasm or inhibition of the respiratory muscles, blockage of the alveoli and ducts with inflammatory exudate, and collapse of the alveoli. In the presence of sharp pleuritic pain the intercostal muscles become obviously spastic, from both voluntary and involuntary protective reactions; but without the pain, although breathing movements are greatly reduced on the side of the lesion, spasticity is less well defined or cannot be demonstrated at all. A certain amount of evidence is available to suggest that under the latter conditions the muscles are inhibited. Heuer and Holman (6) and others (7) have shown that artificial stimulation of the central stump of a

divided vagus nerve in animals causes the diaphragm temporarily to cease moving and to assume the elevated position of complete relaxation, and they interpret the effects as due to inhibition of the phrenic nervous centers. Furthermore, Newburgh, Means and Porter (8) found that in pneumonia the vagi carry centripetal impulses which act upon the respiratory centers to render the respirations shallow and rapid. It may well be, therefore, that the reduction of costal and diaphragmatic excursions which is under discussion is produced by inhibitive impulses from the lungs (2). The second and third causes for the abnormalities of breathing are perhaps more manifest than the first, since with the alveoli rendered unavailable for reception of air, either because they are filled with exudate or collapsed, that part of the lung cannot expand at inspiration and probably impedes the expansion of the adjacent region of the thoracic parietes. A common observation at autopsy is that consolidated areas in pneumonic lungs expand poorly or not at all when the lungs are excised and then inflated by blowing into the trachea (9, 10). The space normally intended for air is occupied by fluids. Coryllos (10) believes that atelectasis occurring in the early stages of pneumonia is chiefly responsible for the changes in position and motion of the breathing parts.

The changes in breathing in our clinical cases were not always easily explained by these hypotheses, because they were often found before any consolidation of the lung was demonstrable and remained for some time after consolidation and all outward signs of pulmonary irritation had gone. In one instance elevation and confinement of the diaphragm persisted for more than three weeks after complete re-aeration of the lung had occurred and cough had disappeared. Reflex nervous inhibition could account for the changes during the preconsolidative stage, for the lungs were then distinctly catarrhal, but that seemed probably not to be the cause for them late in the recovery period. An hypothesis hitherto unconsidered presented itself, that alterations in elasticity of the lung parenchyma occurred at these stages of the disease and were chiefly responsible. This seemed the more likely because soft tissues in other parts of the body become stiffer than normal during, and for a period after, the presence of acute inflammation, and because increased elastic tension of the pulmonary alveolar and lobular septa at the pre- and post-consolidative periods of pneumonia would be expected to increase the resistance to pulmonary inflation and impede the excursions of the thoracic parietes.

The elasticity of the lungs has been the subject of much investigation. Perhaps the best work on the normal lungs is that of Cloetta (11). As to the pathological changes in this property, interest has centered principally in the loss of tension in emphysema (12, 13, 14). The statement that the elastic tension is increased in pneumonia appears here and there

in the literature (15), but few writers have made direct measurements to prove the truth of the assertion. Perls (14), in 1869, attached a manometer to the trachea of human subjects dead of various diseases, then opened the chest and read the manometric pressure produced by the recoil of the lungs. He found greater pressures in cases with pneumonic consolidation than in those with normal lungs. However, he was not satisfied with the results because of the postmortem changes that had occurred before autopsy, and others (14) have not accepted them for the same reason. Coryllos states, and it is our experience too, that human lungs at autopsy frequently leak air from the pleural surfaces on inflation so freely as to interfere with the results of such experiments. Bittorf and Forschbach (16) insufflated the trachea of human subjects with air after death without opening the chest and measured the pressure necessary to expand the chest. They found increased pressures in the presence of pneumonic consolidation. Tendeloo, Hennemann and Metz (12) tested strips of tissue excised from the cortex of lungs of man. The length of each strip was measured, the strip was stretched momentarily to a certain degree, and the length after relaxation was determined. The degree of approach to the initial length was used as the index of elasticity. The specimens from consolidated lungs proved considerably less elastic than those from normal lungs. Apparently only Joannides and Steinman (17) have paid attention to the nonconsolidative stages of pneumonia. They reported from microscopic study of the living dog's lung that the alveolar walls were thicker and seemed to stretch at inspiration less easily than normal when pneumonia was incipient and the air spaces and passages were still patent.

The experiments to be described were designed to determine from freshly excised lungs of dogs to what degree the pulmonary tissues develop increased elastic tension in pneumonia, especially before and after the period of consolidation, and how much this affects the gross pulmonary expansion. Dogs were chosen as subjects because they are known, after proper intrapulmonary inoculation, to run a course of pneumonia that closely resembles the spontaneous lobar pneumonia in man.

EXPERIMENTAL MATERIALS AND METHODS

Pneumonia was produced in 13 dogs by the method of Terrell, Robertson and Coggeshall (18, 19), with the modification that inoculation was done with the aid of bronchoscopy. The bronchi of the right lower lobe were examined by x-ray from day to day. Three were sacrificed at what seemed to be the height of pneumonic consolidation, 3 to 7 days after inoculation; and the remaining five were sacrificed 2 to 6 days after disappearance of consolidation, which was 14 to 17 days after inoculation.¹ The animals were electrocuted

¹ "As a rule, within 24 hours after inoculation typical consolidation of the injected lobe has occurred. . . . The disease runs a febrile course of 3 to 7 days; the pneumonic lesion either remains localized in one lobe or spreads from lobe

to avoid the agonal changes frequently produced in the lungs by other methods of killing. Autopsy was begun by exposing and clamping the trachea in the neck. The chest was opened and the lungs were examined, special note being made of the relative sizes of the lower lobes, inflated as they then were to the degree of passive expiration.² All vessels supplying the lower lobes were ligated to retain the fluids, and the lungs were removed *en masse* from the

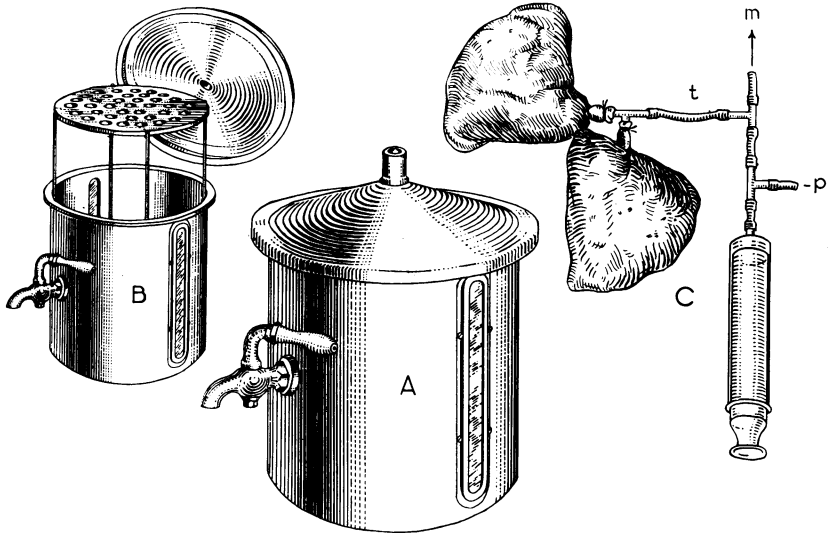


FIG. 1. APPARATUS FOR INFLATING EXCISED PULMONARY LOBES WITH EQUAL, MEASURED PRESSURES OF AIR AND DETERMINING THEIR VOLUMES

The volumetric chamber is represented at A. It is shown again at B with cover and platform lifted for insertion of a lobe. At C are two lower lung lobes attached to the same system of tubes and syringe for inflation. The manometer which is connected at *m* is not shown. The tube at *p* is opened for admission of air to the syringe, and the tube at *t* is opened only when the tube at *p* is closed for injection of the air into the specimens.

to lobe. This experimental disease resembles the natural disease in humans in the manner of spread of the lesion, the localization of the process, the immune response, the abrupt termination of the disease by crisis, lysis, or death, and the rapid regression of the process after recovery. . . . With the evolution of the disease the lesion progresses through the different stages observed in the human pneumonic lung. . . ." (18)

Many more dogs were inoculated than those enumerated above, but they were discarded, either because x-ray examination during life or after death showed pneumonia in the left lower lobe or only abortive pneumonia in the right lower lobe; or because the lobes were accidentally punctured at the time of removal and leaked air on reinflation.

² Attempts were made in the earlier experiments to measure accurately the volume of each of the lower lobes in this state of inflation, but without success because the handling of the lungs incident to their removal and preparation for such measurement necessarily caused displacement of air from lobe to lobe and marked changes in size of the lobes.

chest. The stem bronchi of all but the two lower lobes were now ligated and then divided peripheral to the ligature, which left the primary bronchi airtight and only the lower lobes attached. The clamp on the trachea was removed, the lobes were allowed to collapse, and a photograph and a roentgenogram were made. Each primary bronchus was then ligated near its origin at the trachea and was divided between the ligature and the trachea.

The volume of each lobe was obtained by immersion in water in a specially constructed chamber (Fig. 1, *A* and *B*). This was a cylindrical metal vessel fitted with a spigot and covered with a conical plate that was ground to fit the top accurately. The cover was perforated at the peak by a short tube. A removable platform was contained in the vessel. The chamber was made ready for use by greasing the margin of the cover, fitting it in place, and filling the chamber with water until the meniscus appeared at the top of the tube in the cover. The spigot was next opened and sufficient water was let out to enable the cover to be removed and one of the lobes to be introduced under the platform without spilling any water. The cover was replaced and the water that had been let out was poured through the tube back into the chamber until

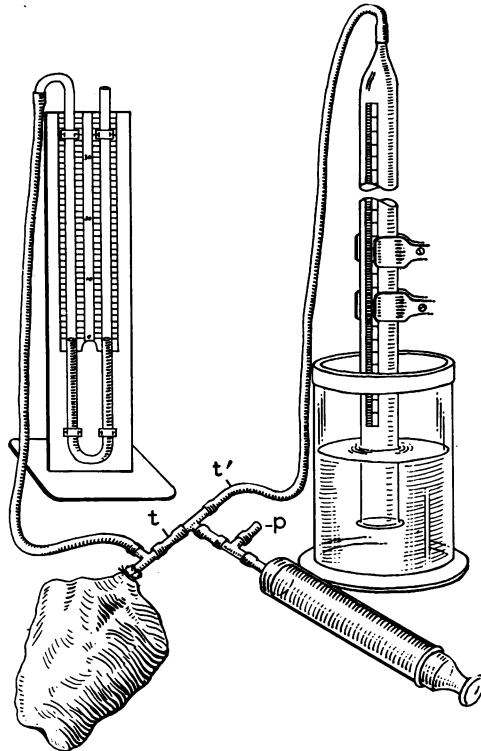


FIG. 2. APPARATUS FOR INFLATING AN EXCISED LOBE WITH A MEASURED AMOUNT OF AIR AND DETERMINING THE INTRAPULMONARY PRESSURE

The tube at *p* is opened only to adjust the water level in the burette to the lowest mark on the scale and then closed. The tubes at *t* and *t'* are opened and closed as necessary while pumping air from the burette into the specimen.

the meniscus appeared again at the top. The volume of water left over was taken as the volume of the lobe. After measuring both specimens in this way, the ligatures were removed from the bronchi and the bronchi were applied and held with ligatures on two limbs of a T-shaped cannula. The other limb of the cannula was connected with rubber tubes to a water manometer and a syringe (Fig. 1, C); and the specimens were simultaneously inflated with air from the syringe until all parts of the left (normal) lobe were inflated to an extent that was judged to represent natural, moderately full inspiration. The pressure was then adjusted to 10 cm. H₂O by removing a little air. Each bronchus was ligated right next to the cannula, to maintain the inflation, and was freed from the cannula. Once more each lobe was measured volumetrically, photographed and roentgenographed.

After this the ligatures were taken off, the air was allowed to escape, and the bronchus of the right (pneumonic) lobe alone was cannulated and was connected to a water manometer, a syringe, and a burette which had been inverted and placed with the lower end in a dish of water (Fig. 2). The water level in the burette was adjusted to the lowest mark on the scale, and then air was drawn from the burette by the syringe and deposited in the lobe until the nonconsolidated portions of the lobe were fully inflated.³ The amount of air required to do this and the manometric pressure were noted. The lobe was replaced by the other and the test was repeated; this time, however, using only the amount of air injected into the first lobe.

Finally, the lobes were sectioned at numerous places, including the most consolidated and most air-containing regions, for gross and microscopic examination.

The entire procedure, except for the inoculation, was applied to 5 other dogs, to obtain normal controls.

RESULTS

The data thus obtained for each lobe of every pair included (1) the relative size at natural expiration, (2) the absolute size at complete collapse, (3) the absolute size at inflation with equal pressures as at natural inspiration, (4) the pressure at inflation with equal amounts of air, and (5) the gross, microscopic and roentgenographic appearances of the tissues. The measurements from the four groups of dogs are given in the tables.

(1) *Size at expiration.* The two lobes appeared to be very nearly, if not quite, the same size, whether pneumonia was present or not and whatever was the stage of the lesion.

(2) *Size at collapse.* In the control dogs the two lobes showed very little difference in size, the greatest difference being 7 per cent. In 3 of them the right lobe was the larger, and in 2 the left was the larger. At the preconsolidative stage of pneumonia the right lobe was larger by 6 to 11 per cent; at the consolidative stage the right was larger by 2 to 34 per cent; and at the postconsolidative stage the right was the same size as the left in 1 case, 2 per cent smaller in 1 case, and 3 to 9 per cent larger in 3 cases. (Figure 4.)

³ Attempt was not made to equalize the water-levels of the burette before taking the manometric reading, because the difference of level was exactly the same with the two lobes and we were interested only in comparative pressures.

(3) *Size at inspiration.* The lobes from the control dogs had slight differences in size, the greatest difference being 8 per cent. In 2 of them the right was the larger, and in 3 the left was the larger. At the preconsolidative stage the left lobe was larger by 13 to 48 per cent; at the consolidative stage the left was larger by 40 to 60 per cent; and at the post-consolidative stage the left was larger by 19 to 39 per cent. (Figure 4.)

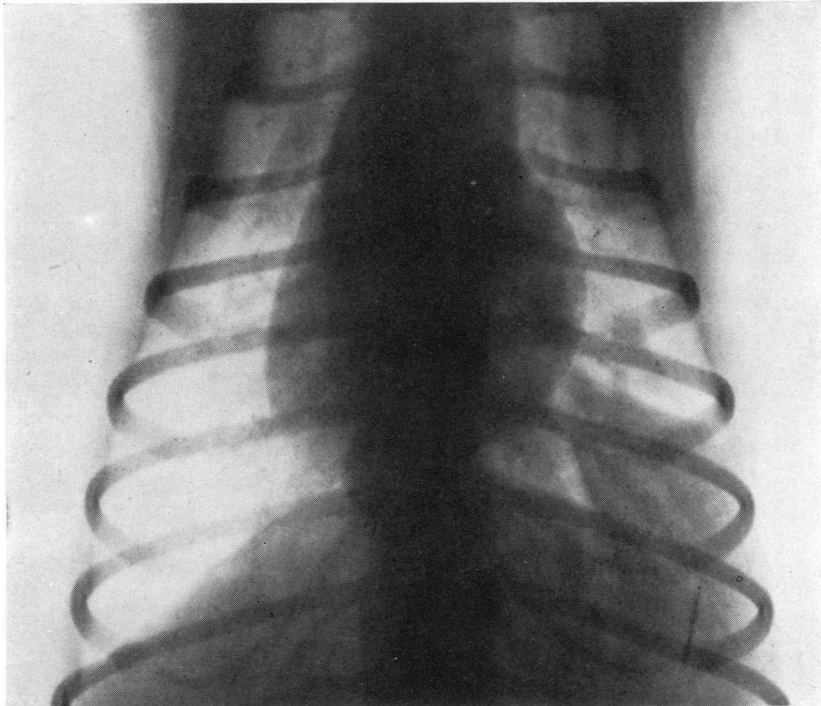


FIG. 3. ROENTGENOGRAPHIC APPEARANCE OF A DOG'S CHEST 3 DAYS AFTER INOCULATION OF THE RIGHT LOWER LOBE WITH PNEUMOCOCCUS

The lobe (on the right) is seen to be completely consolidated and the right hemidiaphragm to be slightly elevated.

(4) *Pressure at inspiration.* The lobes from the control dogs exhibited a fair degree of uniformity of pressure, the greatest difference being 16 per cent. In 1 of them the pressure was the same, in 2 that of the right was the greater, and in 2 that of the left was the greater. At the preconsolidative stage of pneumonia the pressure of the right lobe was greater by 23 to 38 per cent; at the consolidative stage that of the right was greater by 42 to 75 per cent; and at the recovery stage that of the right was greater by 11 to 43 per cent.

(5) *Appearance.* The lobes of the control dogs had no significant alterations.

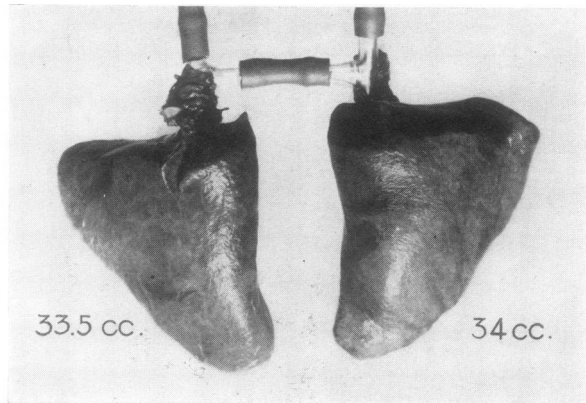
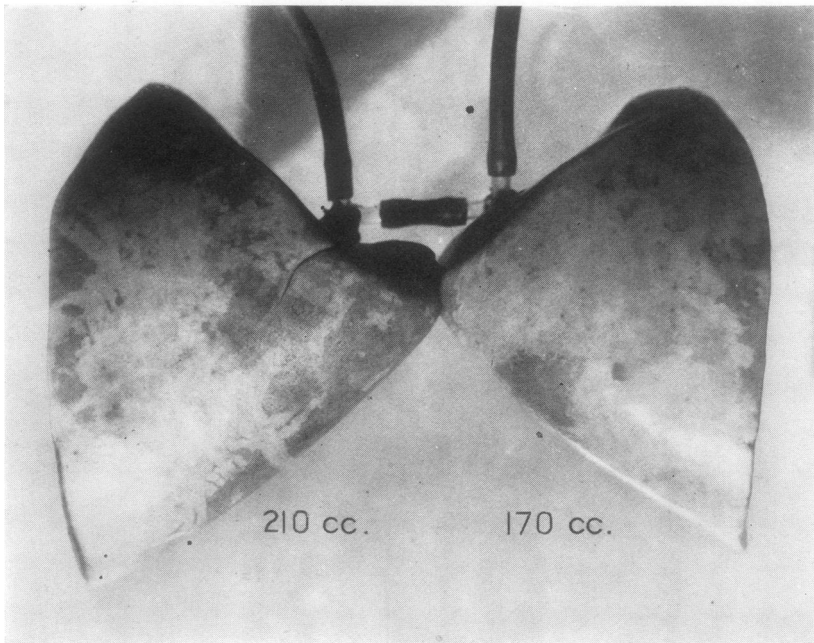
*A**B*

FIG. 4. THE TWO LOWER LOBES OF THE DOG OF FIGURE 3, REMOVED 17 DAYS AFTER INOCULATION AND 7 DAYS AFTER DISAPPEARANCE OF CONSOLIDATION

The lobes are collapsed at *A* and expanded at *B*; and the corresponding volumes are inscribed. Note the lack of consolidation in both lobes, the approximate equality of size at collapse, and the smaller size of the inoculated lobe (on the right in each view) at expansion.

Both lobes of the inoculated dogs presented gross changes at the pre-consolidative stage, the right, however, much more than the left. The right lobe was redder than normal throughout, particularly along the medial border and about the hilus. Numerous petechiae were scattered over the surface at various points, also more especially at the medial border and hilus. The tissues were everywhere crepitant and seemed slightly heavier than normal. Section showed the parenchyma to be red and wet in those regions with the greater surface changes, and to be practically normal in other parts. No consolidation was discernible. The left lower lobe presented slight superficial redness limited to the medial aspect of the hilic region and redness and wetness of the parenchyma beneath, but it was normal elsewhere. The peribronchial connective tissues and lymph nodes of both lobes were somewhat edematous. Microscopic examination revealed an air-containing condition throughout in both lobes, except for a few small areas in the cortex of the right lobe at the hilic region where a few of the alveoli were filled with erythrocytes and edema fluid. The capillaries and smaller arterioles and venules were dilated with blood in many parts of the right lobe but only in the hilic region of the left lobe. In these places the alveolar walls were two or three times the normal thickness, due to the presence of dilated capillaries, increased interstitial fluids, and a few lymphocytes. The alveolar sacs were contracted to one-third or one-fourth the normal size in most instances. In other parts of both lobes there was no alteration. The bronchi and bronchioles were empty.

At the consolidative stage, the right lobe was one-eighth to four-fifths airless. The solid portions were sharply demarcated and occupied principally the hilus and body of the lobe, while the air-containing parts were mostly at the periphery. The former were swollen and dark purplish red with smooth lusterless surfaces. Section presented a bulging, dry and granular surface in some parts of the consolidated parenchyma, a concave, dry and smooth surface in others, and a moist and somewhat crepitant zone at the periphery; while it showed the air-containing tissues to be without gross abnormality save for slight redness and wetness of the cut surfaces. The left lobe was unaltered grossly except for a little redness and wetness of the tissues near the hilus. The peribronchial tissues and lymph nodes of both lobes were hugely swollen and edematous. Microscopic study of the right lobe showed wide areas of pneumonic consolidation beside narrower ones of atelectasis. The vessels were all markedly engorged and the bronchial passages, large and small, were choked with polymorphonuclear leukocytes, erythrocytes, epithelial debris and fluid. Sections from other regions showed the alveoli and bronchi free from exudate. Here, for the most part, the alveolar and lobular septa were distinctly thickened and the alveolar spaces were correspondingly narrowed. Again the septal thickening was due to cap-

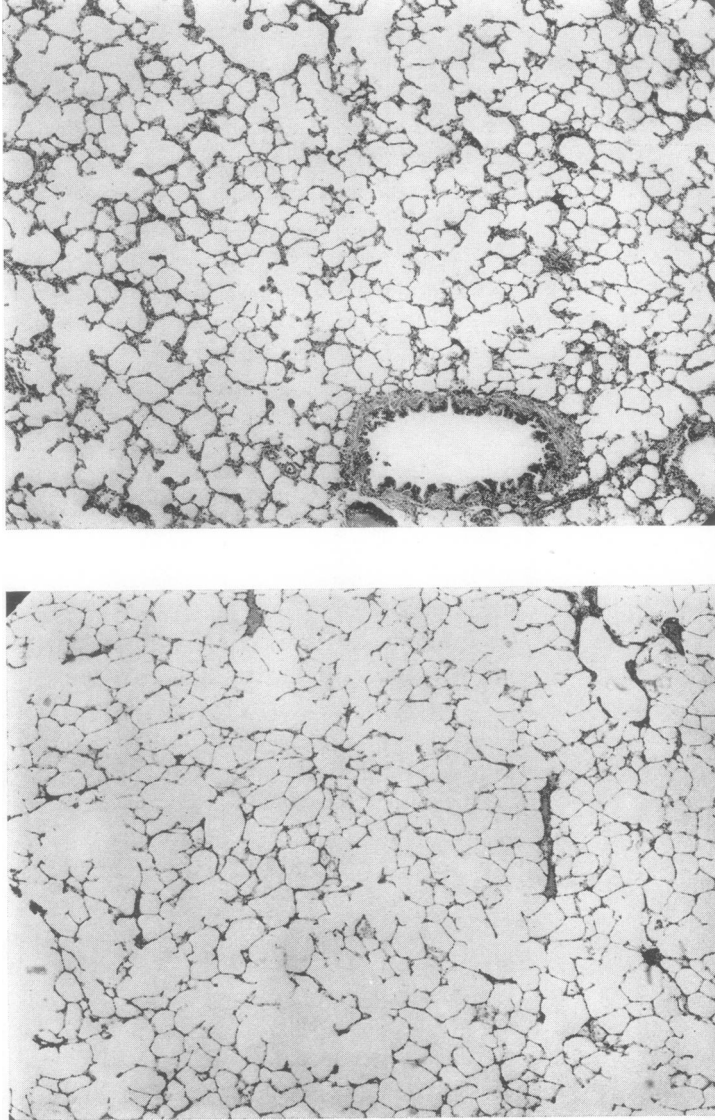


FIG. 5. MICROSCOPIC APPEARANCES OF THE LOBES OF FIGURE 4
The inoculated lobe (on the right) shows alveolar and bronchial patency but thickening of the alveolar septa. The uninoculated lobe shows no abnormalities.

illary engorgement and interstitial accumulation of wandering cells and fluid. The left lobe presented no histological changes except in sections from the hilic region where the vessels were engorged and the alveolar septa were slightly thickened.

All animals sacrificed at the postconsolidative stage exhibited at x-ray examination during the first week of the infection complete consolidation of the right lower lobe. At autopsy, however, there was extremely slight gross abnormality of the lungs. This appeared only in two cases and was confined to the inoculated lobe. Near the hilus were small red and wet, but crepitant, patches. Otherwise the right lobe appeared normal. (Figure 3.) The peribronchial tissues on the right were moderately edematous, and the lymph nodes in this neighborhood and throughout the mediastinum were markedly enlarged and succulent. Fine brick-red granules lay scattered abundantly in the mediastinal and pericardial membranes. Histologically the parenchyma of both lower lobes was completely air-containing, except for an occasional alveolus or small group of alveoli situated near the pleura in the right lobe which was filled with clear fluid or was collapsed. The capillaries and small vessels in all parts of this lobe were slightly dilated, the interstitial fluids were slightly increased, and this caused the alveolar and lobular septa in most places to be distinctly thickened. The septal change was the chief characteristic of the right lobe, and it was in most cases entirely absent in the left lobe. (Figure 5.) The pleural membrane of the right lobe was also definitely thickened, due chiefly to proliferation of fibroblasts and somewhat to increase of interstitial fluids and cells.

CONCLUSIONS

(1) The elastic tension of the dog's lung becomes markedly increased in pneumonia within a few hours after entrance of the organisms, before blockage of the air passages and spaces with inflammatory exudate; also, for several days after reinflation of the parenchyma. No conclusion is drawn as to the elastic tension during consolidation, since exudate in the bronchi and alveoli interferes with the inflation required for the tests.

(2) The increase of elastic tension is probably due to thickening of the alveolar and lobular septa and, in the postconsolidative stage, also to thickening of the pleura.

(3) The size of the lung is changed in pneumonia. In the preconsolidative period, the infected lobe is larger than normal⁴ when fully collapsed, about normal in size when inflated at expiration, and smaller

⁴ "Normal size," with reference to the right lobe, refers to the size of the left lobe, rather than to the absolutely normal size of the right lobe. This basis of comparison is the more pertinent of the two for the object of the experiments. The lower lobes of the dog lent themselves well for comparison since they were normally very similar in size. See Table 1.

than normal when inflated at inspiration. In the consolidative period, the lobe is larger than normal at collapse, about normal at expiration, and smaller than normal at inspiration. In the postconsolidative period, the lobe is about normal in size at collapse and at expiration, and it is smaller than normal at inspiration.

(4) Increased elastic tension of the parenchyma is probably chiefly responsible for the decreased size of the right lobe at inspiration during the pre- and postconsolidative periods. Increased content of inflammatory products of the lobe is evidently responsible for the increased size at collapse during the preconsolidative and consolidative periods. Blockage of the air passages and spaces with inflammatory products and foci of atelectasis (for the airless parts) and increased elastic tension of the tissues (for the air-containing parts) probably act together to cause the decrease in size at inspiration during the consolidative period.

(5) Without further study ⁵ it cannot be said how much this increased elastic tension interferes with respiration during life; but judging from the magnitude of the effects on the distensibility and size of the excised lobe which it causes, it may well be expected to curtail the respiratory movements of the ribs and hemidiaphragm adjacent to the inflamed part and to displace the mediastinum, to the extent to which these changes occur in clinical pneumonia.

(6) Since the lung shows unmistakable evidences of irritation throughout the period of experimental observation, it is possible that reflex nervous inhibition, as referred to in the introduction, occurs and contributes to the curtailment of respiratory movements in the pre- and postconsolidative stages of pneumonia, as well as in the consolidative stage.

COMMENT

Our histological findings of interstitial cellular infiltration in the early, preconsolidative stage of pneumonia correspond with those of Blake and Cecil (20) in their research on pneumonia in monkeys. They showed that after entrance to the large bronchi, the pneumococci quickly penetrate the bronchial walls and travel to the periphery in the peribronchial lymphatics and connective tissues, producing their first parenchymatous lesions in those tissues. Exudation into the bronchi and alveoli with consolidation followed that process.

It was said in the introduction that patients with inextensive pneumonia occasionally showed no detectable alterations of position and motion of the pulmonary environs. Considering increased elastic tension of the lung as the cause of the alterations, this is not surprising, for the powerful action of the respiratory muscles would be expected completely to overcome small increases in elasticity, at least as far as their extrinsic influences are concerned.

⁵ This study is now in progress.

Whether or not extrinsic effects develop, certain intrinsic ones would be expected to do so, in all stages of pneumonia and in all extents of that disease short of total involvement of the hemilung. Since each half of the thorax is a single chamber filled with elastic pulmonary tissues and without partitions to prevent internal spatial rearrangements from taking place, the relatively tense inflamed parts of the lung should expand at inspiration less, and the uninflamed parts more, than normal. This would shift some of the work of breathing from the former to the latter tissues. During the consolidative stage of extensive subtotal pneumonia of the hemilung this shift occurs and is complete, as is well known, so that the alveoli of the uninflamed part become greatly over-expanded and emphysematous, which is detectable during life by physical signs (Skodaic resonance, etc.) and after death by persistence of dilated alveoli in the collapsed specimen as viewed at autopsy. But in the consolidative stage of inextensive pneumonia where a wide field of normal hemilung remains to take over the function, and in the pre- and postconsolidative stages of inextensive or moderately extensive pneumonia where the functional shift is partial, emphysema of detectable proportions would not be expected to develop and the reapportionment of function that takes place might well go unnoticed. Whether the effect of increased elastic tension is purely intrinsic or both in- and extrinsic, it is obviously an agent of rest for the inflamed tissues, which operates automatically from a very early to a very late period of the disease. It would be expected to act whether or not the inflammation progressed to consolidation.

The statement of the older pathologists that the pneumonic lung in man is larger than normal is based upon comparison at autopsy of the consolidated lobe with the collapsed, normal lobes. This, of course, agrees with our findings in dogs.

The belief of Coryllos that the smaller size of the pneumonic lung at inspiration is due to the presence of atelectasis may be true in the early consolidative stage of which he writes, as far as these data go, but at the pre- and postconsolidative stages it is clearly not due to atelectasis.

The elastic tension of the lung is known to become increased in another kind of pulmonary disease, namely, tuberculosis. There it is often brought strikingly to one's attention when artificial pneumothorax or phrenic paralysis is induced, for then selective collapse and healing of the diseased segment of lung may occur. This subject has been discussed at length recently by one of us (21). It seems probable that the increased tension that is responsible for selective therapeutic collapse in this disease is due in some part, too, to thickening of the pulmonary septa and membranes from dilatation of vessels and interstitial deposits of inflammatory fluids and cells.

TABLE 1
Observations on both lower lobes of normal control dogs' lungs.

Dog number	Lower lobes	Volumes of lobes when			Pressures in lobes when inflated by equal volumes of air
		Collapsed	Inflated by equal pressures of air		
		<i>cc.</i>	<i>cc.</i>	<i>per cent increase</i>	<i>cm. H₂O</i>
1	R	51	274	437	19
	L	50	275	450	19
2	R	36	237	558	24
	L	38	255	571	20
3	R	37	222	500	28
	L	40	237	492	25
4	R	57	331	480	22
	L	55	315	472	24
5	R	43	268	523	20
	L	42	265	531	22

TABLE 2
Observations on both lower lobes of dogs' lungs at the preconsolidative stage of pneumonia in the right lower lobe, 6 hours after inoculation.

Dog number	Lower lobes	Volumes of lobes when			Pressures in lobes when inflated by equal volumes of air
		Collapsed	Inflated by equal pressures of air		
		<i>cc.</i>	<i>cc.</i>	<i>per cent increase</i>	<i>cm. H₂O</i>
1	R	24	137	471	26
	L	22	188	755	19
2	R	37	155	318	24
	L	33	230	597	18
3	R	30	153	410	27
	L	28	180	543	20
4	R	44	243	452	26
	L	40	280	600	16
5	R	49	202	312	26
	L	46	265	476	20

SUMMARY

The fact is recalled that in clinical pneumonia may occur reduction of costal and diaphragmatic movements on the side of the lesion, together with lateral displacement of the mediastinum. The causes commonly

given for this are enumerated and discussed, and it is pointed out that they explain the phenomena well in the consolidative stage of pneumonia but not well in the pre- and postconsolidative stages. The hypothesis is advanced that the phenomena in the latter stages may be due to increase in the elastic tension of the inflamed tissues.

Experiments with dogs are described which show that inflamed pulmonary lobes at the pre- and postconsolidative stages of pneumonia possess markedly increased elastic tension, as indicated by reduction in

TABLE 3

Observations on both lower lobes of dogs' lungs at the consolidative stage of pneumonia in the right lower lobe, 3 to 7 days after inoculation

Dog number	Lower lobes	Fractions of lobes consolidated	Volumes of lobes when			Pressures in lobes when inflated by equal volumes of air <i>cm. H₂O</i>
			Collapsed	Inflated by equal pressures of air		
			<i>cc.</i>	<i>cc.</i>	<i>per cent increase</i>	
1	R	4/5	44	87	197	28
	L	0	29	146	503	8
2	R	4/5	49	122	249	24
	L	0	48	250	521	6
3	R	1/8	32	106	331	24
	L	0	30	272	907	14

TABLE 4

Observations on both lower lobes of dogs' lungs at the postconsolidative stage of pneumonia in the right lower lobe, 14 to 17 days after inoculation

Dog number	Lower lobes	Volumes of lobes when			Pressures in lobes when inflated by equal volumes of air <i>cm. H₂O</i>
		Collapsed	Inflated by equal pressures of air		
		<i>cc.</i>	<i>cc.</i>	<i>per cent increase</i>	
1	R	34	170	400	19
	L	34	210	518	17
2	R	45	214	375	28
	L	41	324	690	16
3	R	40	210	425	26
	L	41	342	733	19
4	R	32	134	318	25
	L	31	180	480	19
5	R	36	192	433	24
	L	34	256	653	16

size and elevation of the intrapulmonary pressure at inflation of the lobes. The increased tension appears to be due to thickening of the alveolar and lobular septa and pleural membranes from dilated capillaries and interstitial inflammatory fluids and cells. The changes of elasticity are great enough to account in considerable part at least for the alterations in movement and position of the pulmonary environs that occur clinically in pneumonia.

The change in elasticity is believed to have the effect also of shifting some of the work of breathing from the inflamed to the normal parts of the lung. The change is believed to be very similar to that which occurs in certain cases of pulmonary tuberculosis and which is responsible for selective collapse of the lung after pneumothorax and phrenicotomy.

BIBLIOGRAPHY

1. Pickhardt, O., *Arch. Surg.*, 1928, xvi, 192. Unresolved Pneumonia. A Surgical Analysis.
2. Cole, R., *Acute Lobar Pneumonia*. Nelson Loose-leaf Medicine, Thos. Nelson & Sons, London, i, 239.
3. Osler, W., and McCrae, T., *Modern Medicine*, iv, 170. Kimpton & Sons, London.
4. Belden, W., Quoted from Coryllos, P., ref. 10.
5. Jung, T., and Van Allen, C., *Nat. Med. J. China*, 1931, xvii, 195. A Method of Recording Respiratory Movements on a Single Roentgenogram.
6. Heuer, G., and Holman, E., *Med. Bull. Univ. of Cincinnati*, 1923, ii, no. 1. Observations on the Position and Movements of the Diaphragm Following Injuries to and Surgical Procedures upon the Thorax: An Experimental Study.
7. Howell, W. H., *Text-book of Physiology*, Saunders & Co., Philadelphia, 1930, 11th ed., p. 708.
8. Newburgh, L., Means, J. H., and Porter, W. T., *Boston Med. and Surg. J.*, 1916, clxiv, 464. A Second Statement Regarding the Respiratory Mechanism in Pneumonia.
9. Holman, E., and Mathes, M., *Arch. Surg.*, 1929, xix, 1246. The Production of Intrapulmonary Suppuration by Secondary Infection of a Sterile Embolic Area.
10. Coryllos, P. N., *Surg., Gynec. and Obst.*, 1930, l, 795. Postoperative Pulmonary Complications and Bronchial Obstruction.
11. Cloetta, M., *Arch. f. d. ges. Physiol.*, 1913, clii, 339. Untersuchungen über die Elastizität der Lunge und deren Bedeutung für die Zirkulation.
12. Tendeloo, N., Hennemann, J., and Metz, G. A., *Krankheitsforschung*, 1929, vii, 163. Untersuchungen über Lungenemphysem und Lungenelastizität.
13. Von Neergaard, K., and Wirz, K., *Ztschr. f. klin. Med.*, 1927, cv, 35. Über eine Methode zur Messung der Lungenelastizität am lebenden Menschen, insbesondere beim Emphysem.
14. Perls, M., *Deut. Arch. f. klin. Med.*, 1869, vi. (Quoted from Tendeloo et al., ref. 12.)
15. De la Camp, O., *Spezielle Pathologie und Therapie innerer Krankheiten*, Urban & Schwarzenberg, Berlin, 1921, iii, 163. Die Lungenentzündungen.

16. Bittorf, A., and Forschbach, J., *Ztschr. f. klin. Med.*, 1910, lxx, 474. Untersuchungen über die Lungenfüllung bei Krankheiten.
17. Joannides, M., and Steinman, F. H., *Arch. Int. Med.*, 1931, xlvii, 24. The Mechanism of Pneumonia.
18. Terrell, E. E., and Robertson, O. H., *Proc. Soc. Exp. Biol. and Med.*, 1930, xxvii, 973. Production of Experimental Lobar Pneumonia in the Dog.
19. Terrell, E., Robertson, O., and Coggeshall, L., *J. Clin. Invest.*, 1931, x, 659. Experimental Lobar Pneumonia in the Dog.
20. Blake, F. G., and Cecil, R. L., *J. Exp. Med.*, 1920, xxxi, 445. Studies on Experimental Pneumonia. II. Pathology and Pathogenesis of Pneumococcus Lobar Pneumonia in Monkeys.
21. Van Allen, C., *J. Thoracic Surg.*, In press. Selective Collapse of the Lung after Phrenicotomy Comparable to that after Pneumothorax.