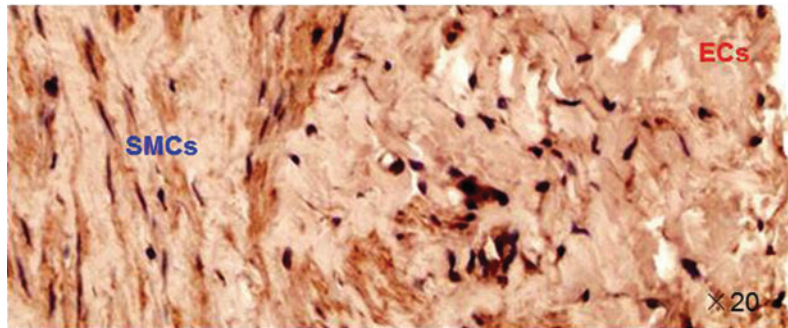


Normal human aorta



Atherosclerotic human aorta



SUPPLEMENTARY FIG. S2. Immunohistochemical staining for PCSK9 in normal and atherosclerotic human arterial sections. Note that the SMCs in atherosclerotic plaque show intense staining for PCSK9.