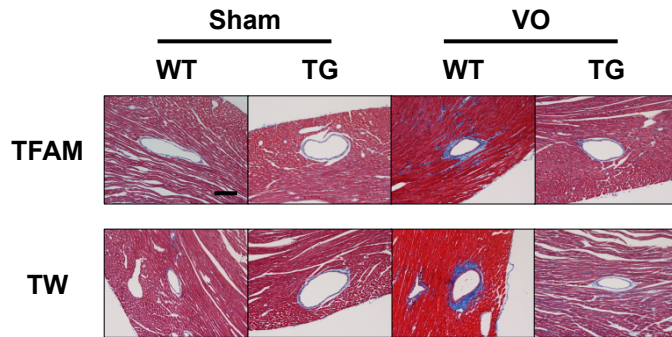


S2 Fig. Perivascular fibrosis and cross-sectional area of myocytes in LV eight weeks after AVF creation

A



B

