

Figure S6

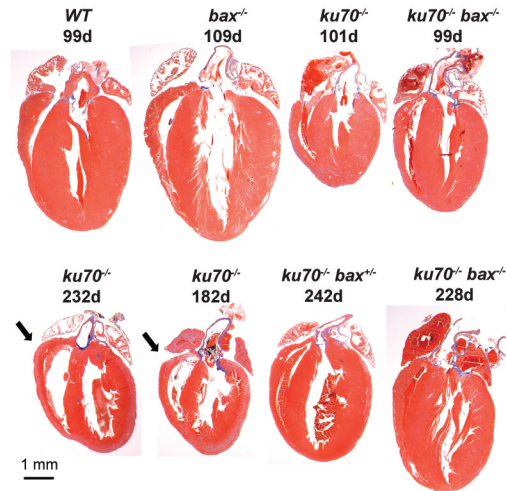


Figure S6. Masson's trichrome staining of heart sections showed no significantly detectable fibrosis (blue staining indicative of collagen deposition) within the cardiac chambers of 100 and 200 day old mice. A comparison of the hearts in a 4-chamber view is shown. Only the hearts from *ku70*<sup>-/-</sup> mice have enlarged right ventricles (arrow), a symptom of pulmonary hypertension.