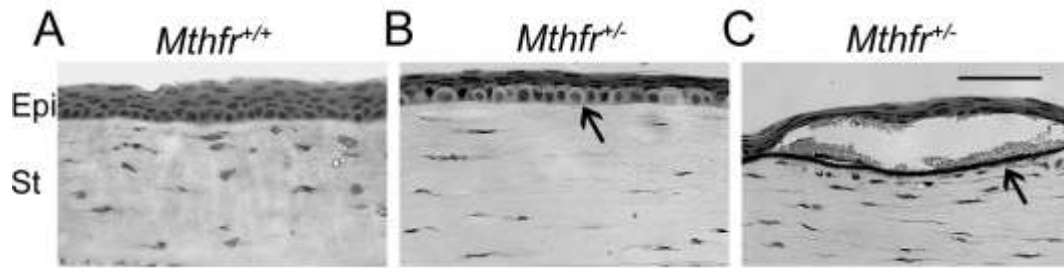


Supplemental Figure 1



Supplemental Figure 1. Corneal abnormalities in *Mthfr*^{+/-} mice.

Ocular cryosections from *Mthfr*^{+/+} and *Mthfr*^{+/-} mice at 24 wks were stained with hematoxylin and eosin and examined for morphological abnormalities. (A) *Mthfr*^{+/+} cornea, (B-C) *Mthfr*^{+/-} cornea. Some of the *Mthfr*^{+/-} mice had corneal abnormalities larger basal cells within corneal epithelium (arrow, B) and evidence of vascularization (e.g. lumen with red blood cells) on the corneal outer surface (arrow, D). Calibration bar = 50 μ M. Abbreviations: epi=epithelium; st=stroma.