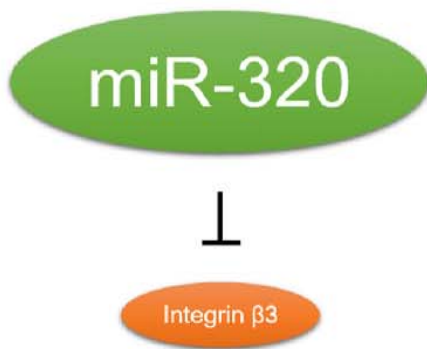


normal salivary epithelia



Salivary Adenoid Cystic Carcinoma (SACC)

