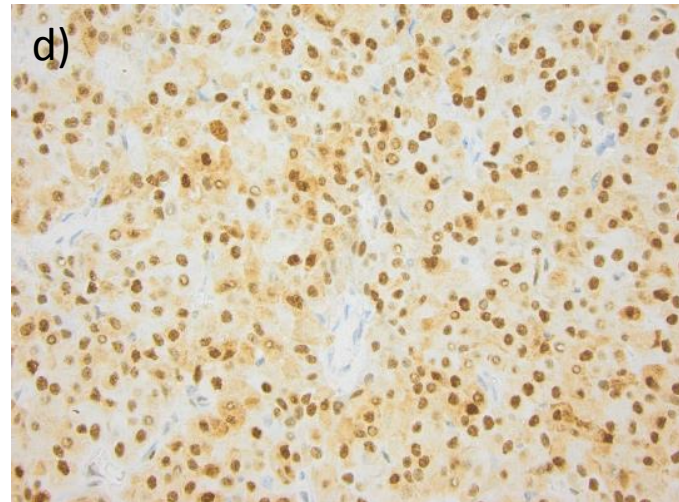
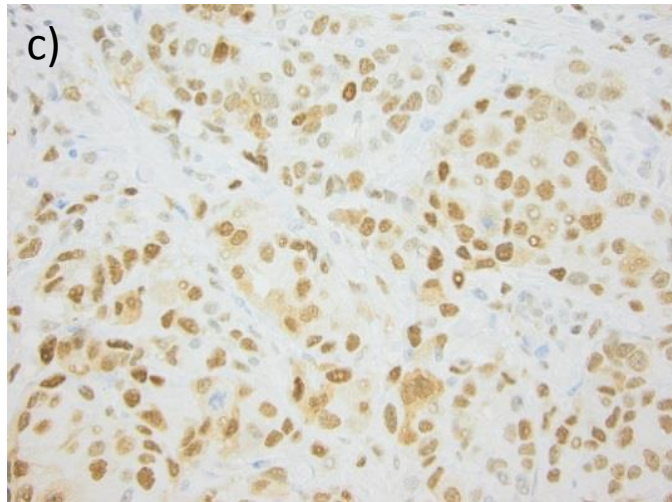
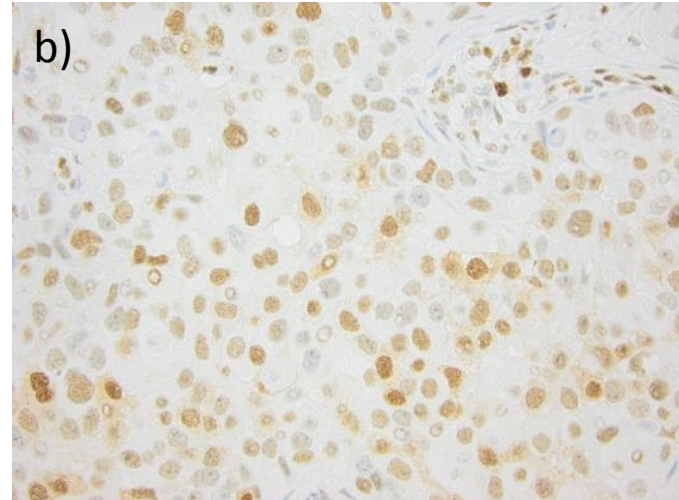
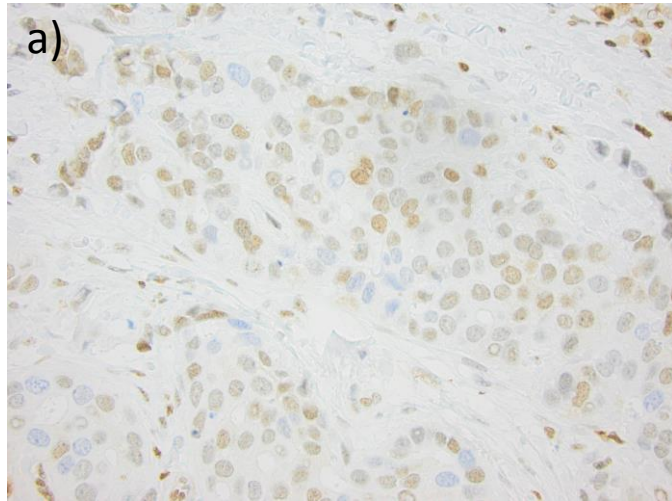


Supplementary Figure S2



Examples of immunohistochemical p27 staining with weak nuclear and negative cytoplasmic (a), moderate nuclear and weak cytoplasmic (b), moderate nuclear and cytoplasmic (c), and strong nuclear and moderate cytoplasmic (d) expression, respectively.