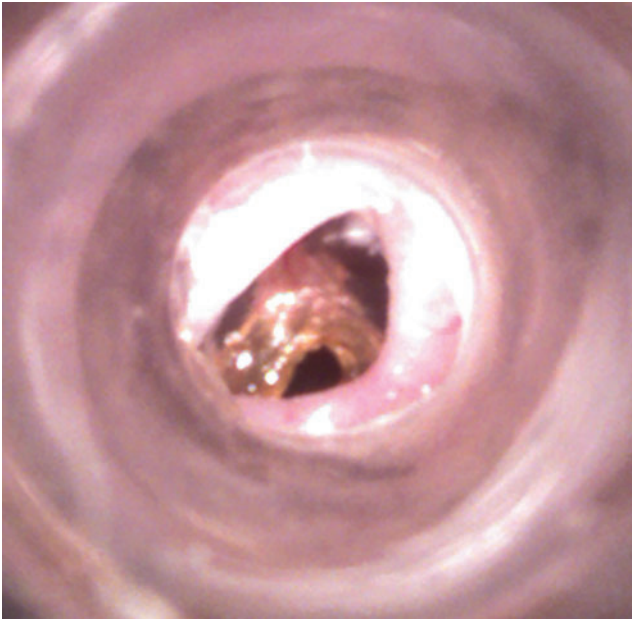


Supplementary Data



SUPPLEMENTARY FIG. S1. A chronic tympanic membrane (TM) perforation created with KB-R7785. Figure demonstrates the otoscopic appearance of a chronic perforation created using KB R7785 at 3 months in a mouse. The perforation can be seen inferiorly in the TM by a ring of debris, which is loosely attached to the perforation margin. Part of the remaining TM has healed and is semi translucent. The handle of the malleus can also be seen attaching in the center of the TM.