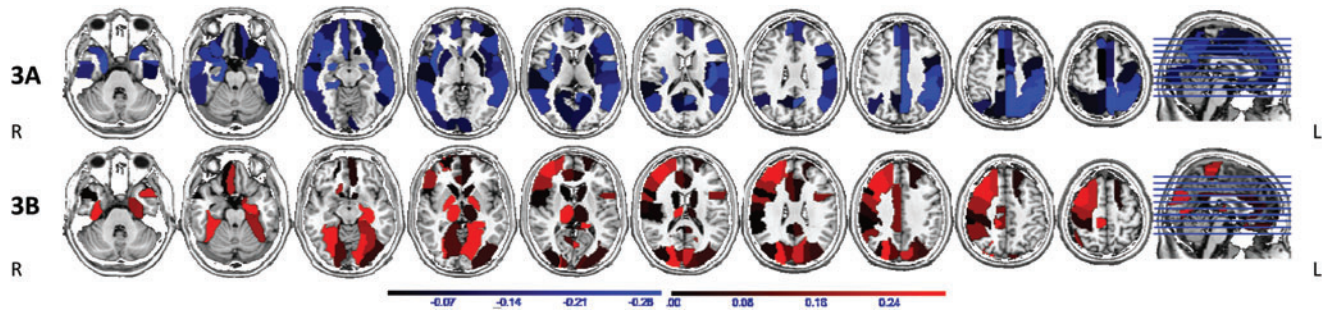


Supplementary Data



SUPPLEMENTARY FIG. S1. Areas of reduced (3A, blue) and increased (3B, red) betweenness centrality associated with duration of epilepsy. This did not have a pattern similar to the regions involved by use of CBZ/OXC (Fig. 2). Orientation is radiological.