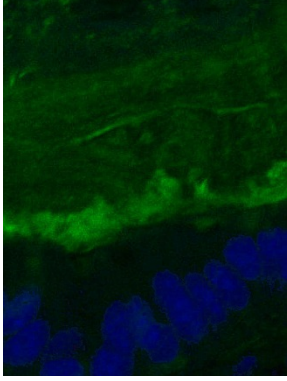
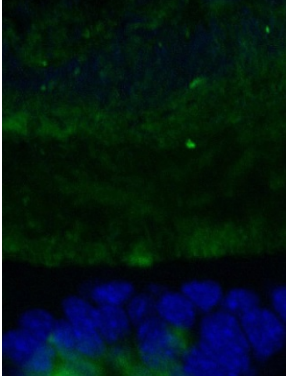
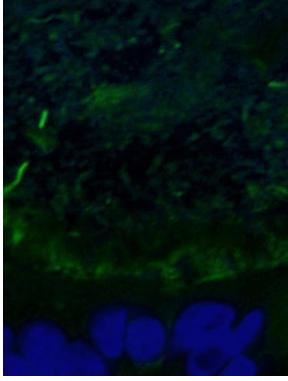
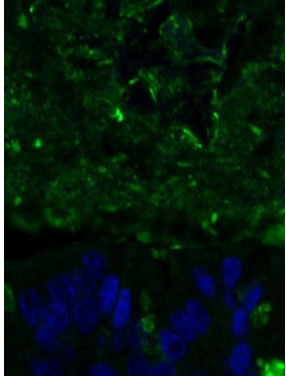


S3 Table. Scoring examples for the inner mucus layer

Mucus layering score			
Score 0	Score 1	Score 2	Score 3
			
Clearly visible layering with stratified structure of the inner mucus layer	Observable layering in the inner mucus layer but with less overall structure	Remains of layering in the inner mucus are visible	No structure at all in the mucus can be observed

Green: Muc2; blue: nuclei