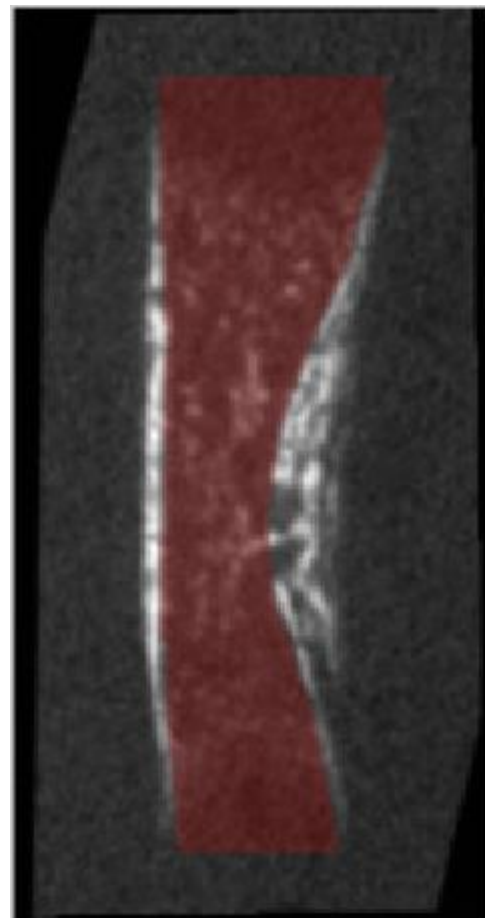
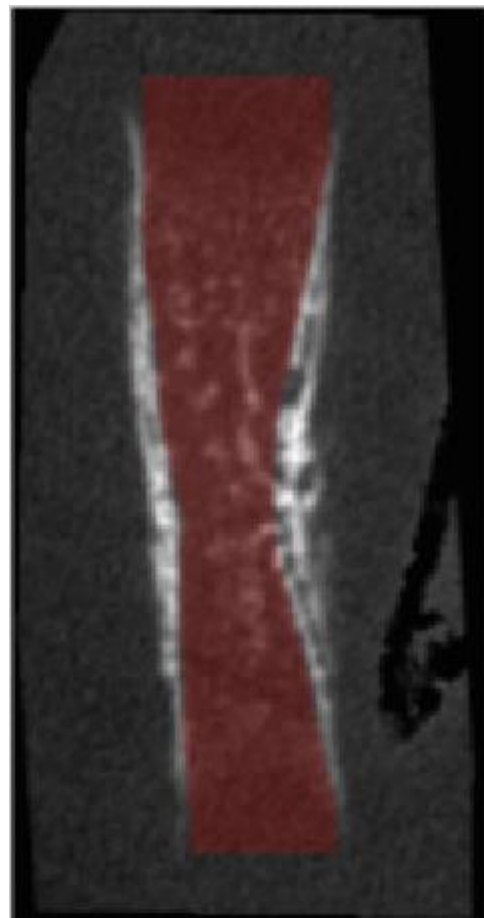


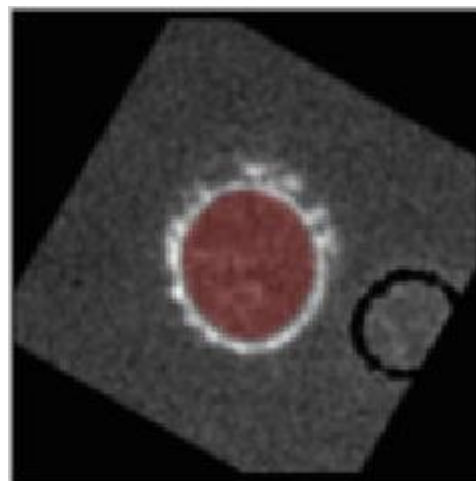
Longitudinal 1



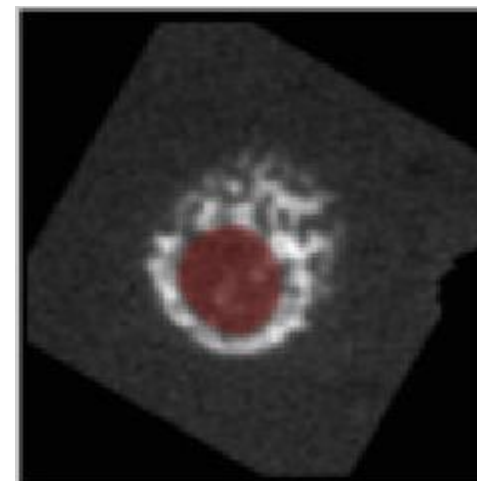
Longitudinal 2



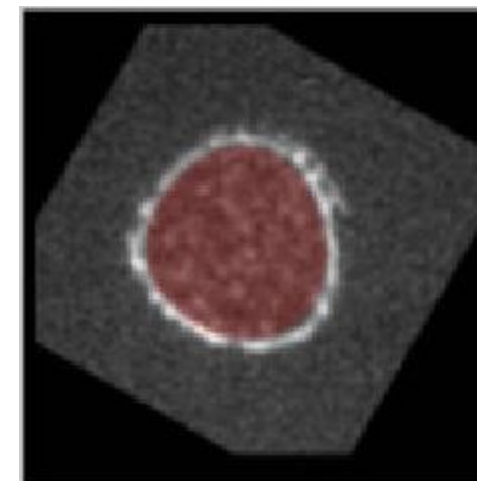
Transverse 1



Transverse 2

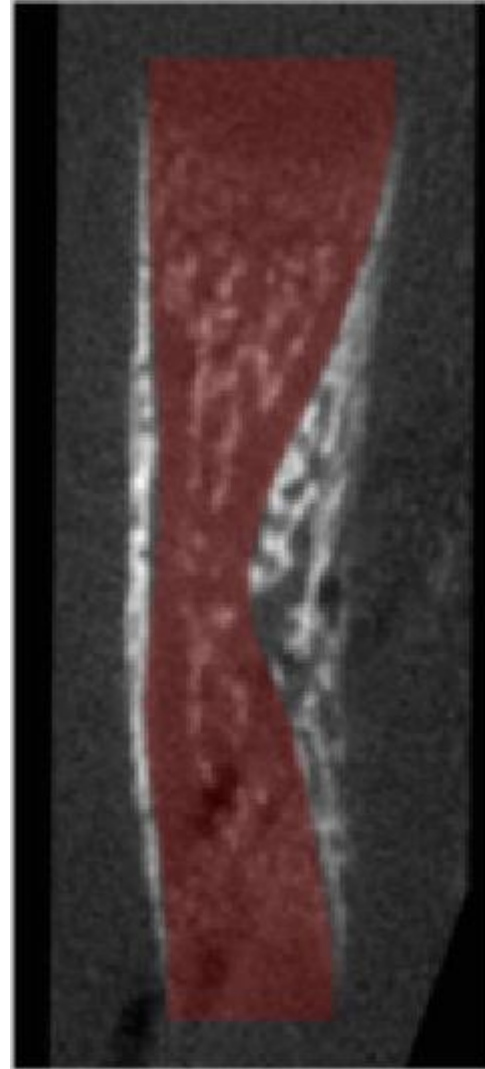


Transverse 3

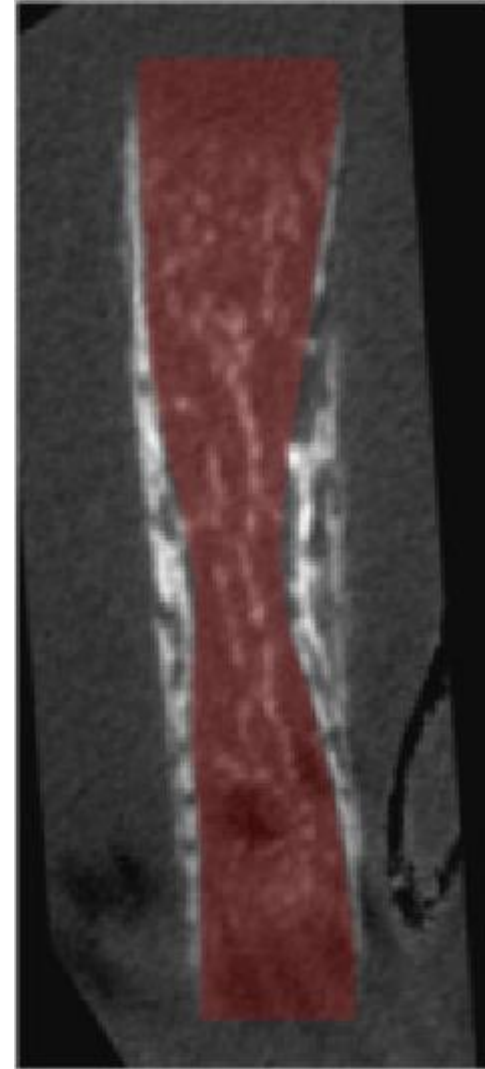

Tibia – E16  
Gray scale = Bone CT slide  
Semi-transparent red = Masked regions

Longitudinal 1



Longitudinal 2

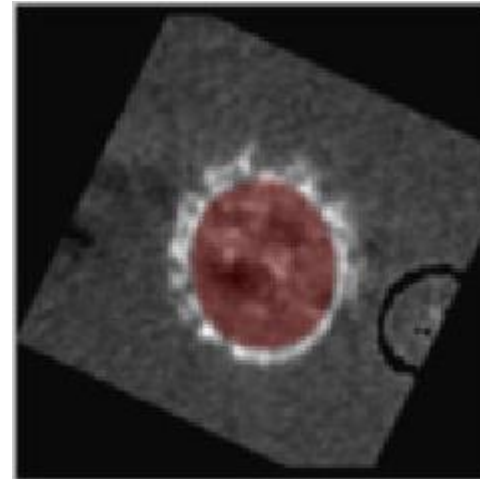


Tibia – E17

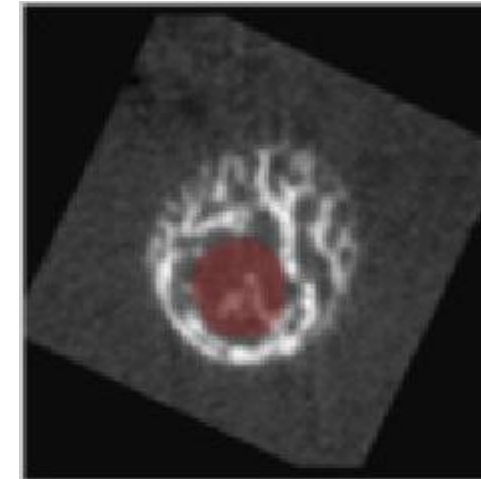
Gray scale = Bone CT slide

Semi-transparent red = Masked regions


Transverse 1



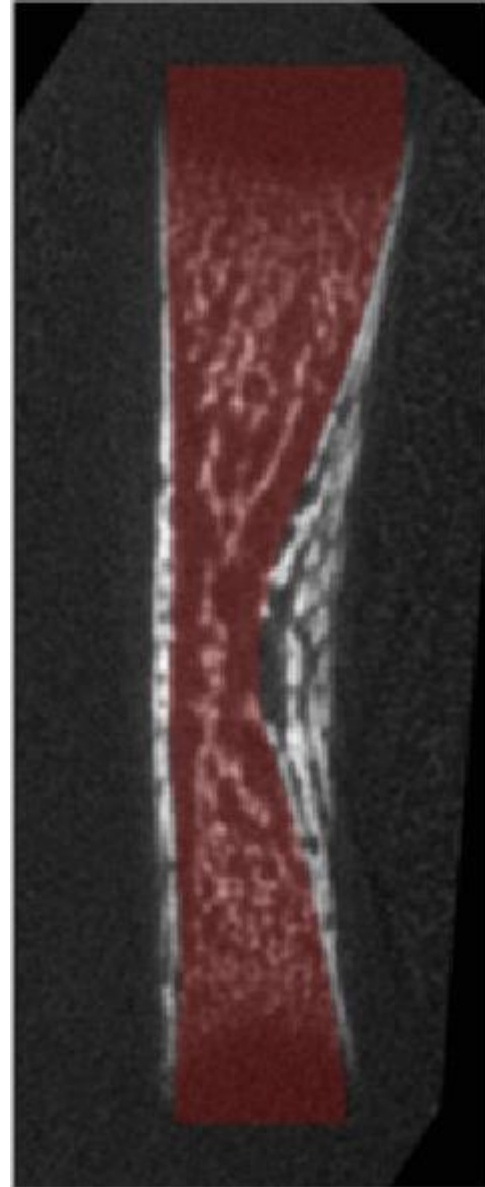
Transverse 2



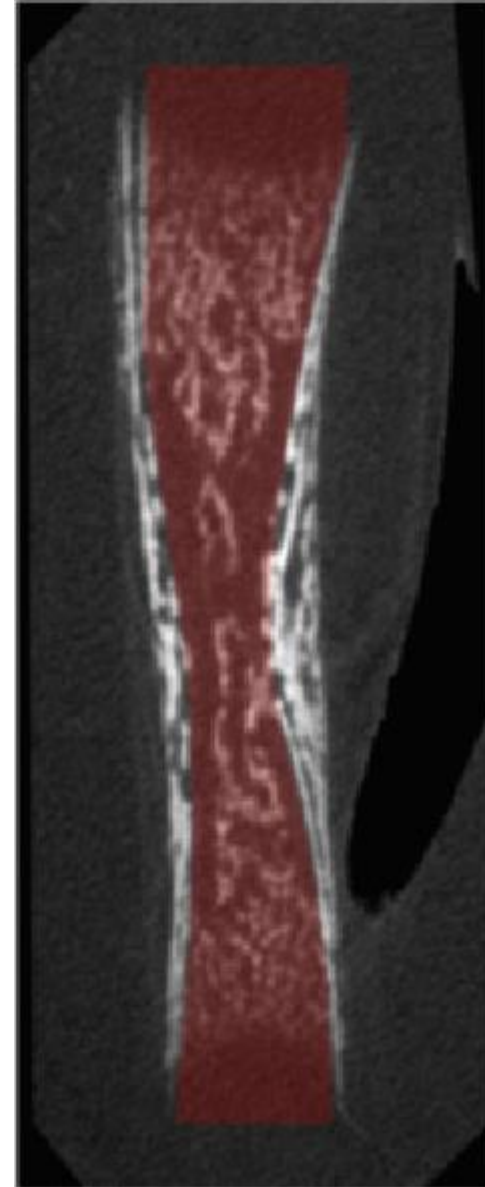Transverse 3




Longitudinal 1



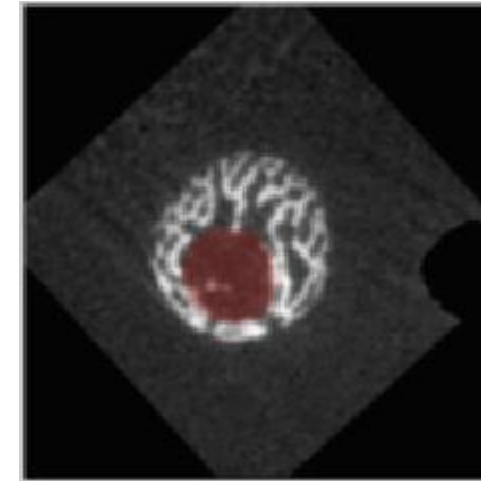
Longitudinal 2




Transverse 1



Transverse 2

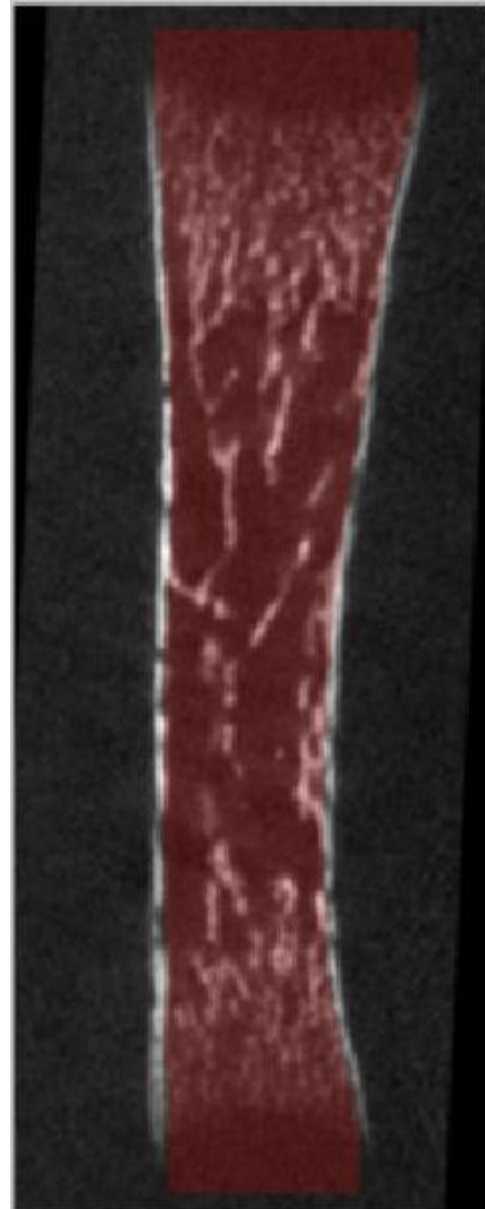


Transverse 3

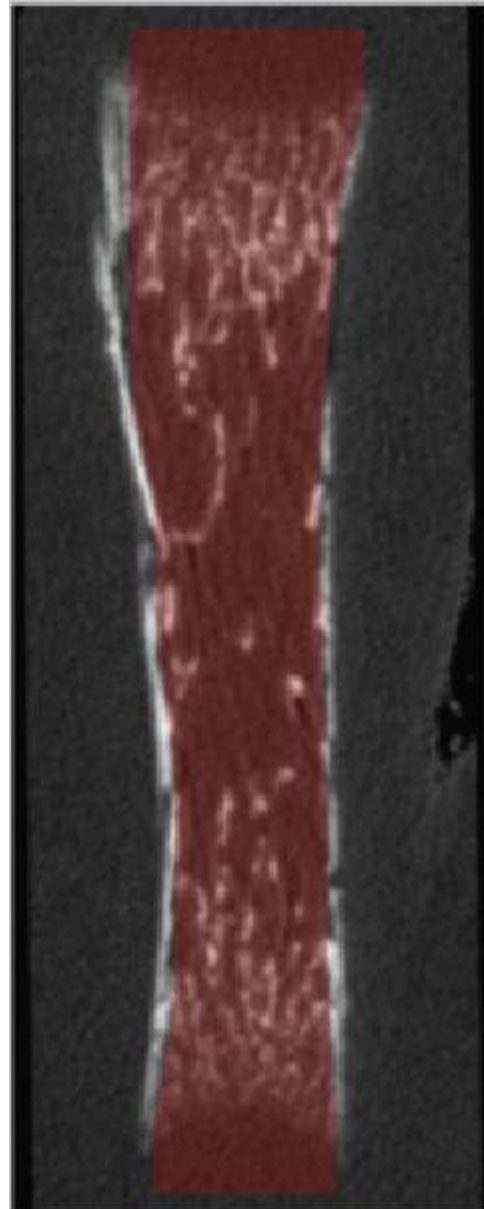


Tibia - E18  
Gray scale = Bone CT slide  
Semi-transparent red = Masked regions

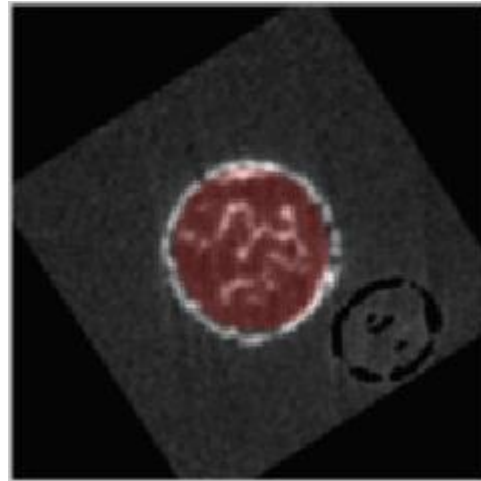
Longitudinal 1



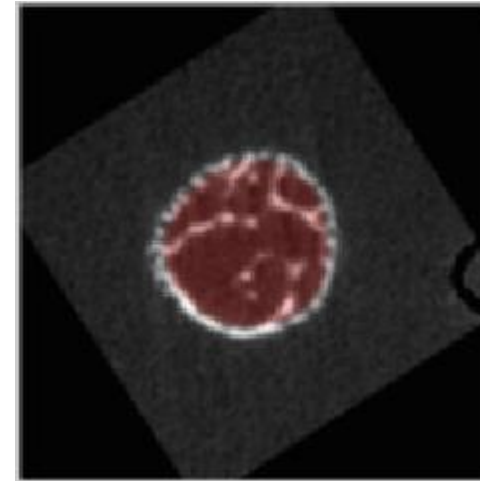
Longitudinal 2




Transverse 1



Transverse 2




Transverse 3

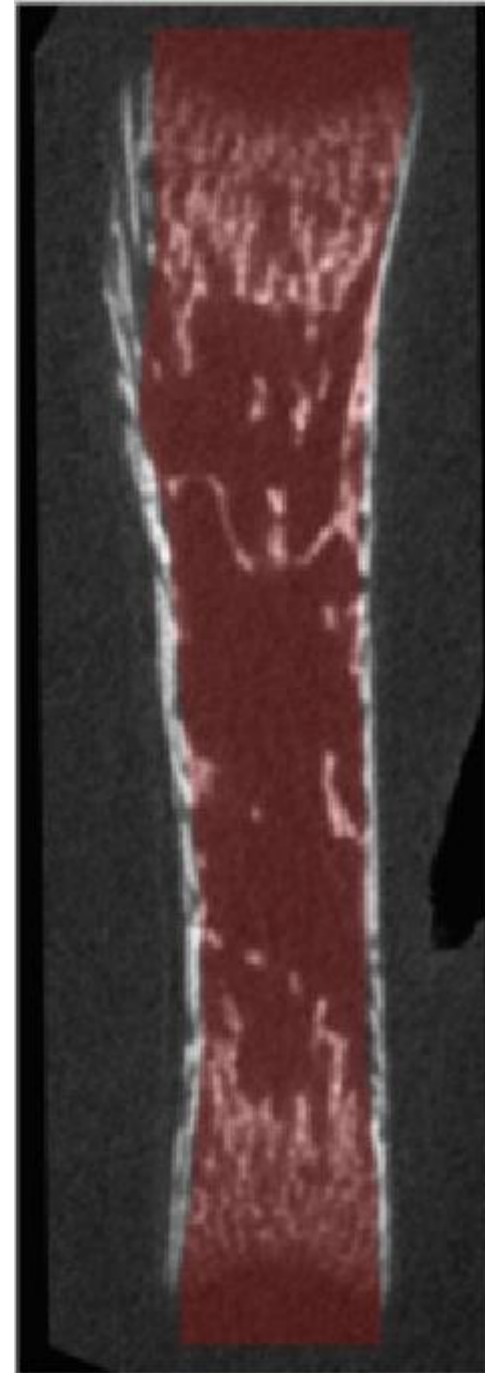


Tibia - P1  
Gray scale = Bone CT slide  
Semi-transparent red = Masked regions

Longitudinal 1



Longitudinal 2

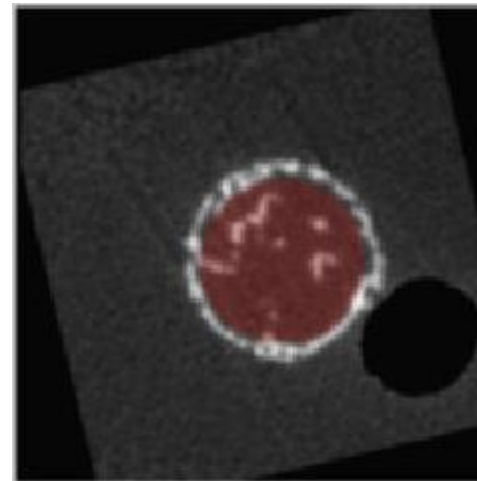


Tibia – P2

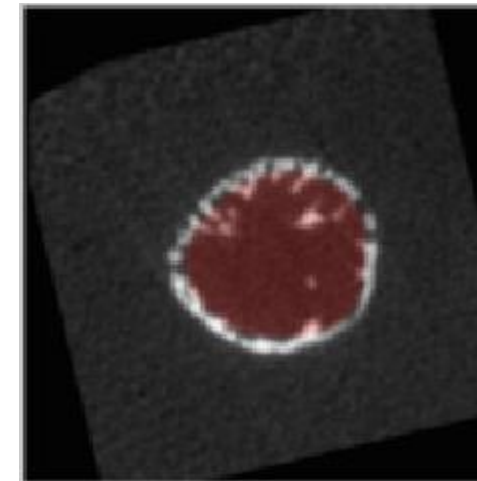
Gray scale = Bone CT slide

Semi-transparent red = Masked regions

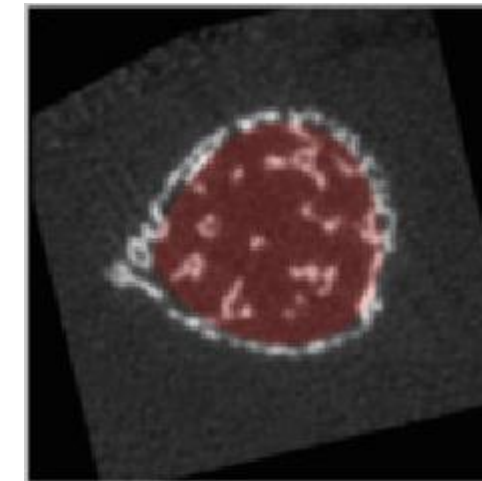
Transverse 1



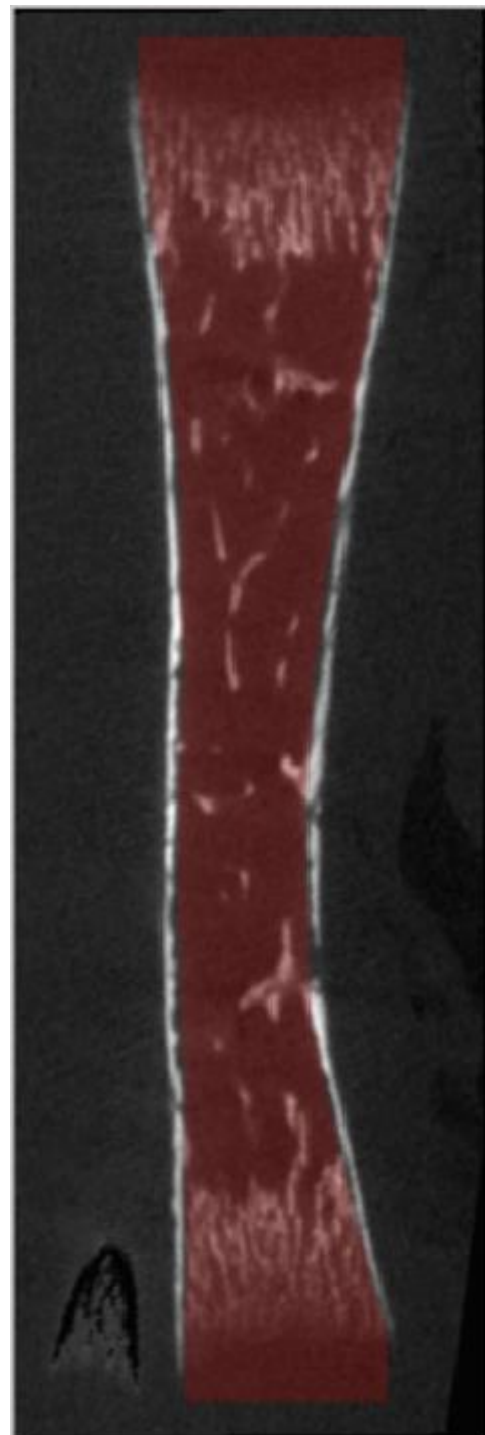
Transverse 2



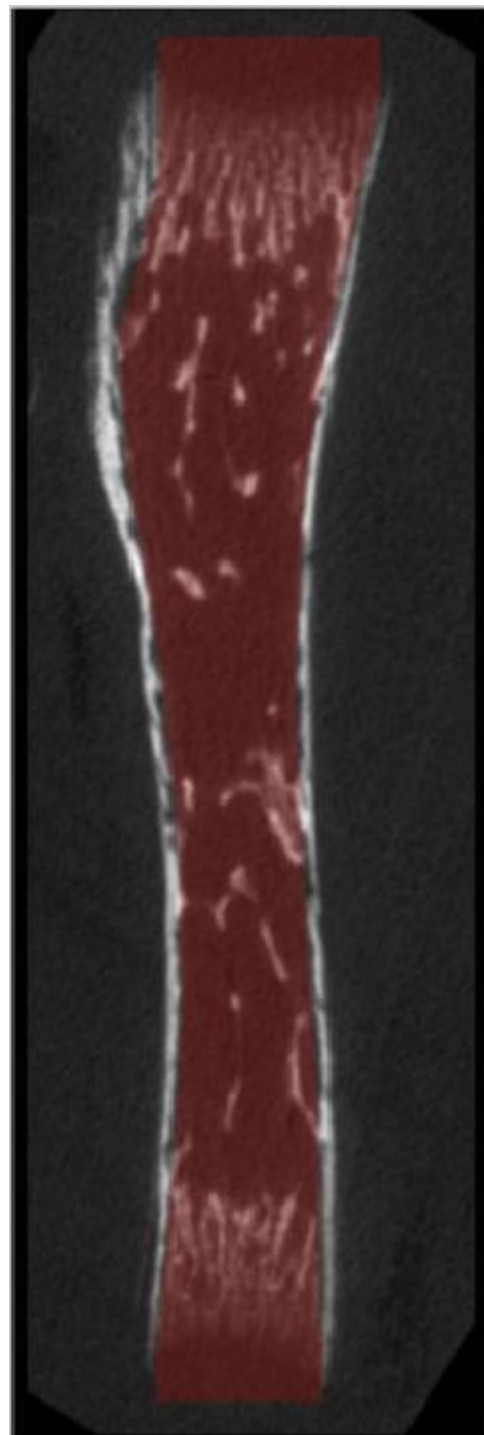
Transverse 3



Longitudinal 1



Longitudinal 2

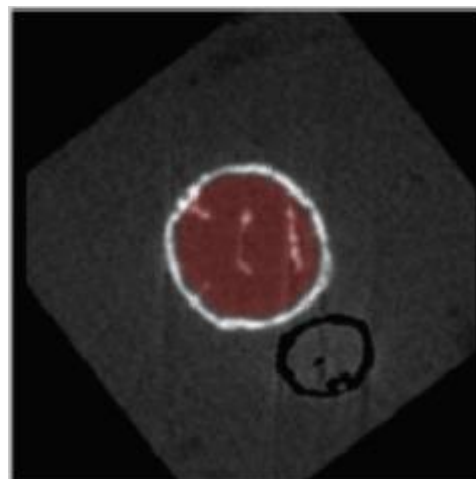


Tibia - P4

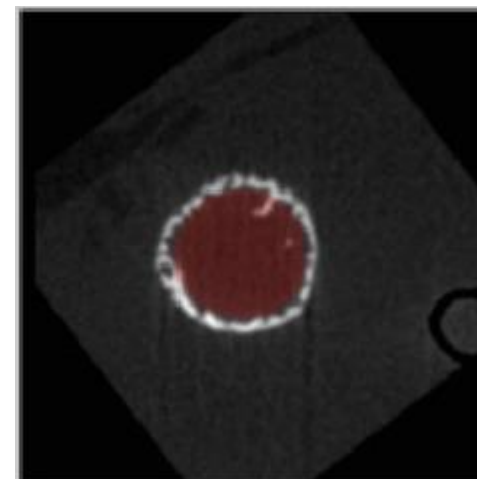
Gray scale = Bone CT slide

Semi-transparent red = Masked regions

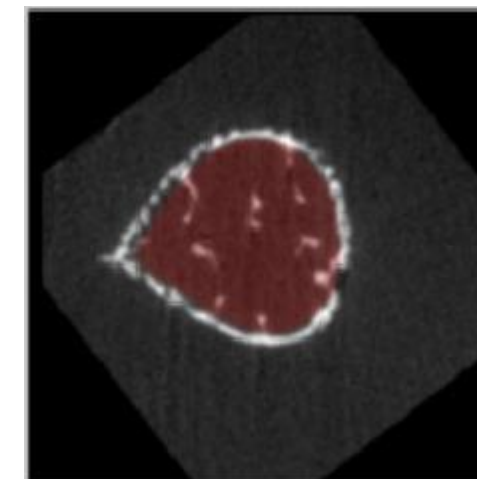
Transverse 1



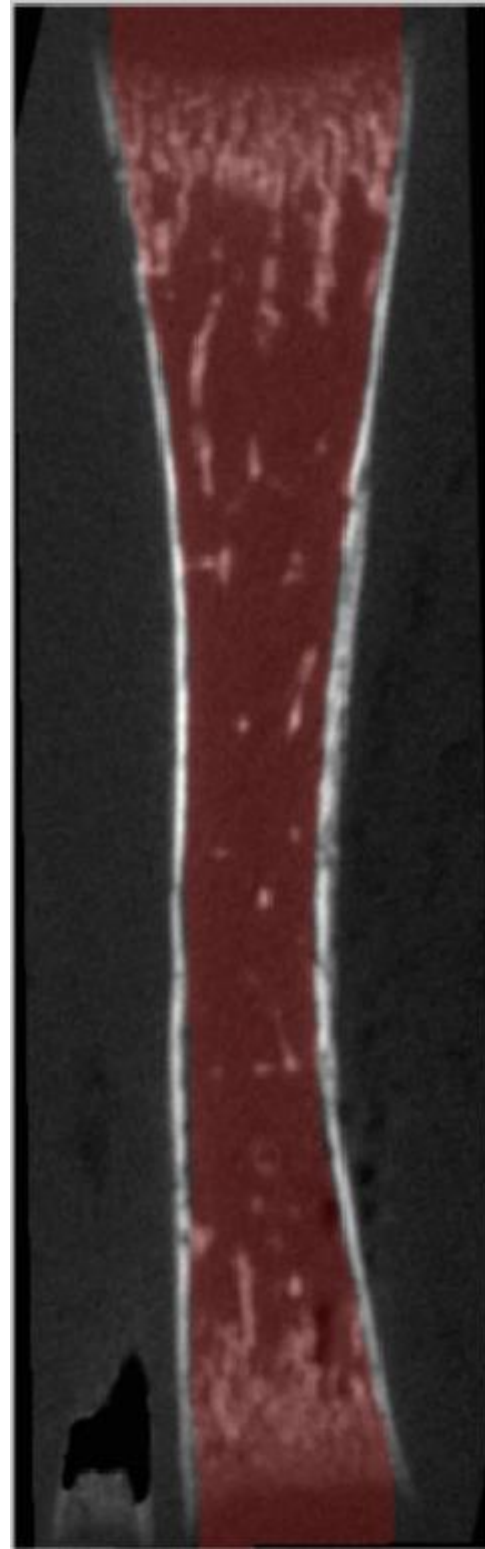
Transverse 2



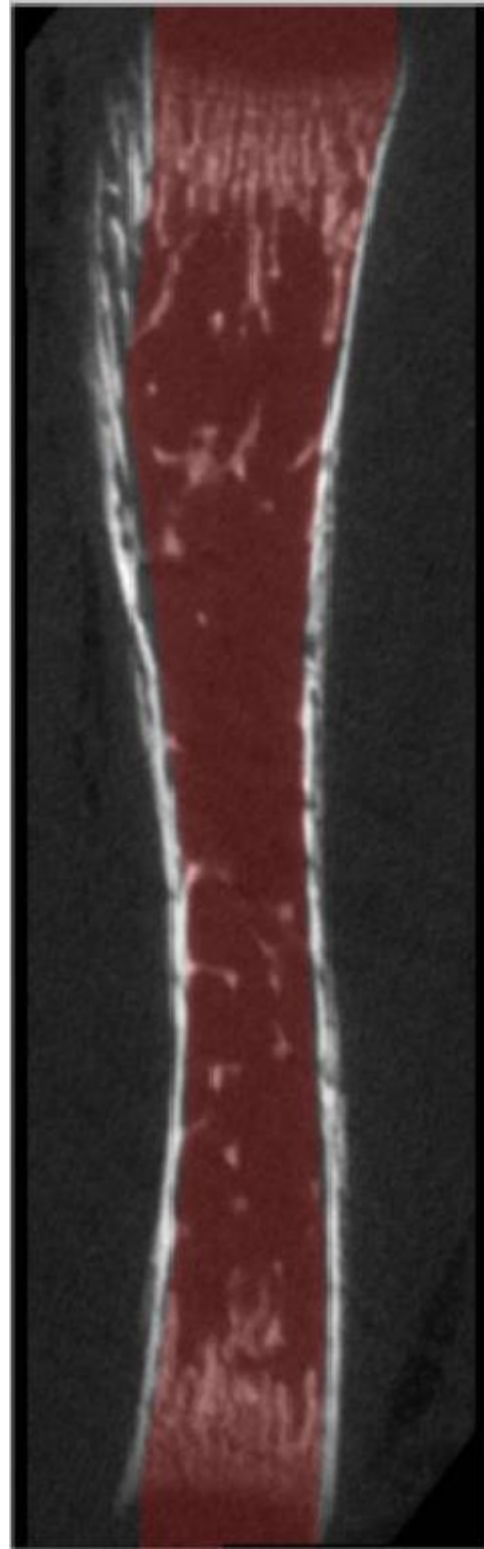
Transverse 3



Longitudinal 1



Longitudinal 2

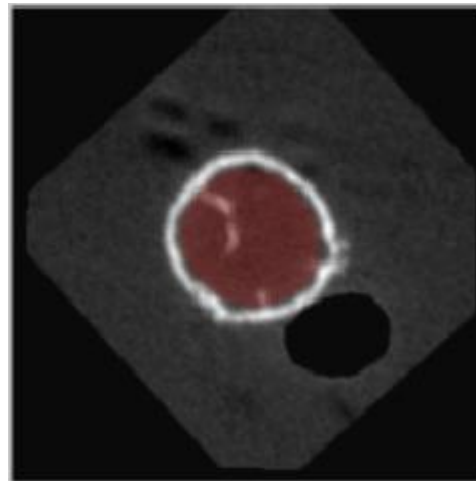


Tibia – P6

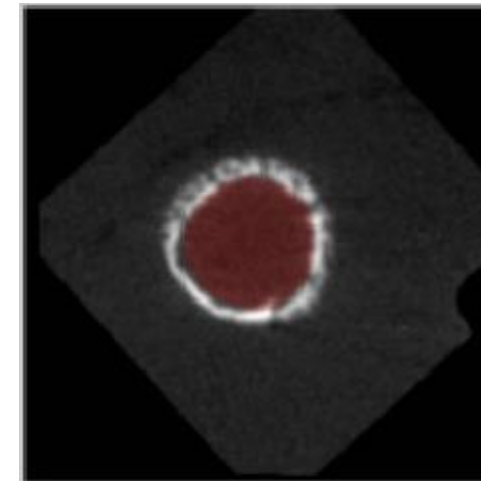
Gray scale = Bone CT slide

Semi-transparent red = Masked regions

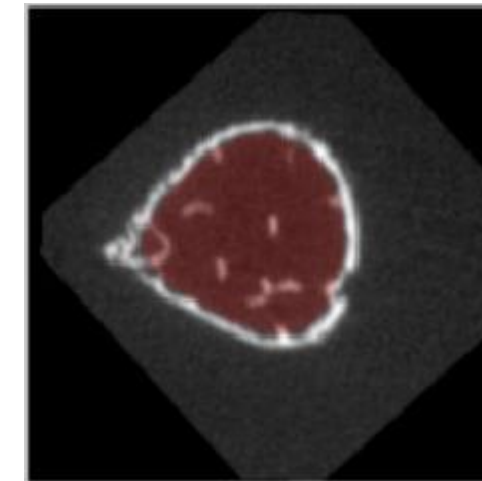
Transverse 1



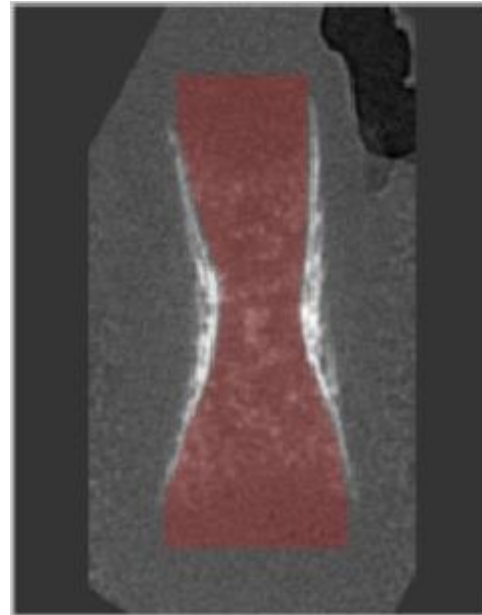
Transverse 2



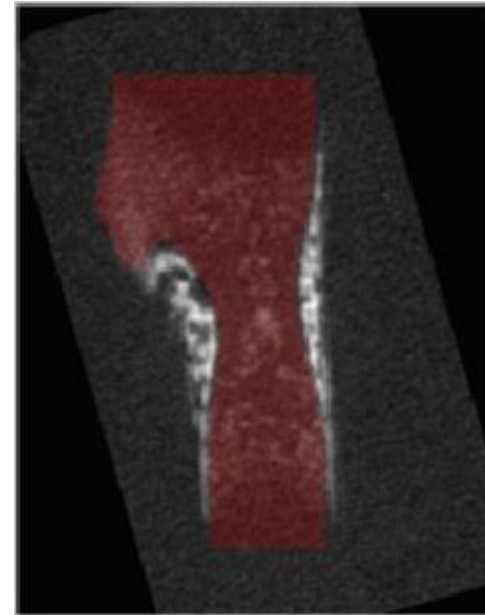
Transverse 3



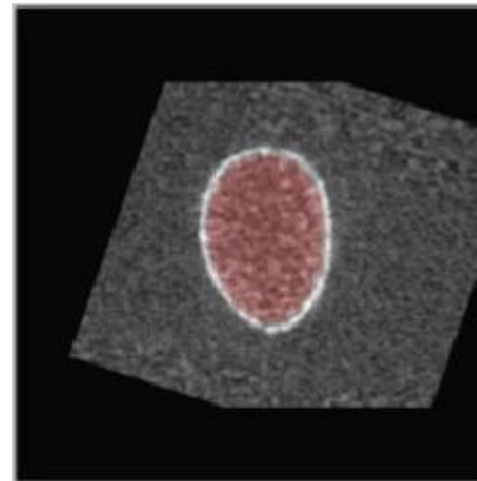
Longitudinal 1



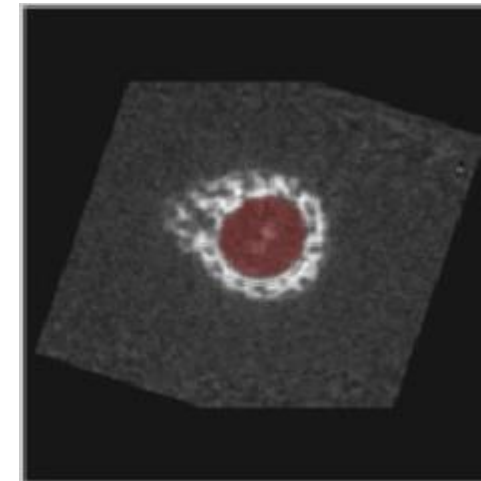
Longitudinal 2



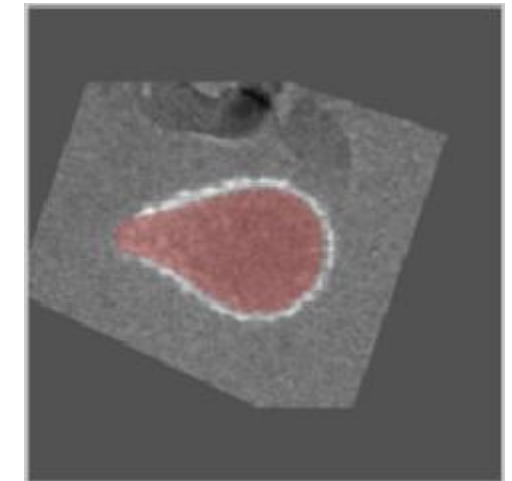
Transverse 1



Transverse 2



Transverse 3



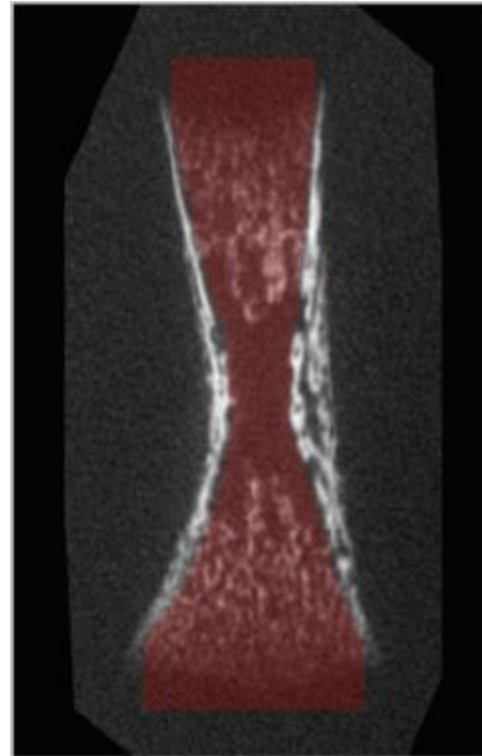
Humerus – E16

Gray scale = Bone CT slide

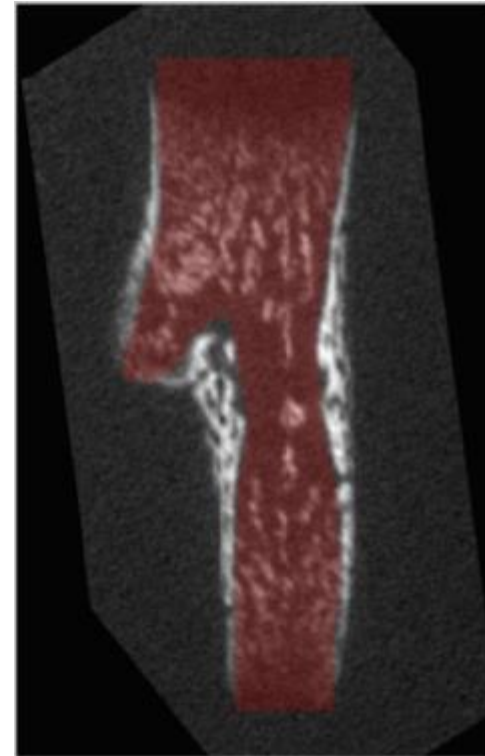
Semi-transparent red = Masked regions



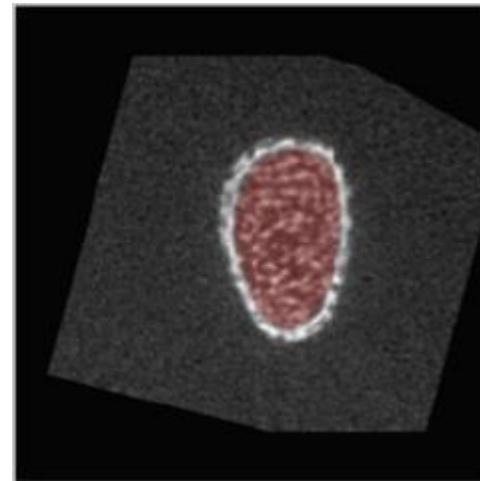
Longitudinal 1



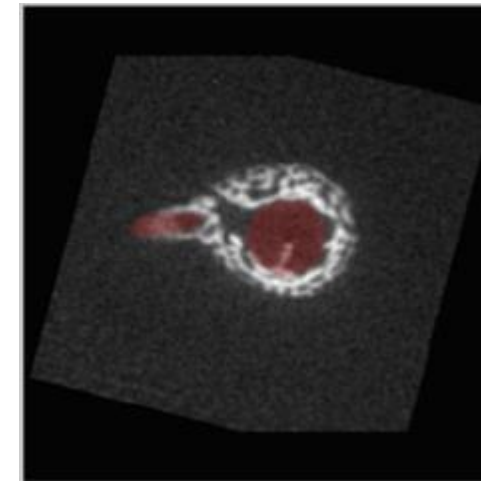
Longitudinal 2



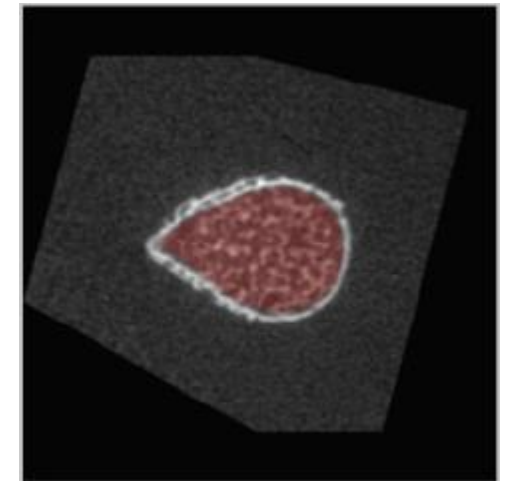
Transverse 1



Transverse 2



Transverse 3

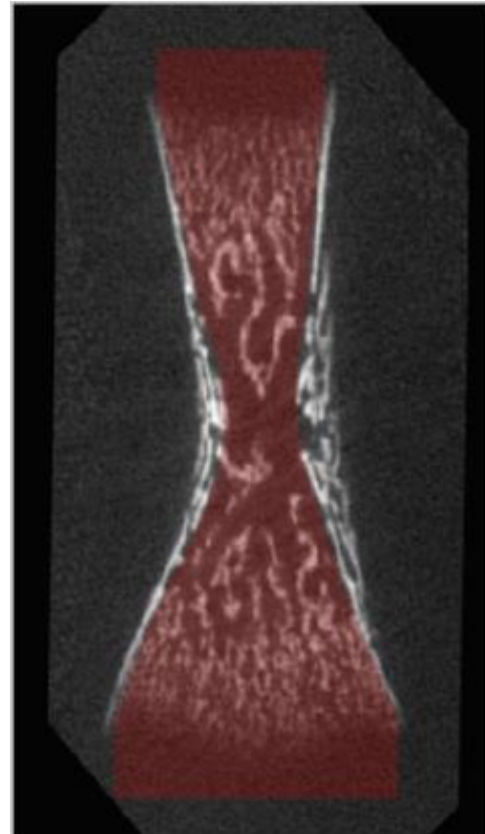


Humerus – E17

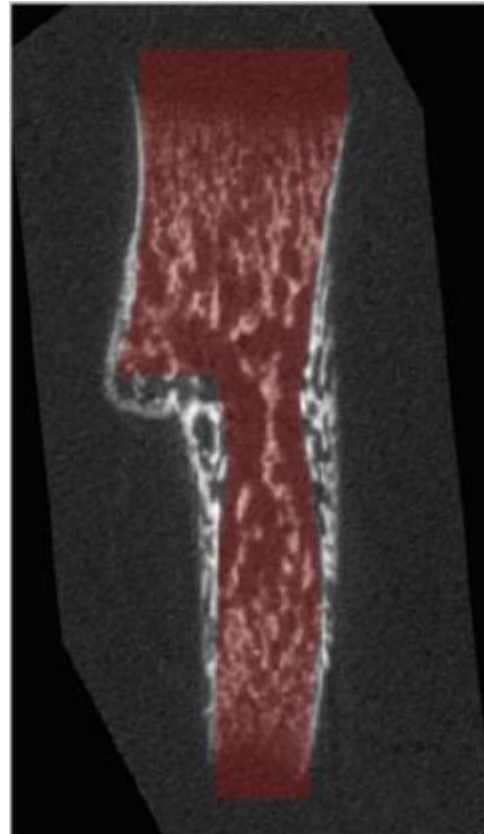
Gray scale = Bone CT slide

Semi-transparent red = Masked regions

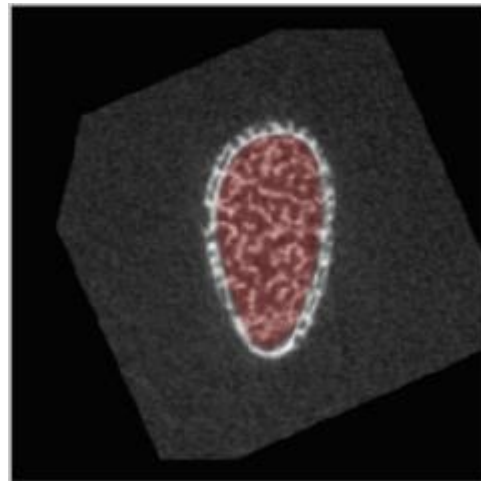
Longitudinal 1



Longitudinal 2



Transverse 1

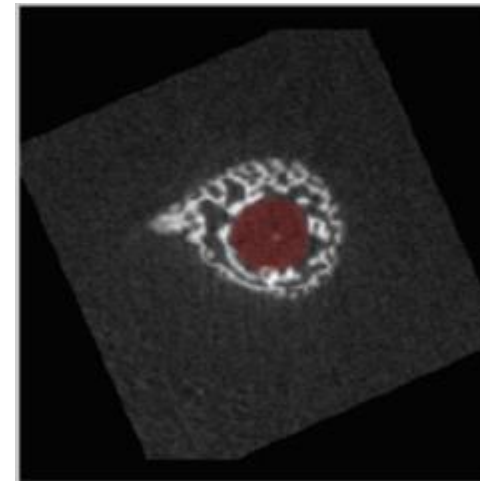


Humerus – E18

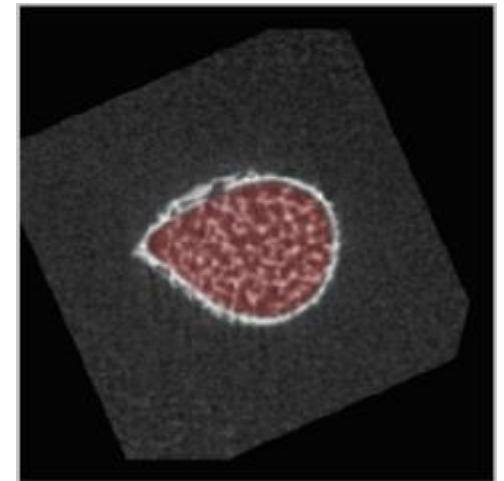
Gray scale = Bone CT slide

Semi-transparent red = Masked regions

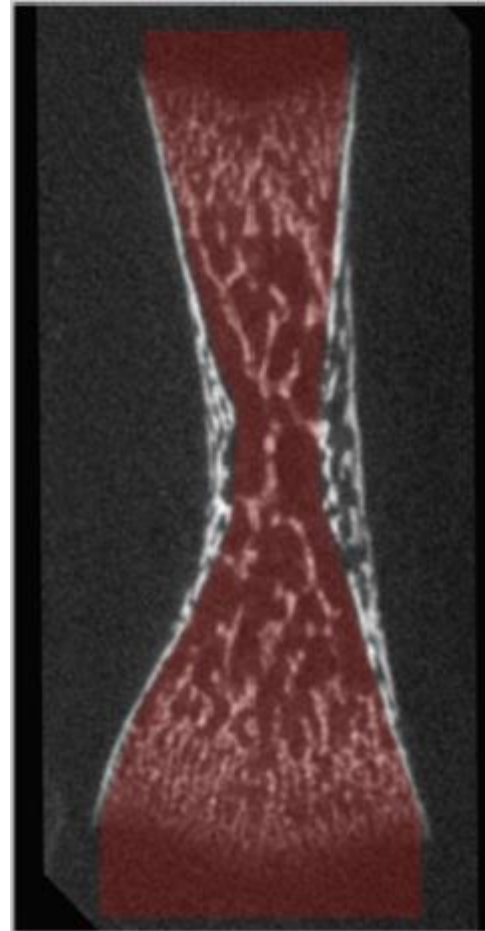
Transverse 2



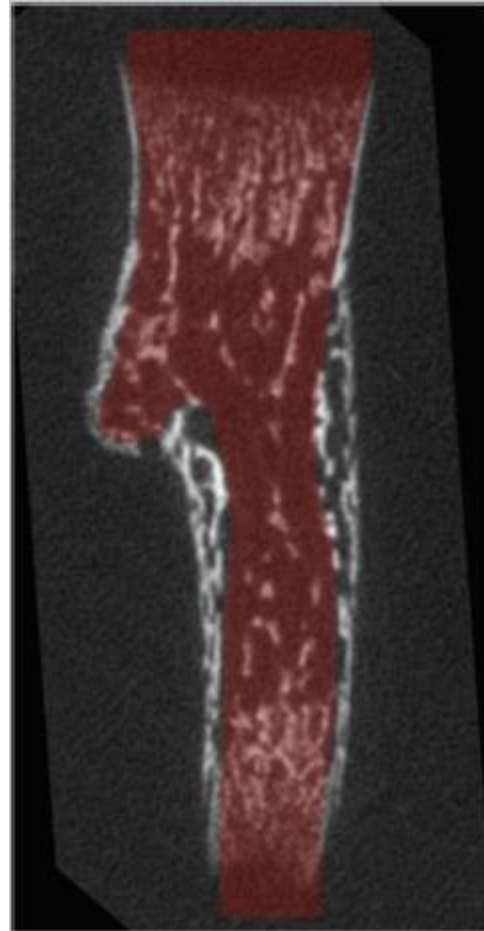
Transverse 3



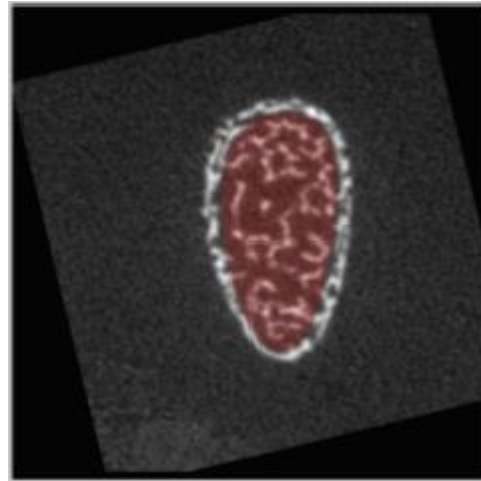
Longitudinal 1



Longitudinal 2



Transverse 1

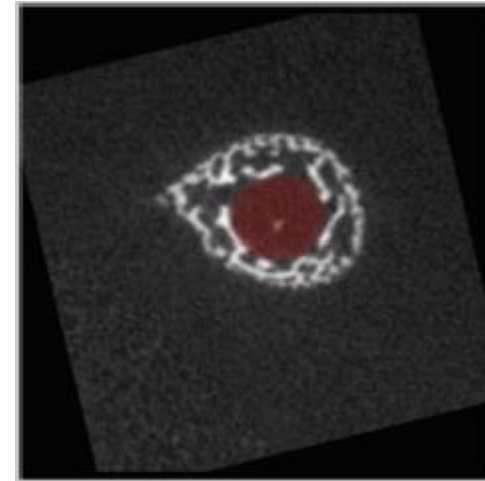


Humerus – P1

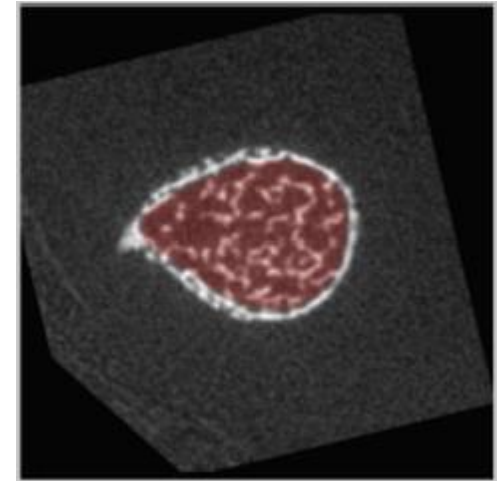
Gray scale = Bone CT slide

Semi-transparent red = Masked regions

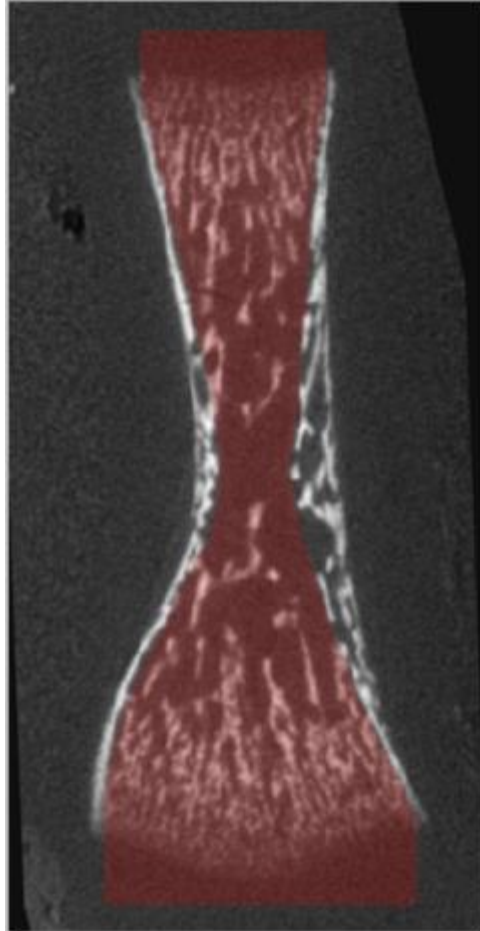
Transverse 2



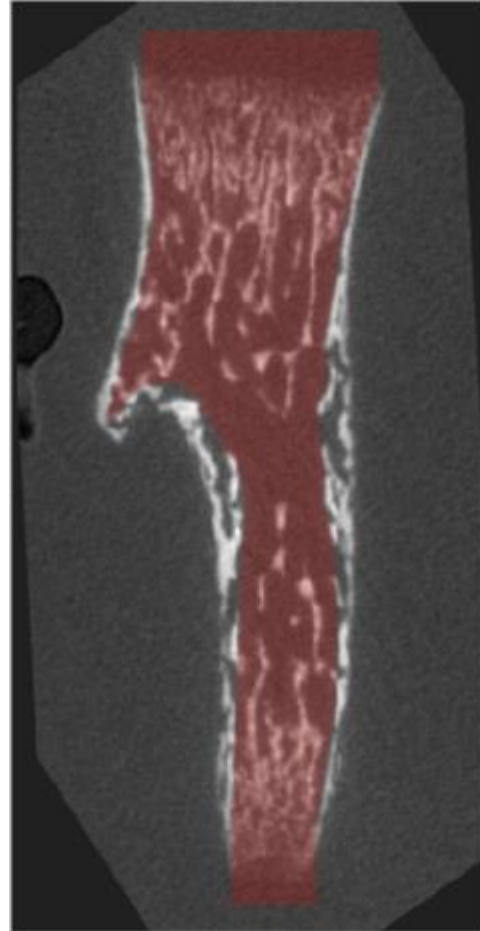
Transverse 3



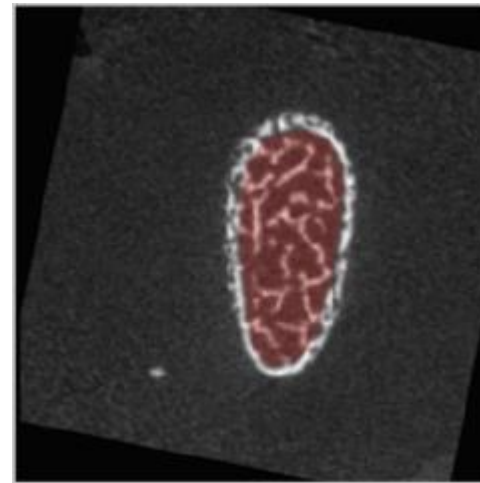
Longitudinal 1



Longitudinal 2



Transverse 1

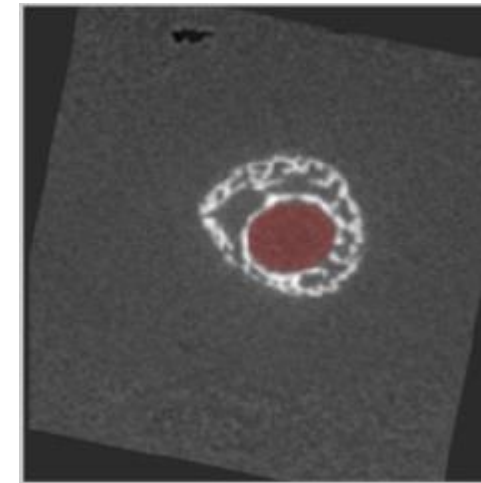


Humerus – P2

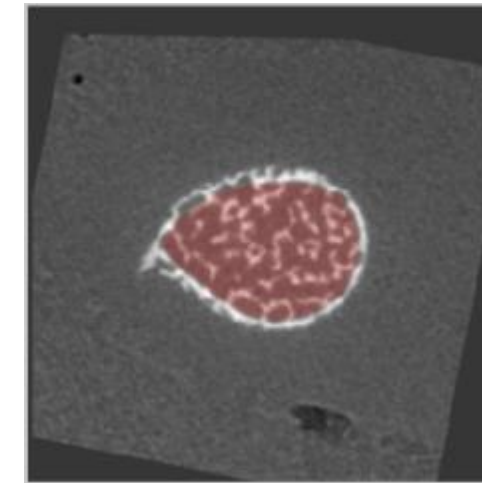
Gray scale = Bone CT slide

Semi-transparent red = Masked regions

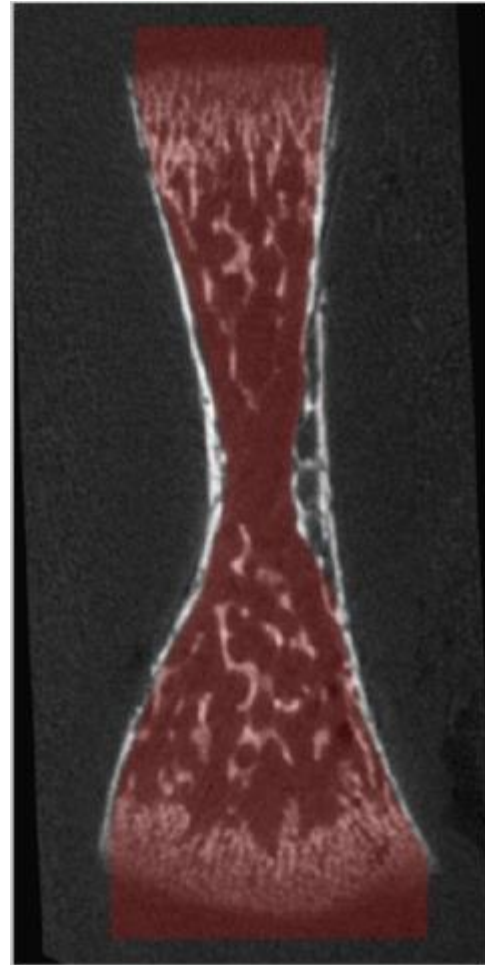
Transverse 2



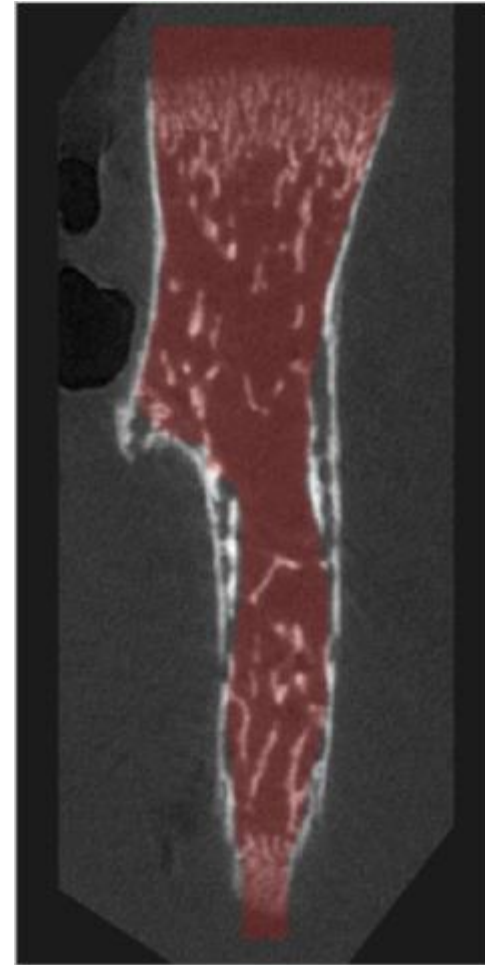
Transverse 3



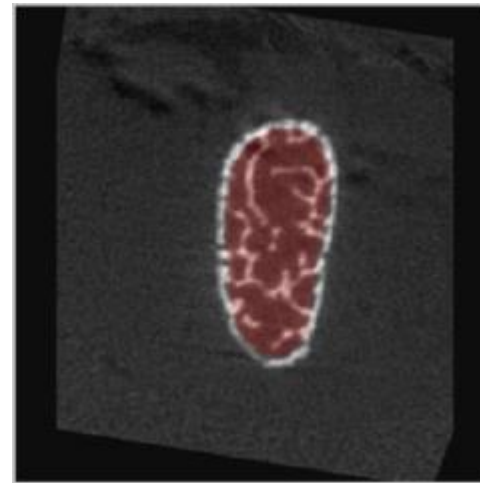
Longitudinal 1



Longitudinal 2



Transverse 1

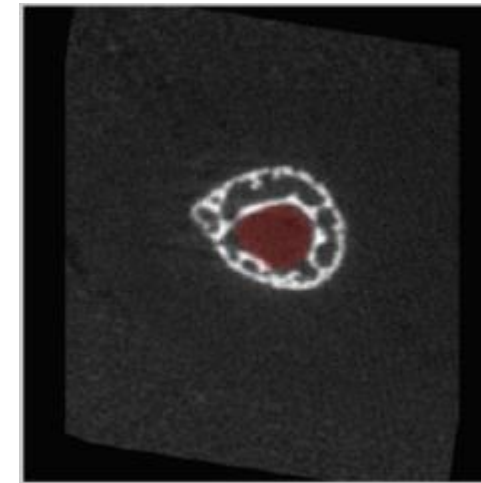


Humerus – P4

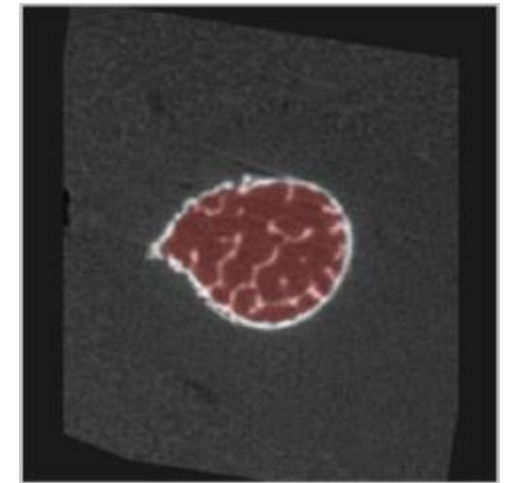
Gray scale = Bone CT slide

Semi-transparent red = Masked regions

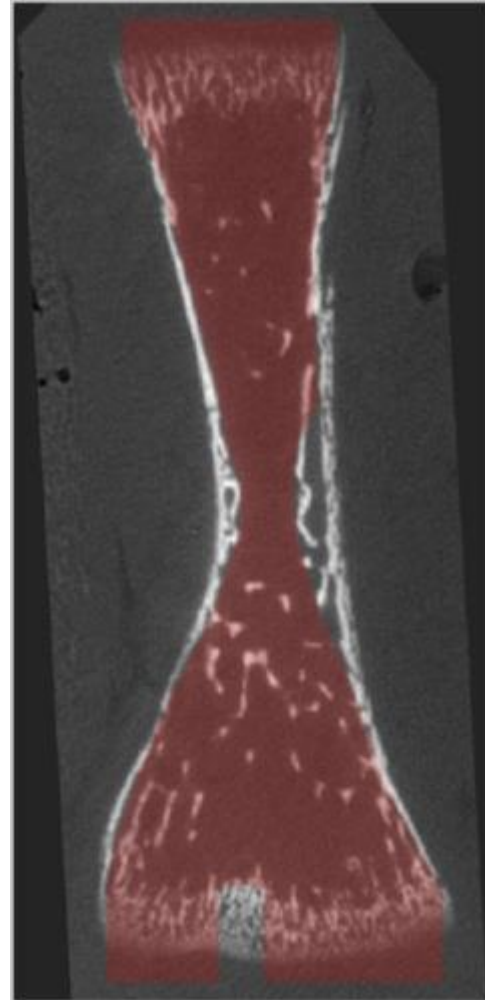
Transverse 2



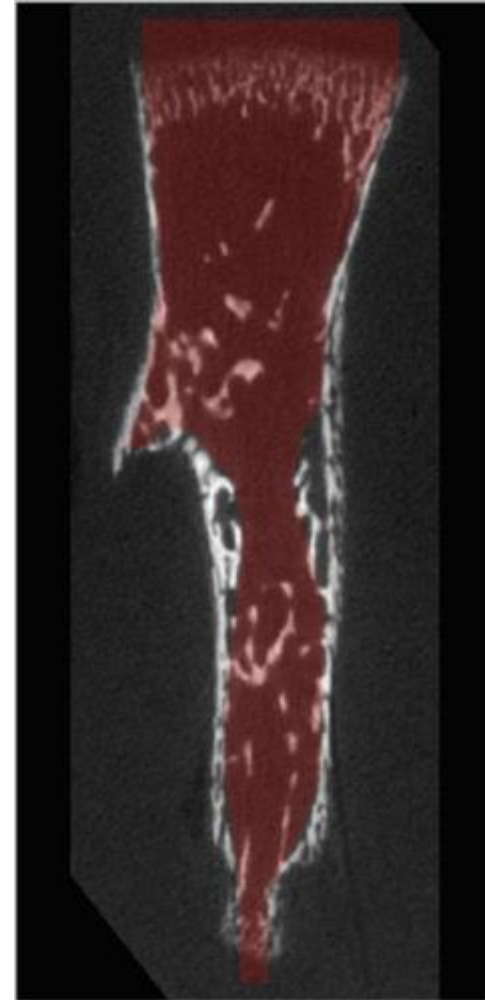
Transverse 3



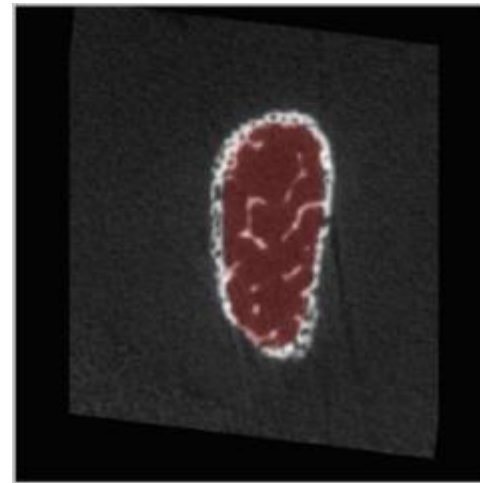
Longitudinal 1



Longitudinal 2

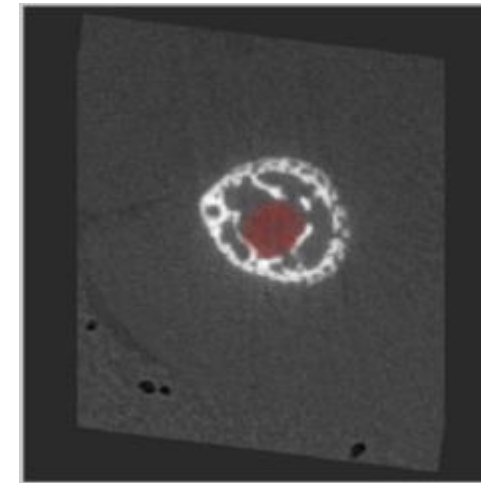


Transverse 1

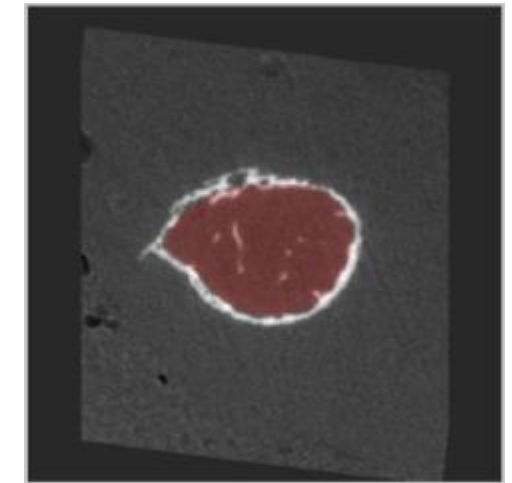


Humerus – P6  
Gray scale = Bone CT slide  
Semi-transparent red = Masked regions

Transverse 2



Transverse 3

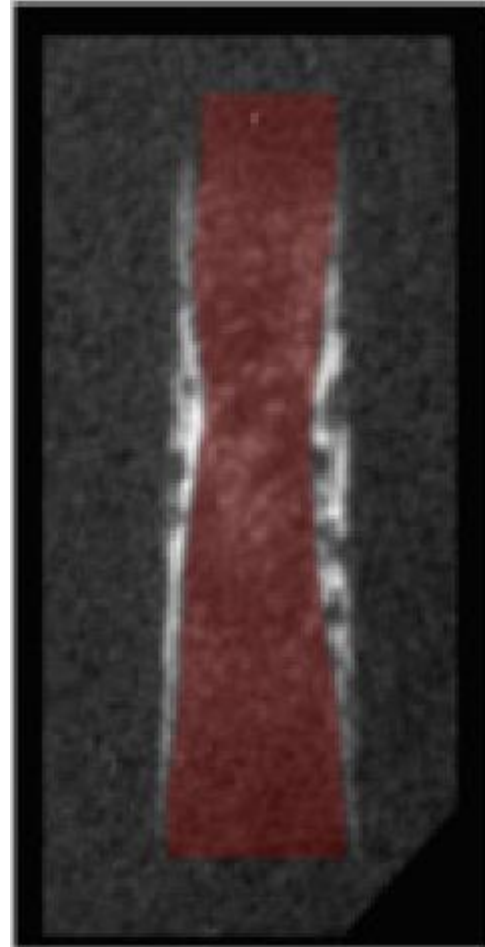


Radius – E16

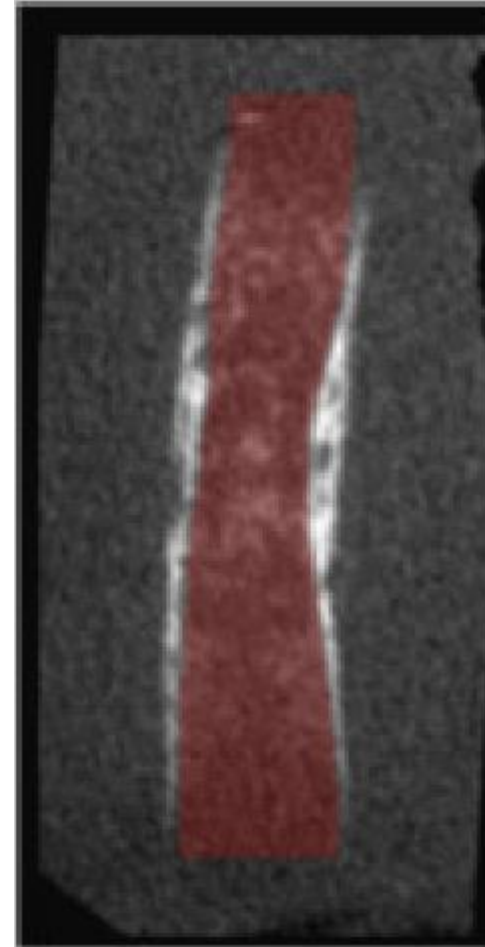
Gray scale = Bone CT slide

Semi-transparent red = Masked regions

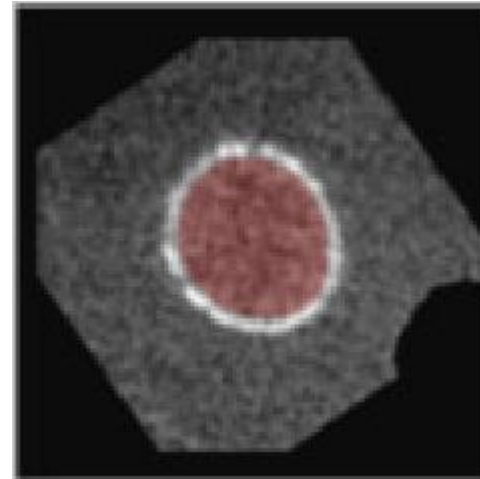
Longitudinal 1



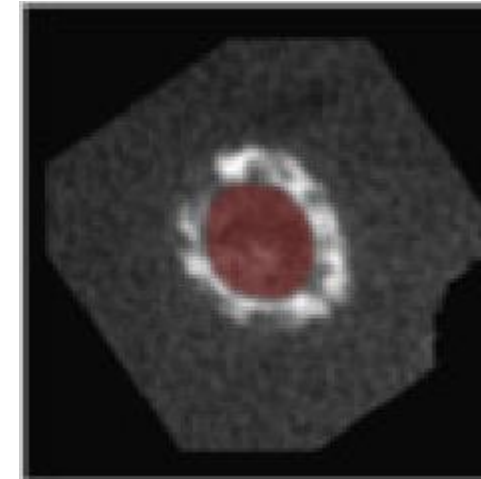
Longitudinal 2



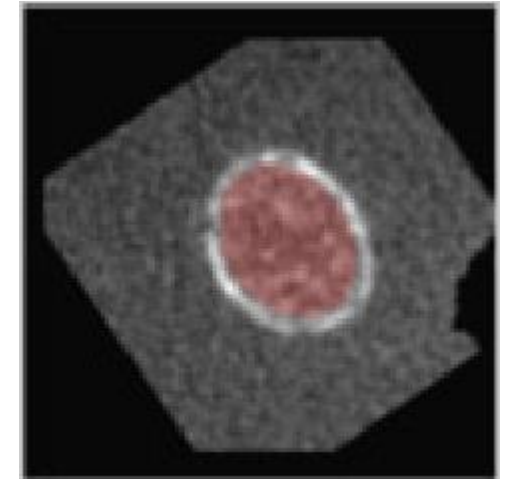
Transverse 1



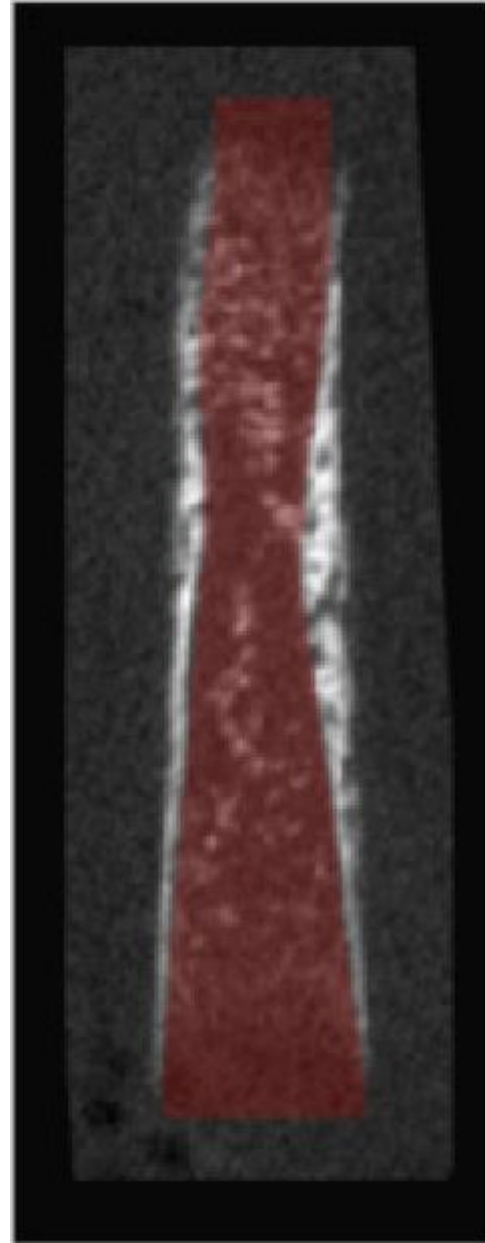
Transverse 2



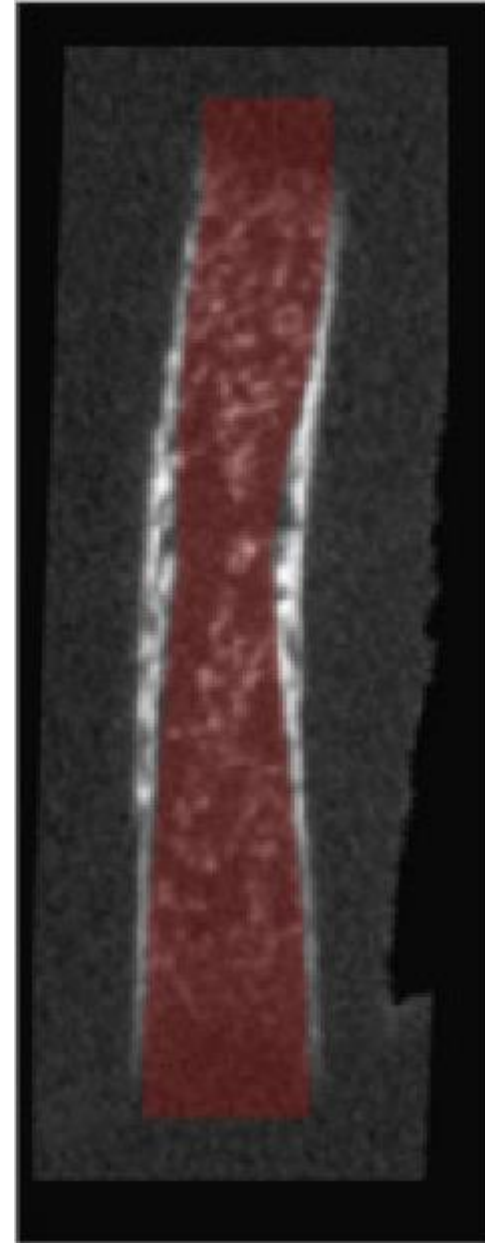
Transverse 3



Longitudinal 1



Longitudinal 2

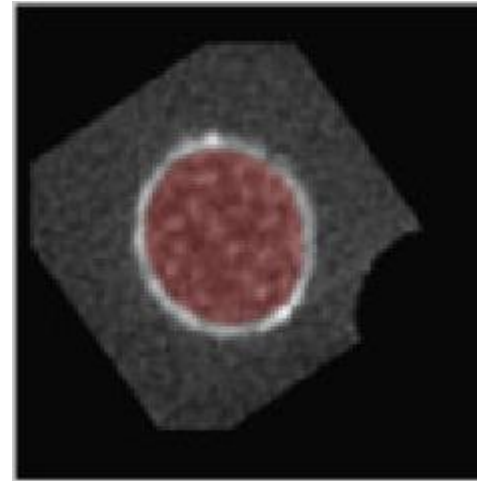


Radius – E17

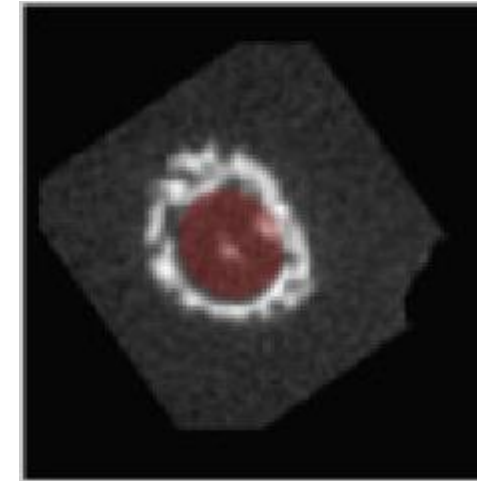
Gray scale = Bone CT slide

Semi-transparent red = Masked regions

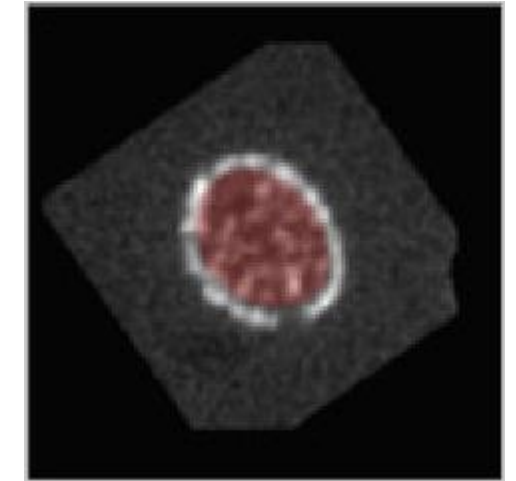
Transverse 1



Transverse 2

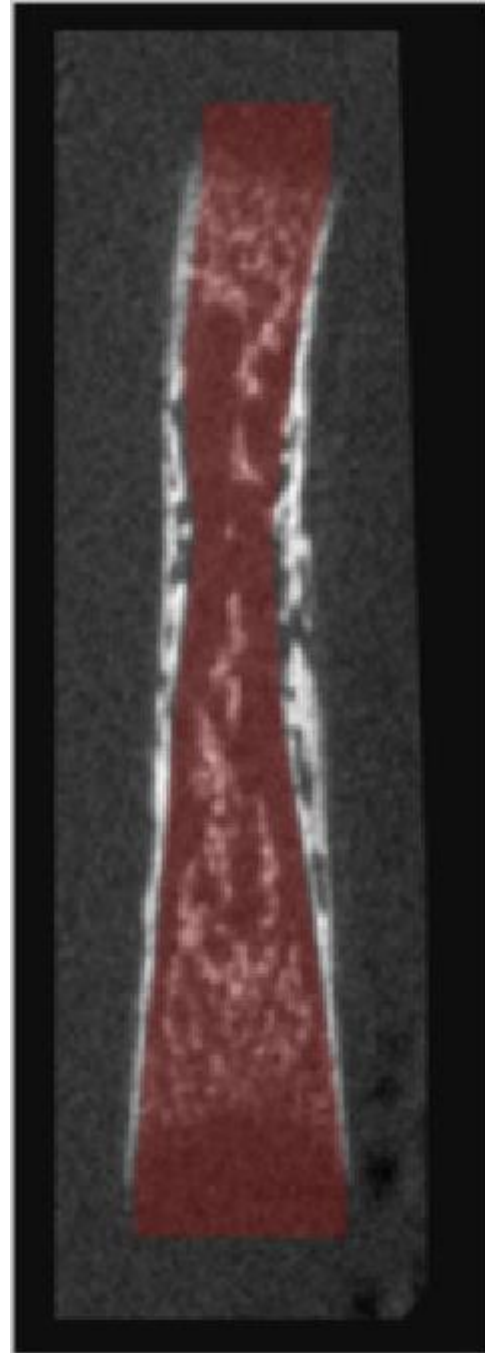


Transverse 3

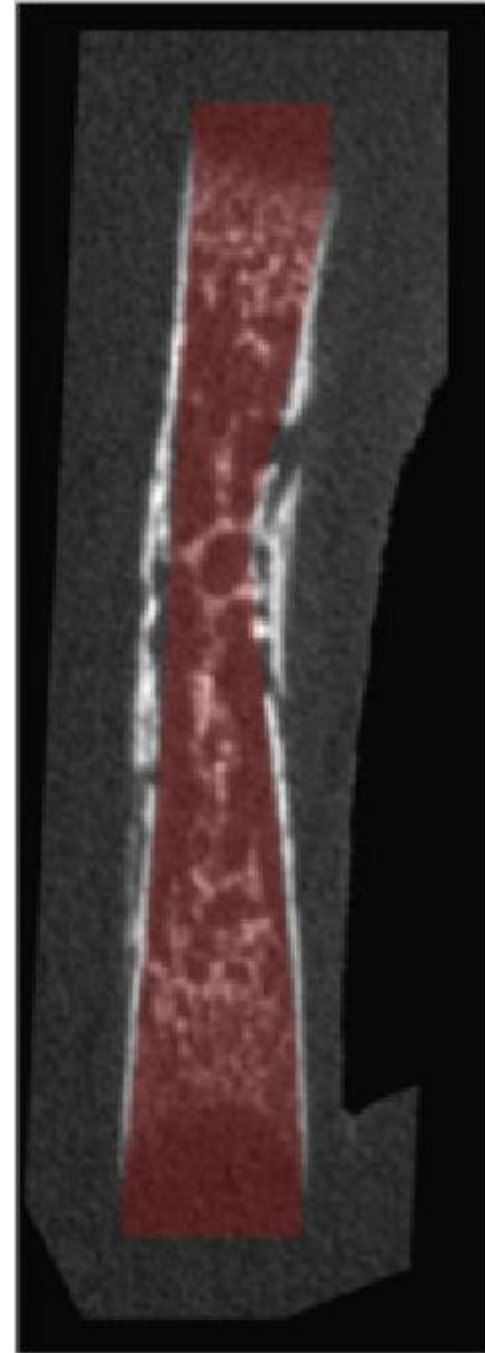




Longitudinal 1




Longitudinal 2

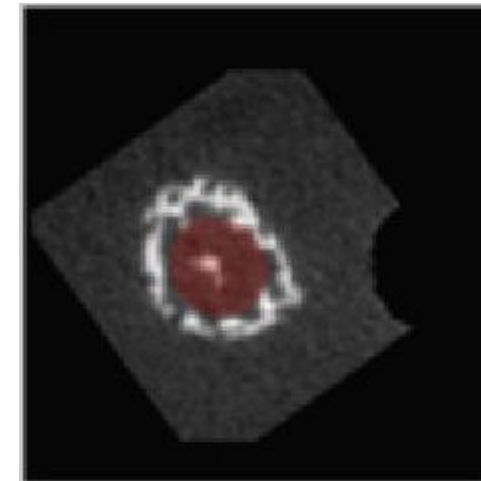


Radius – E18  
Gray scale = Bone CT slide  
Semi-transparent red = Masked regions


Transverse 1



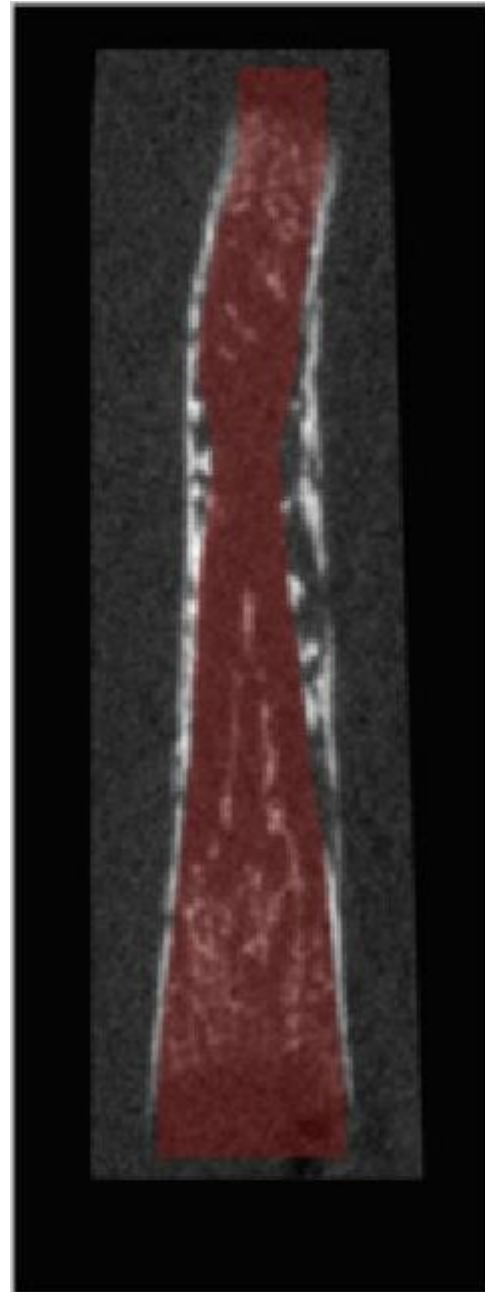
Transverse 2



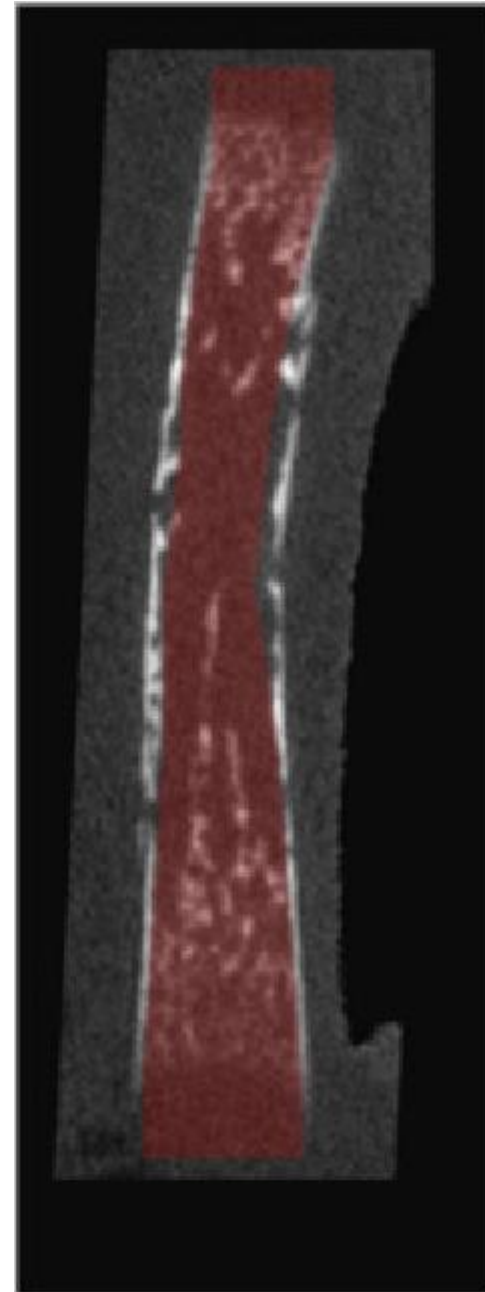
Transverse 3




Longitudinal 1



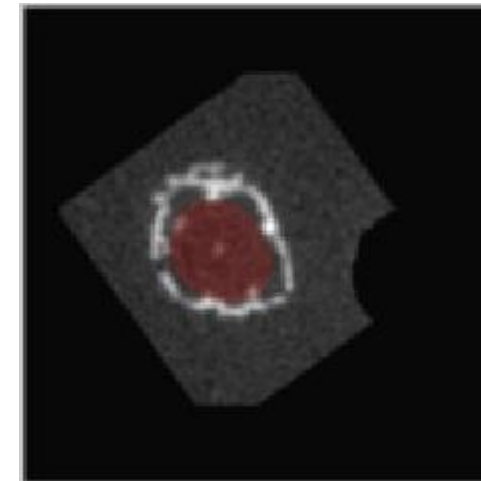
Longitudinal 2



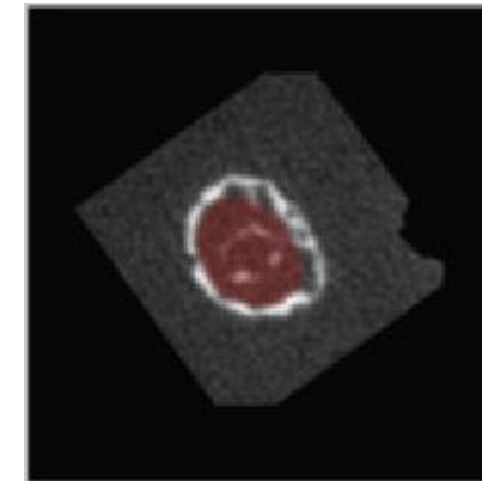
Transverse 1



Transverse 2

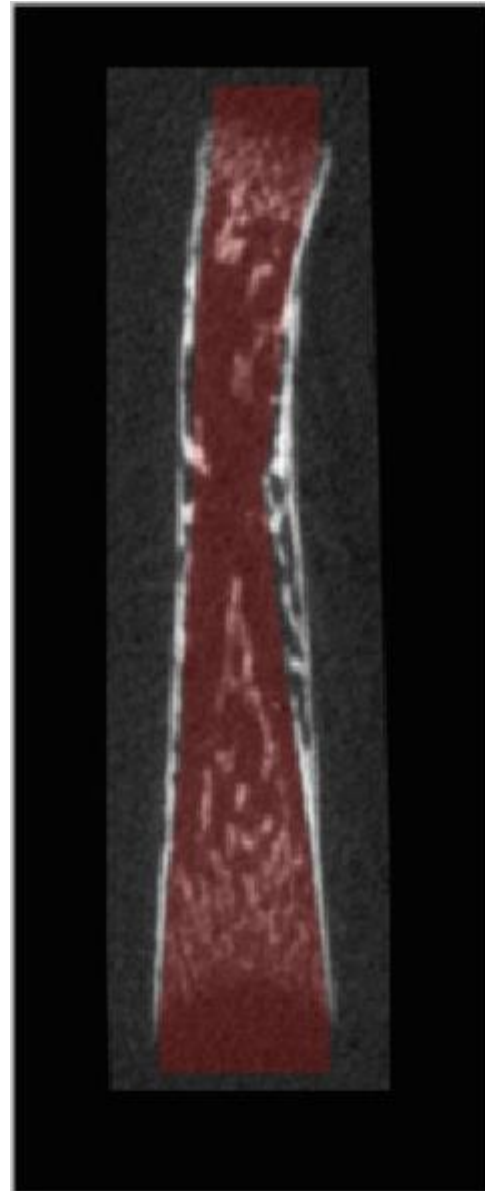


Transverse 3

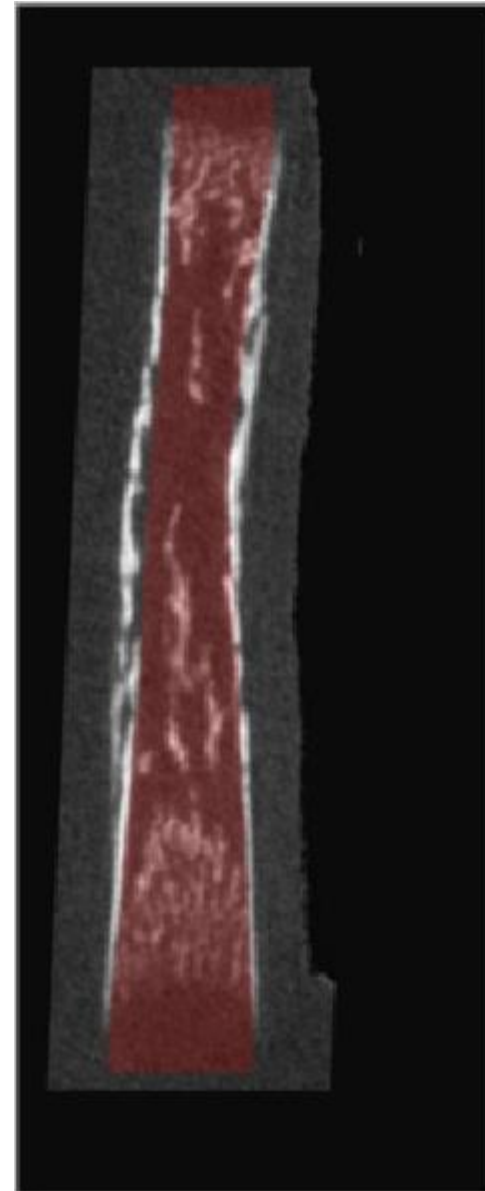


Radius - P1  
Gray scale = Bone CT slide  
Semi-transparent red = Masked regions


Longitudinal 1



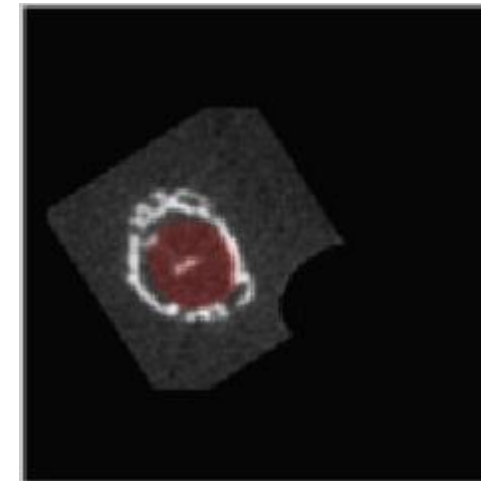
Longitudinal 2



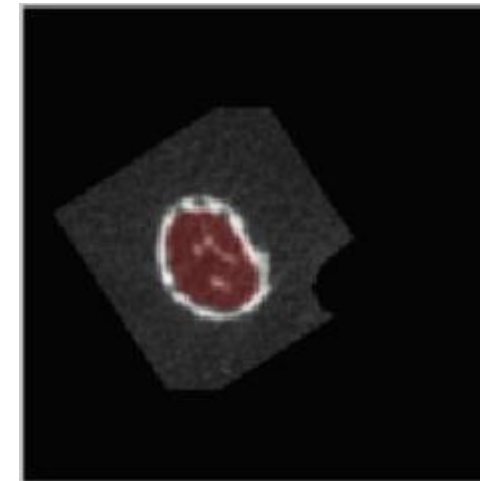
Transverse 1



Transverse 2

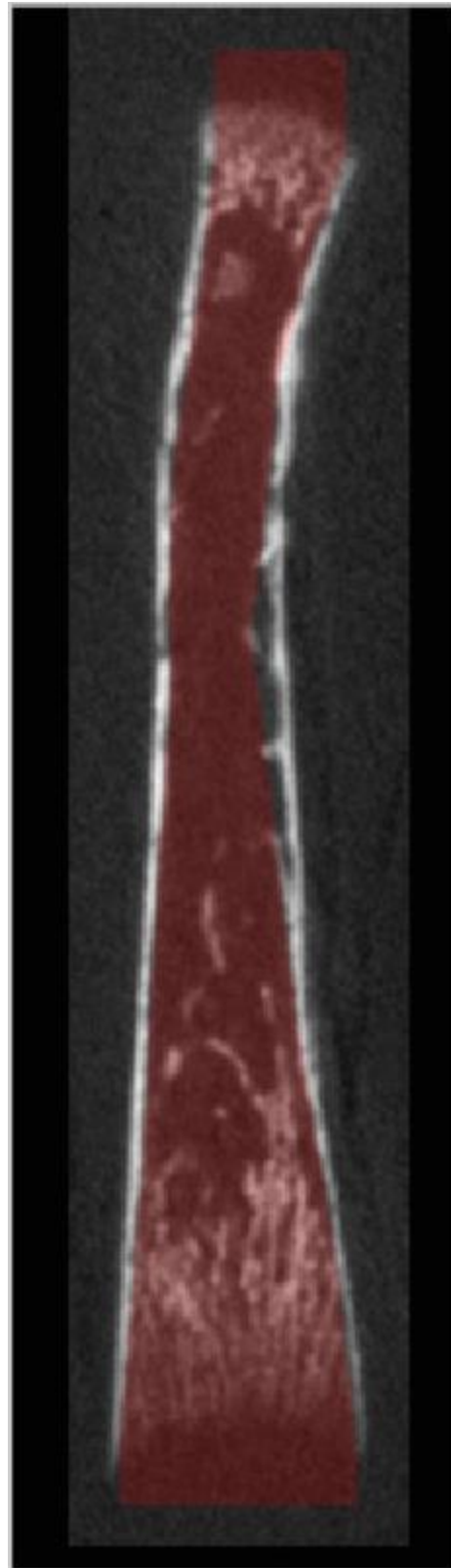


Transverse 3

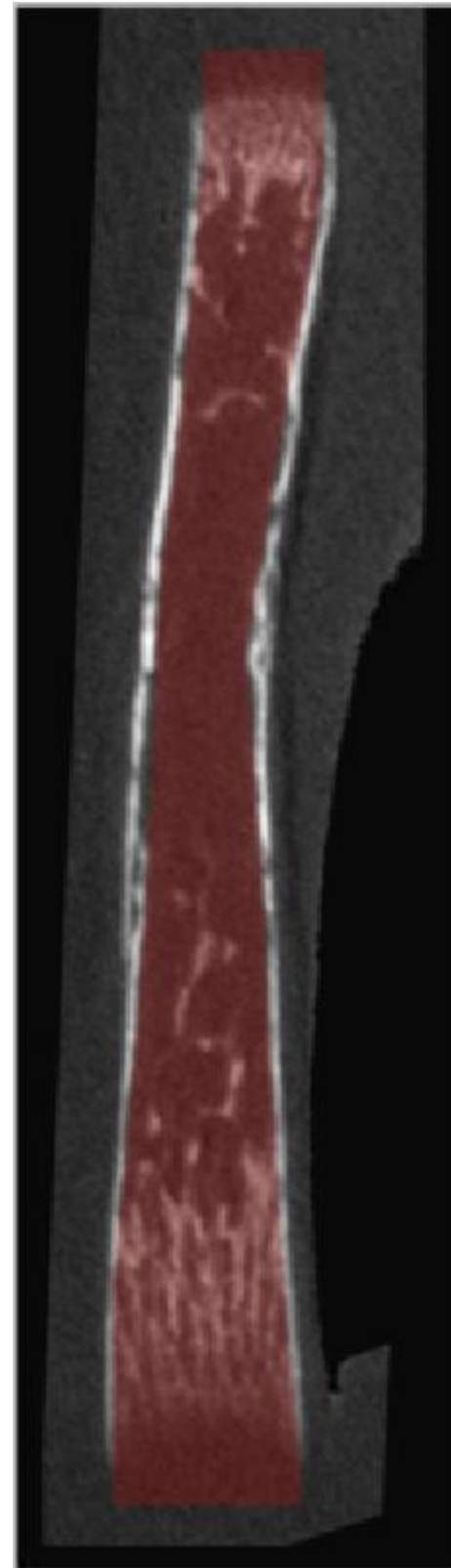


Radius - P2  
Gray scale = Bone CT slide  
Semi-transparent red = Masked regions

Longitudinal 1

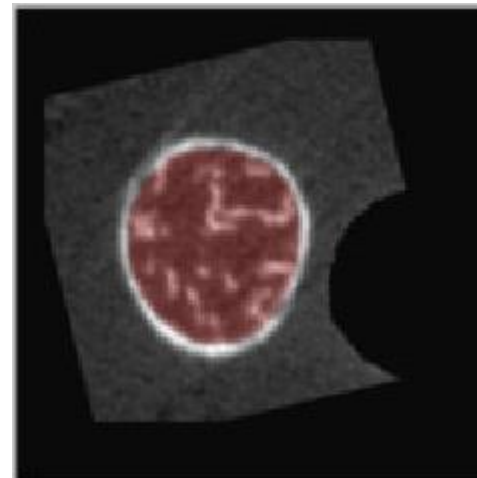


Longitudinal 2

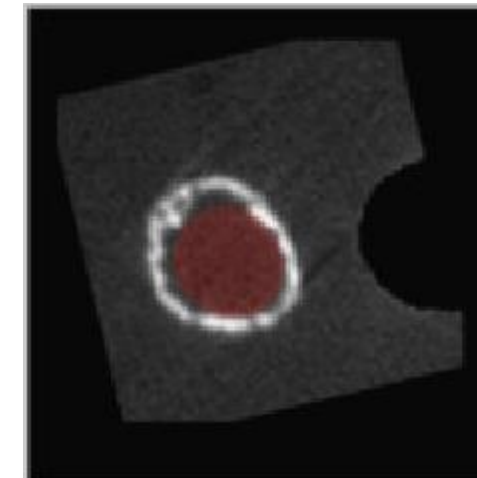


Radius - P4  
Gray scale = Bone CT slide  
Semi-transparent red = Masked regions

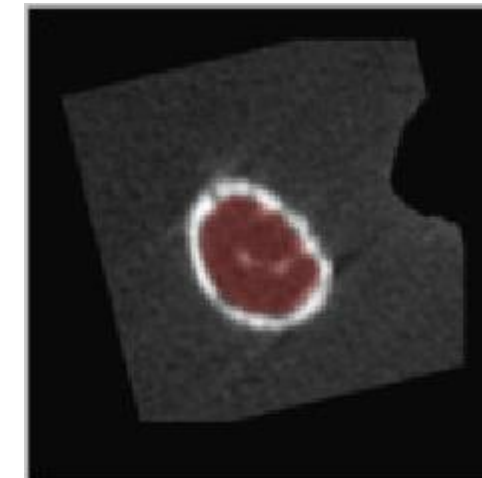
Transverse 1



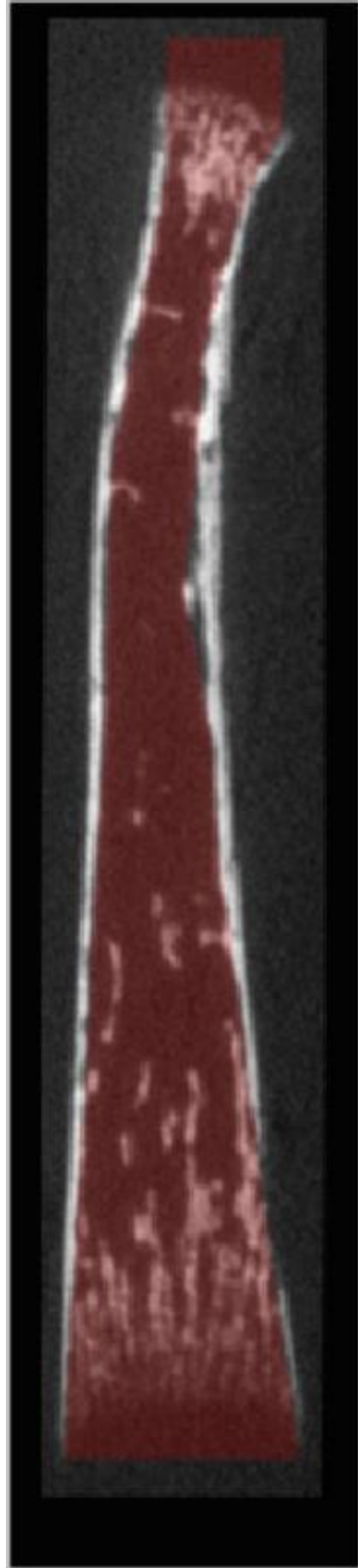
Transverse 2



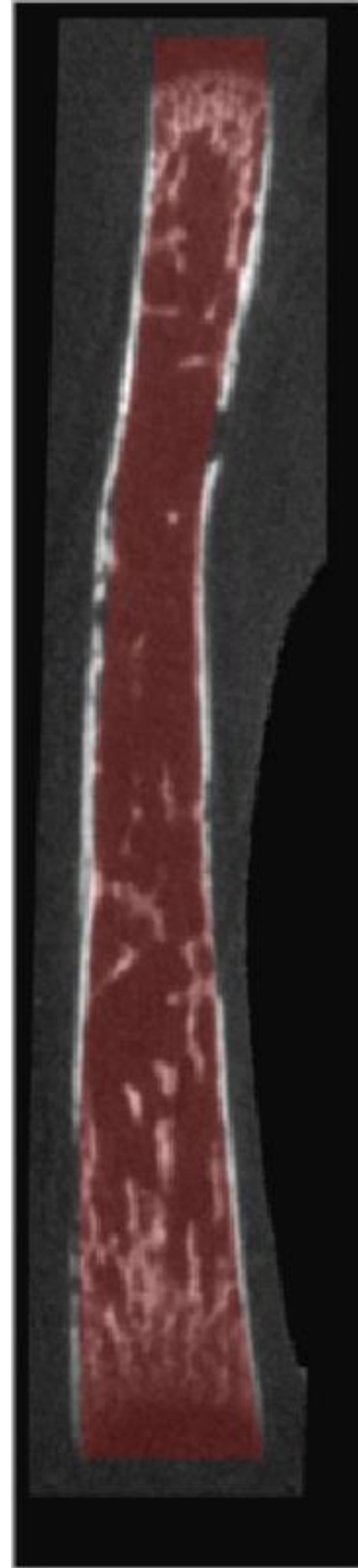
Transverse 3



Longitudinal 1

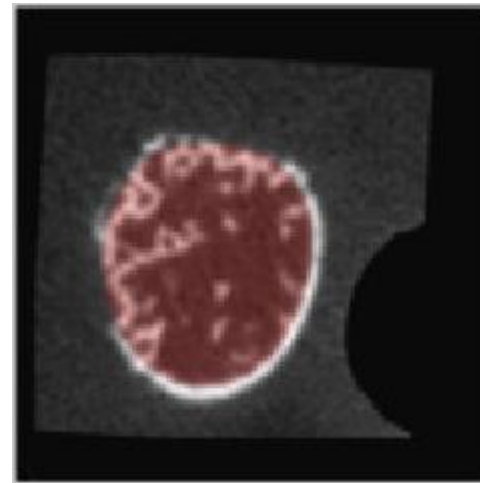


Longitudinal 2

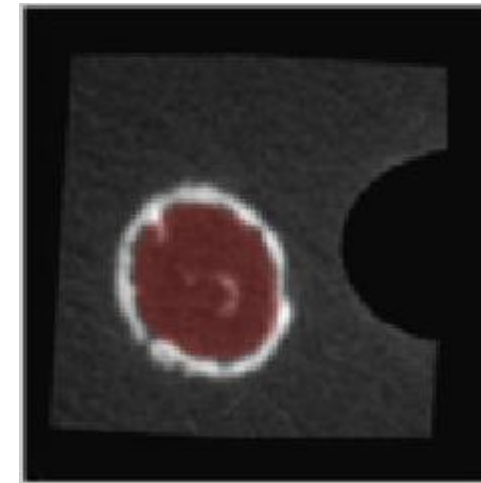


Radius - P6  
Gray scale = Bone CT slide  
Semi-transparent red = Masked regions

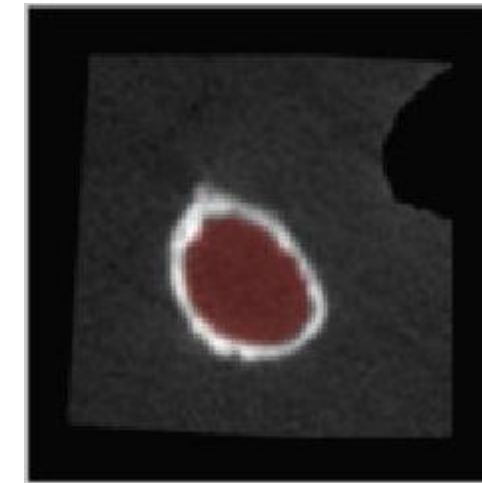
Transverse 1



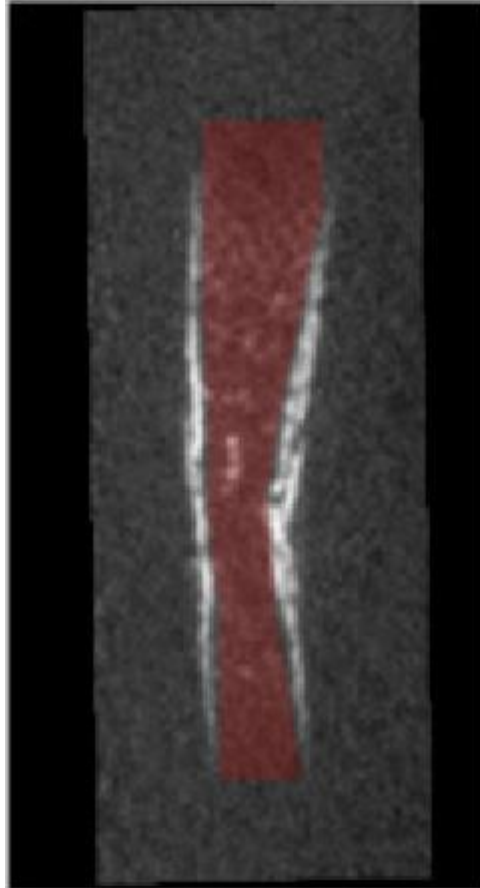
Transverse 2



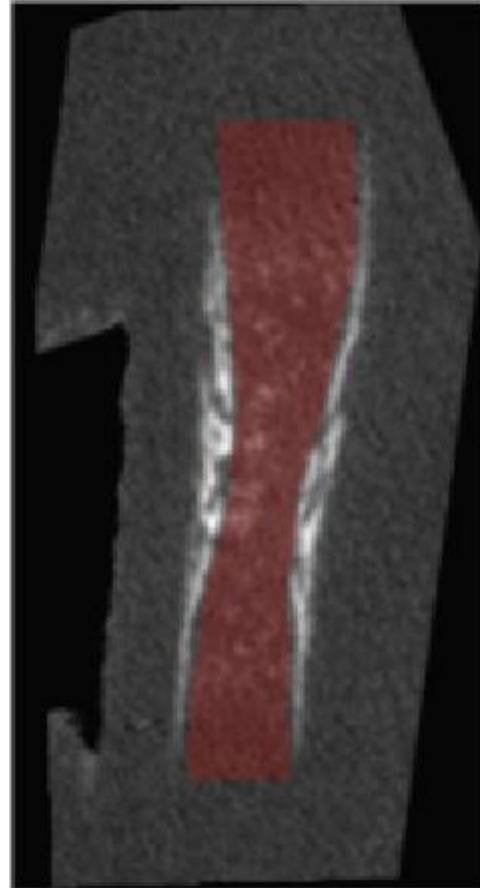
Transverse 3




Longitudinal 1



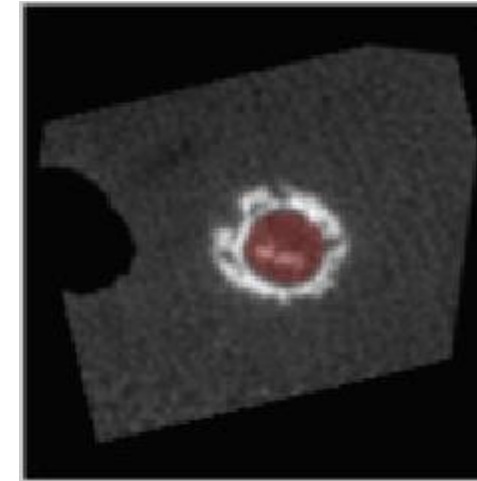
Longitudinal 2




Transverse 1



Transverse 2

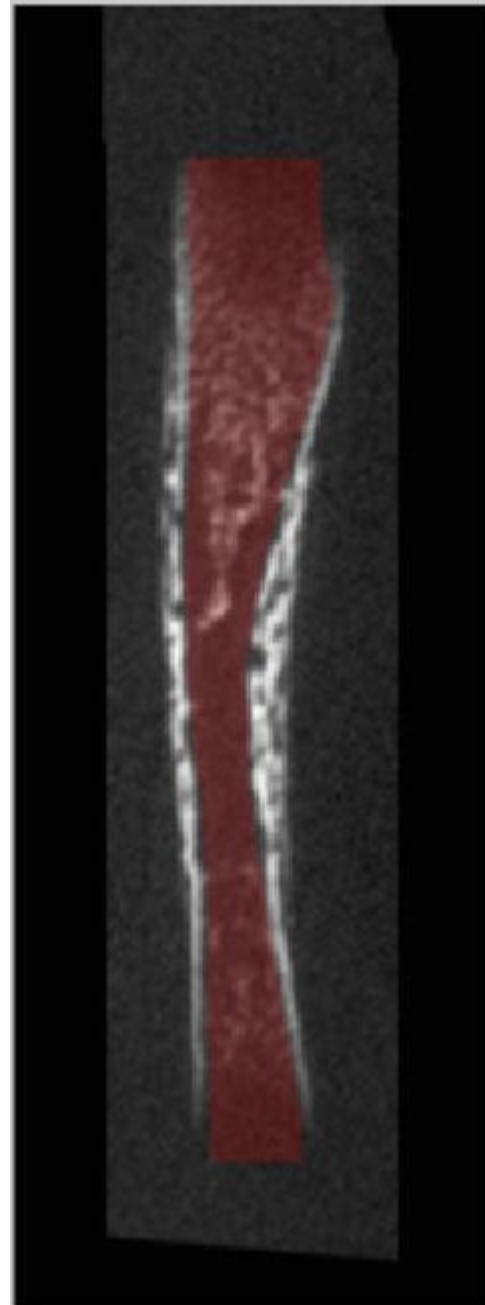


Transverse 3

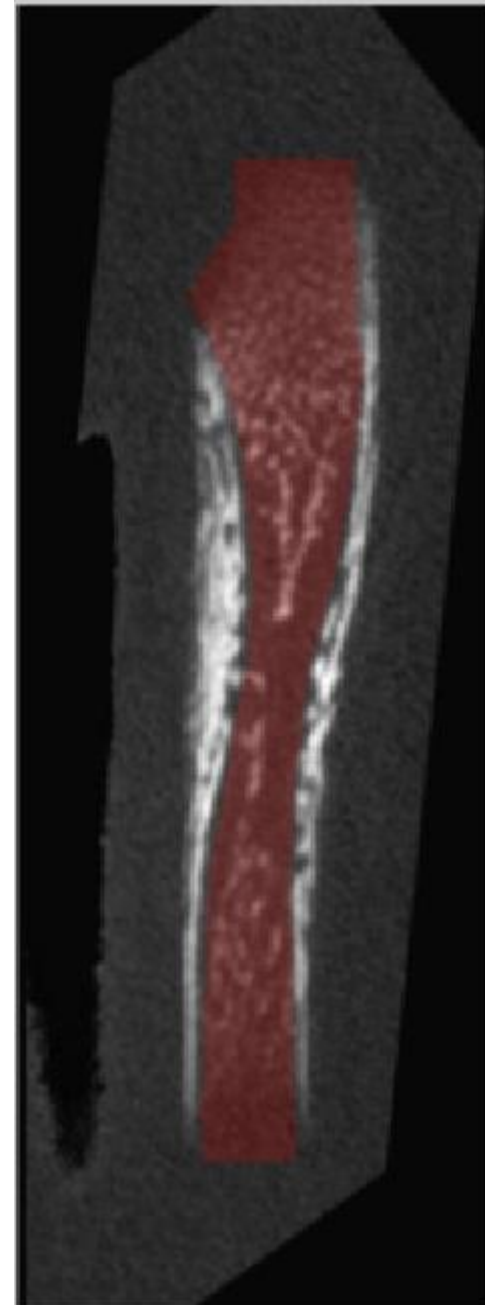


Ulna - E16  
Gray scale = Bone CT slide  
Semi-transparent red = Masked regions

Longitudinal 1

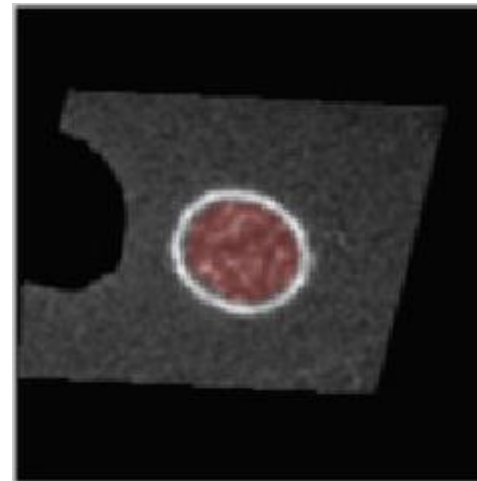


Longitudinal 2




Ulna - E17  
Gray scale = Bone CT slide  
Semi-transparent red = Masked regions

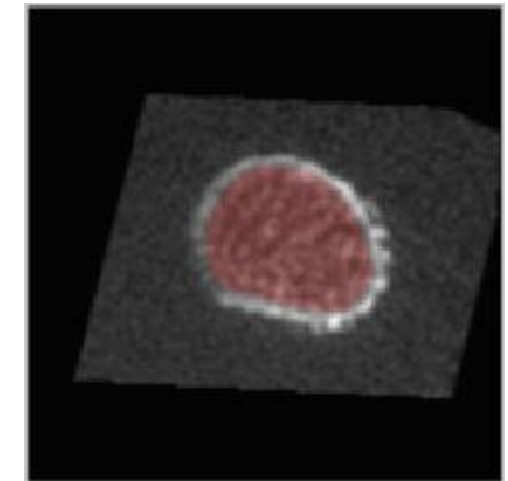
Transverse 1



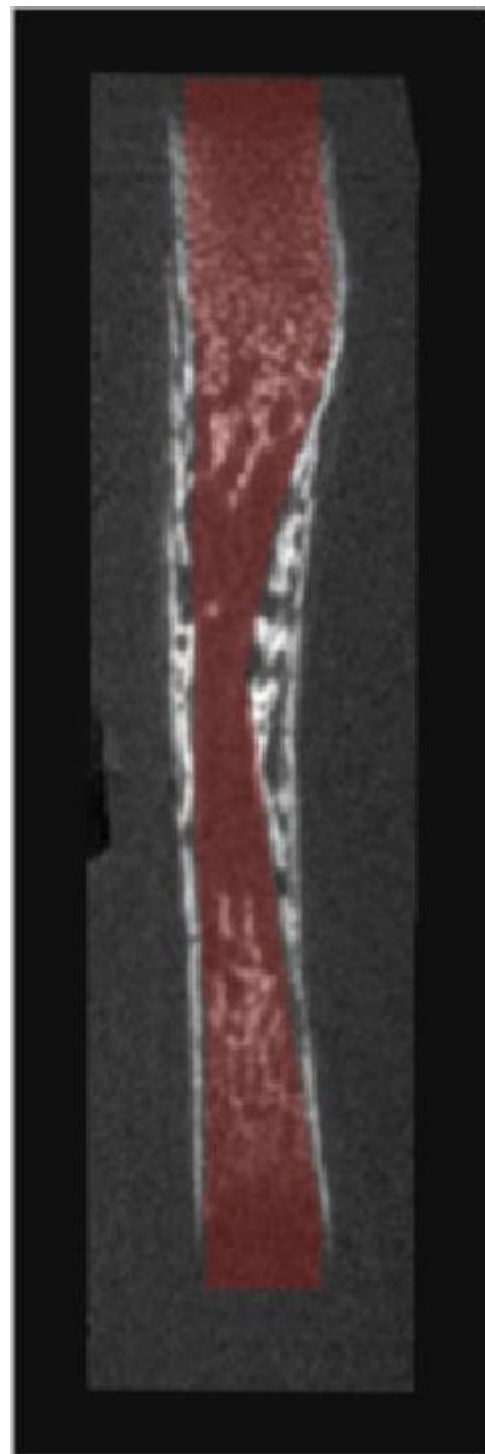
Transverse 2



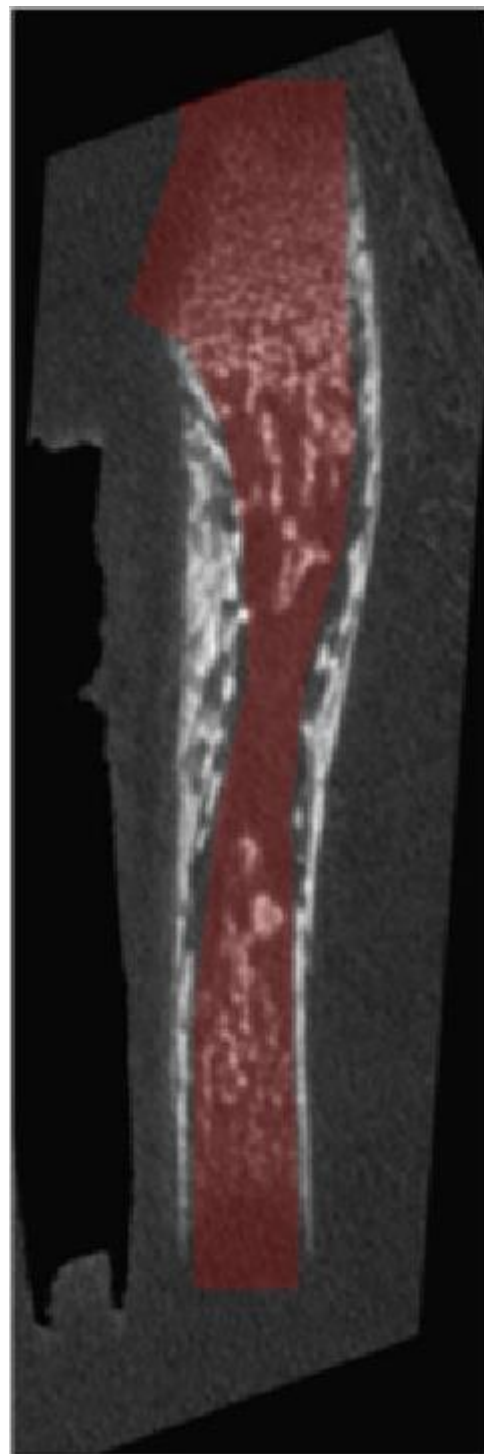
Transverse 3



Longitudinal 1




Longitudinal 2

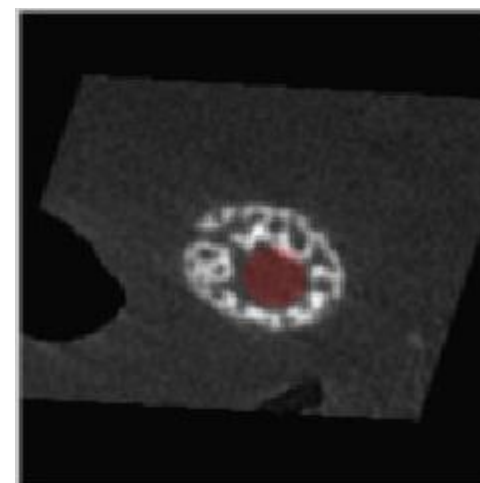


Ulna - E18  
Gray scale = Bone CT slide  
Semi-transparent red = Masked regions

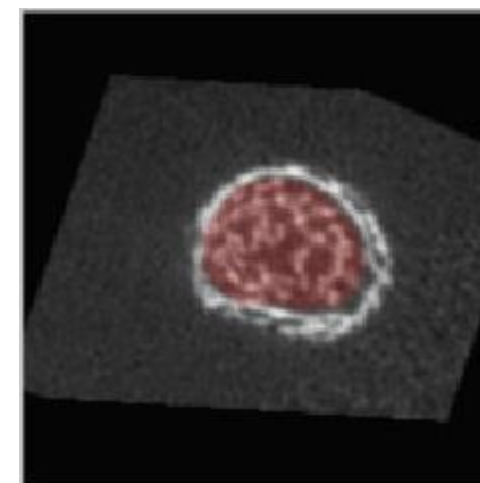
Transverse 1



Transverse 2

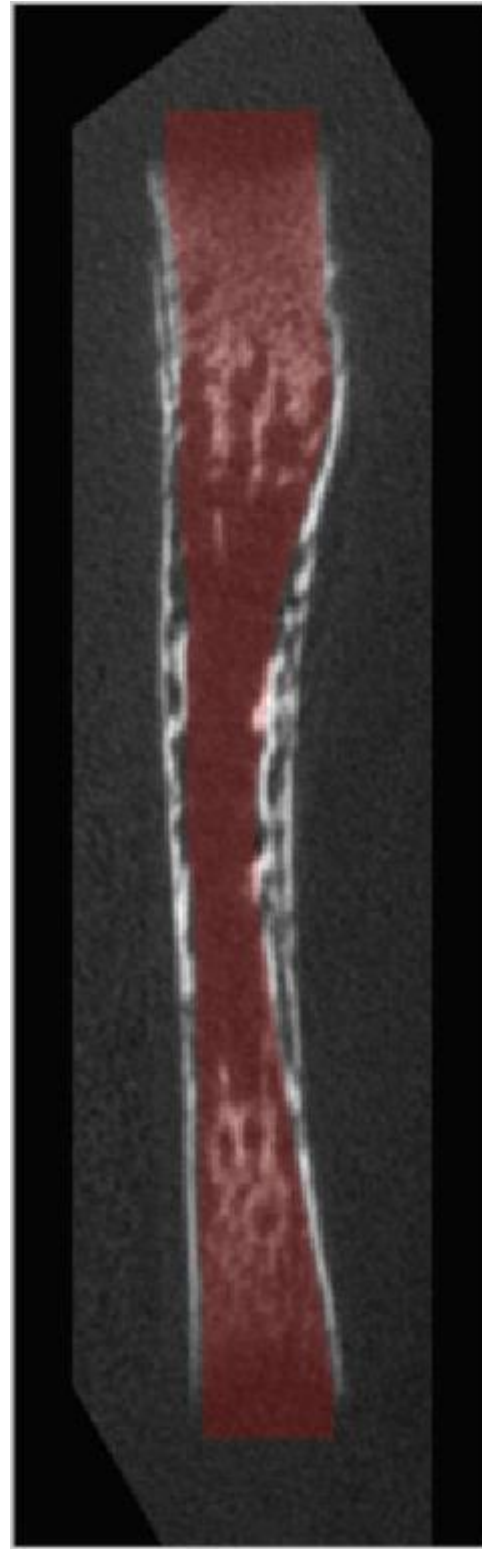


Transverse 3

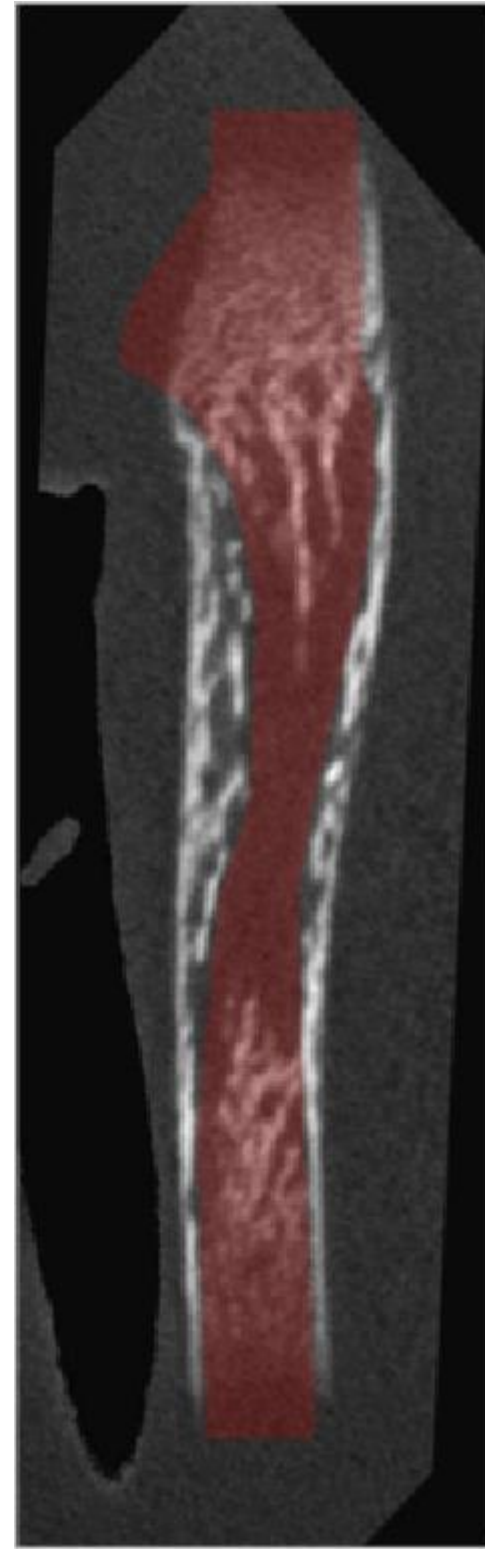




Longitudinal 1

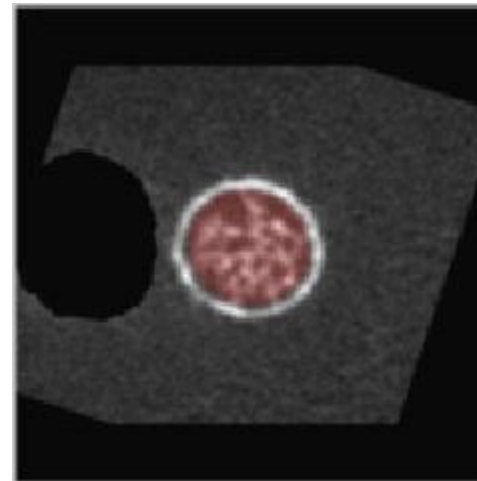


Longitudinal 2

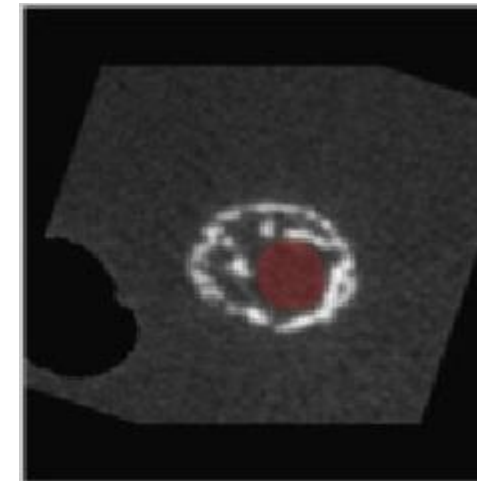


Ulna - P1  
Gray scale = Bone CT slide  
Semi-transparent red = Masked regions

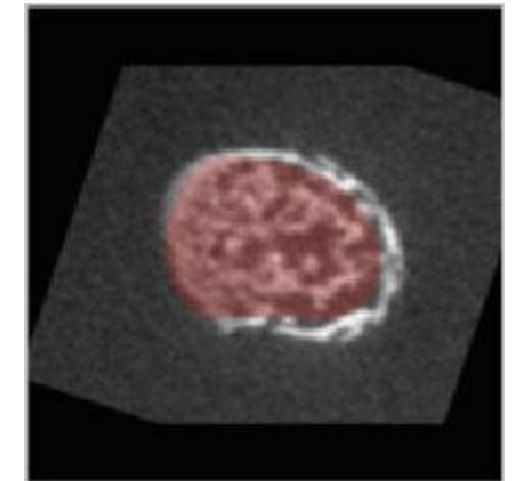
Transverse 1



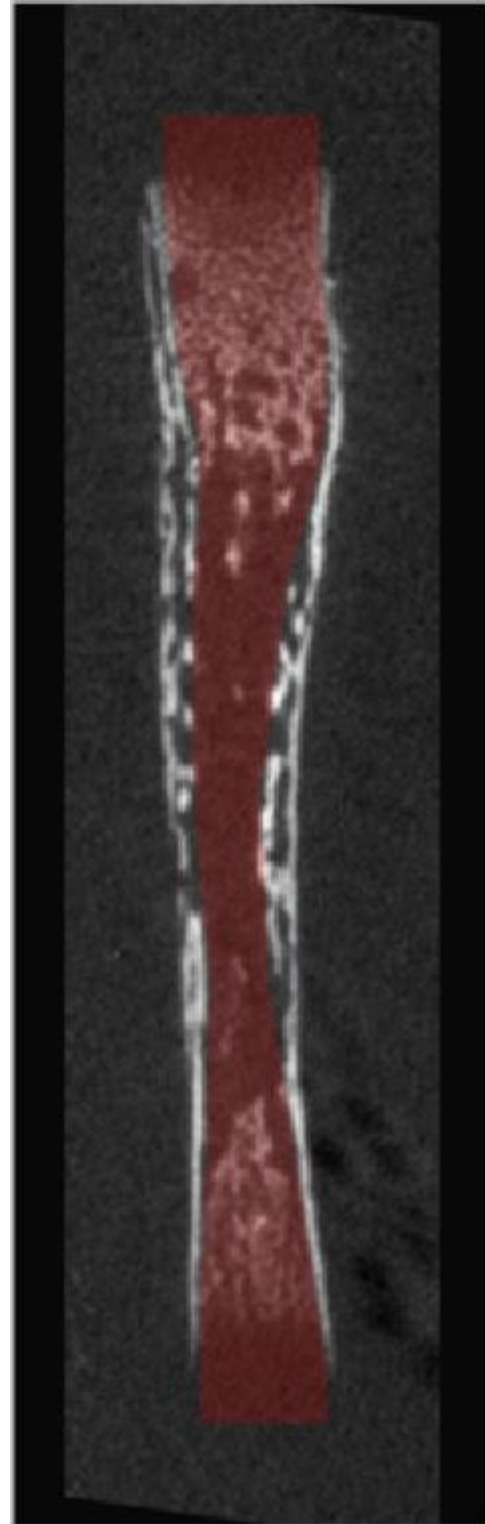
Transverse 2



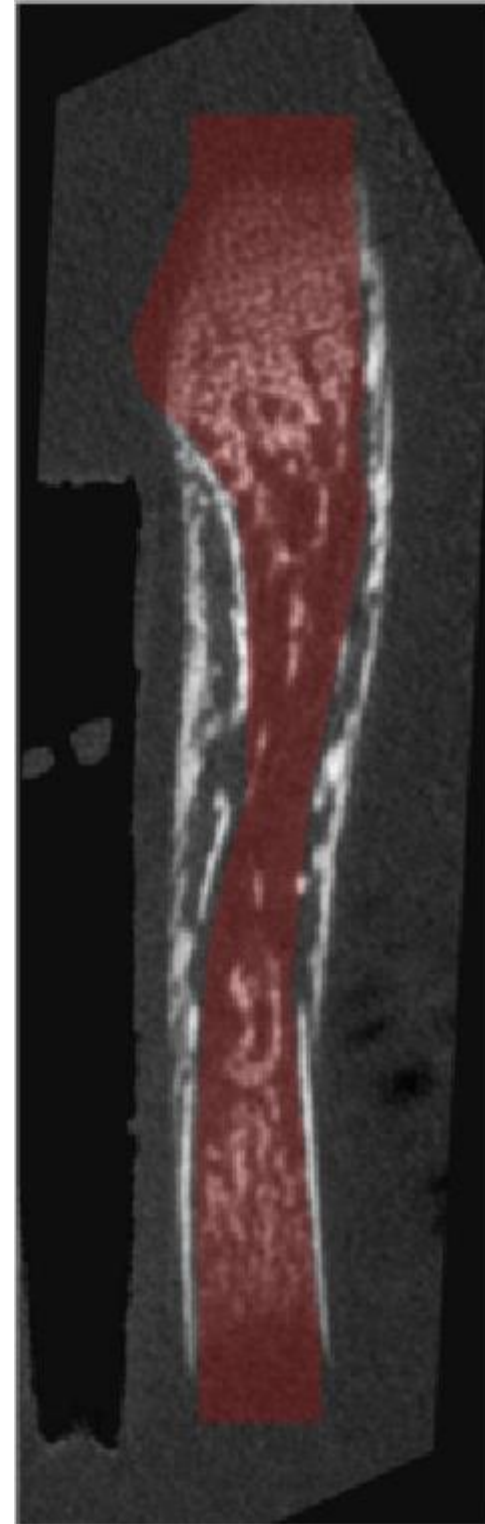
Transverse 3



Longitudinal 1

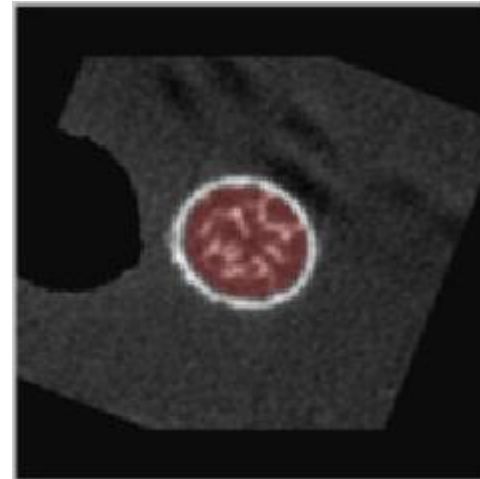


Longitudinal 2

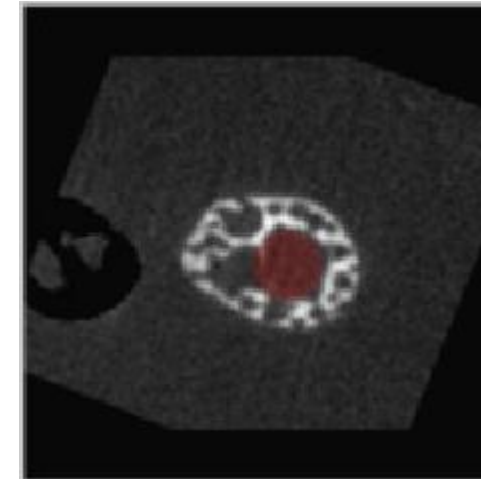


Ulna - P2  
Gray scale = Bone CT slide  
Semi-transparent red = Masked regions

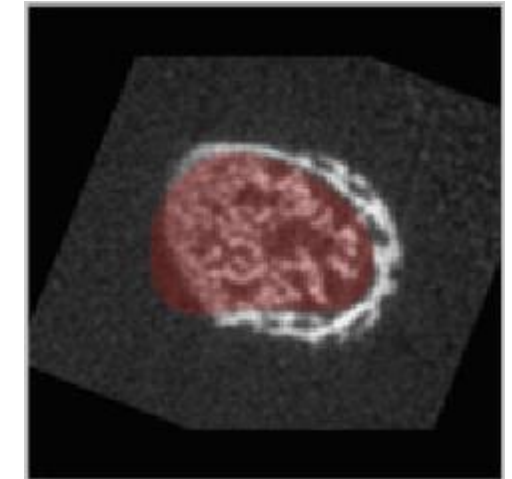
Transverse 1



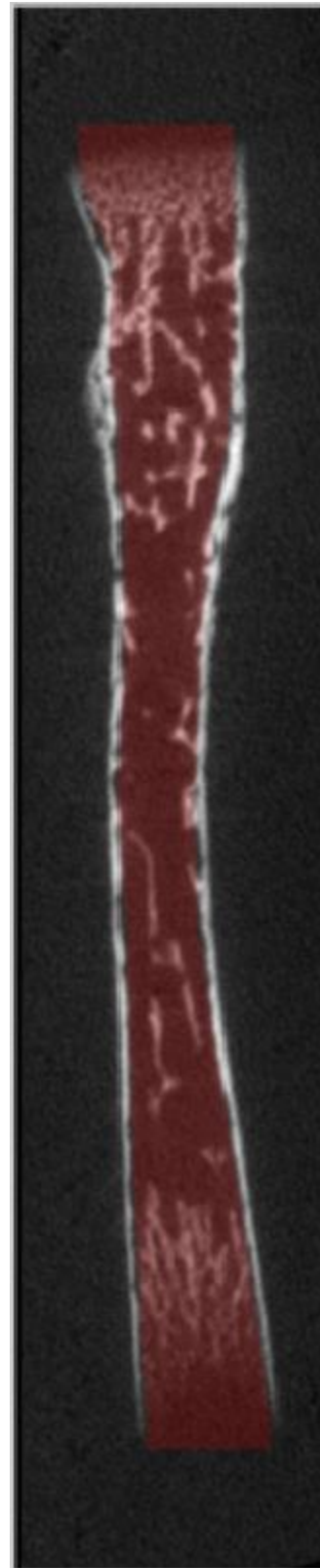
Transverse 2



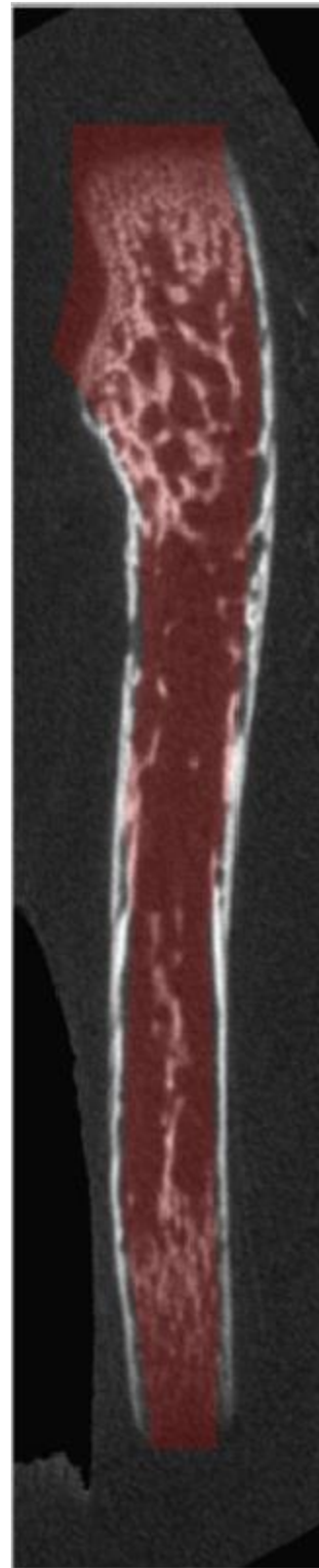
Transverse 3



Longitudinal 1

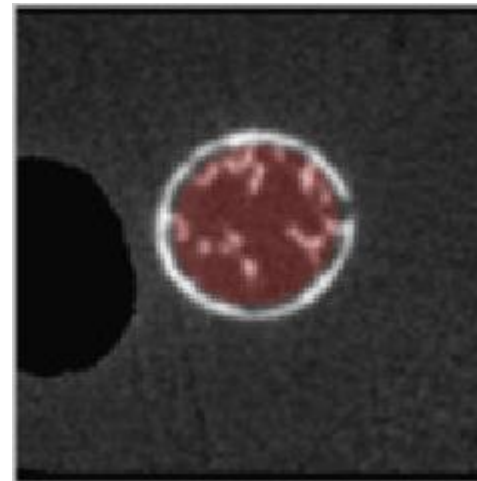


Longitudinal 2

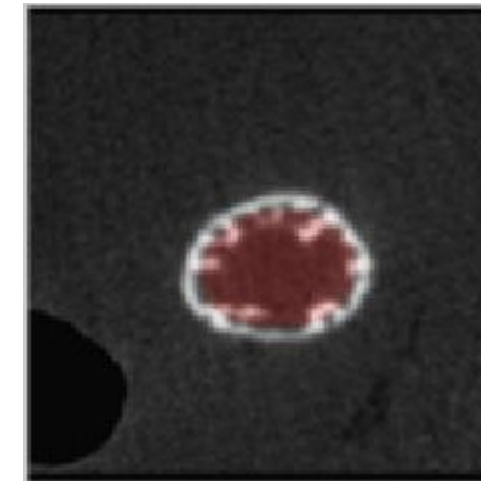


Ulna - P4  
Gray scale = Bone CT slide  
Semi-transparent red = Masked regions

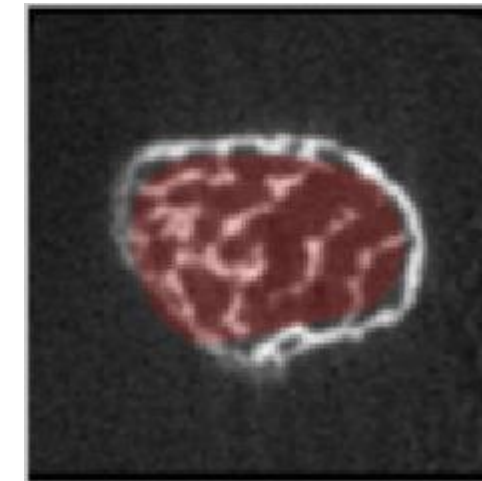
Transverse 1



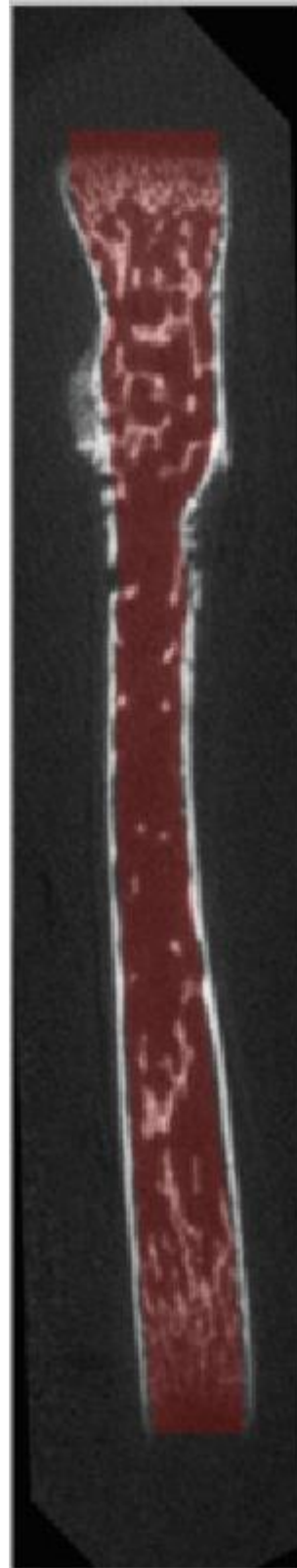
Transverse 2



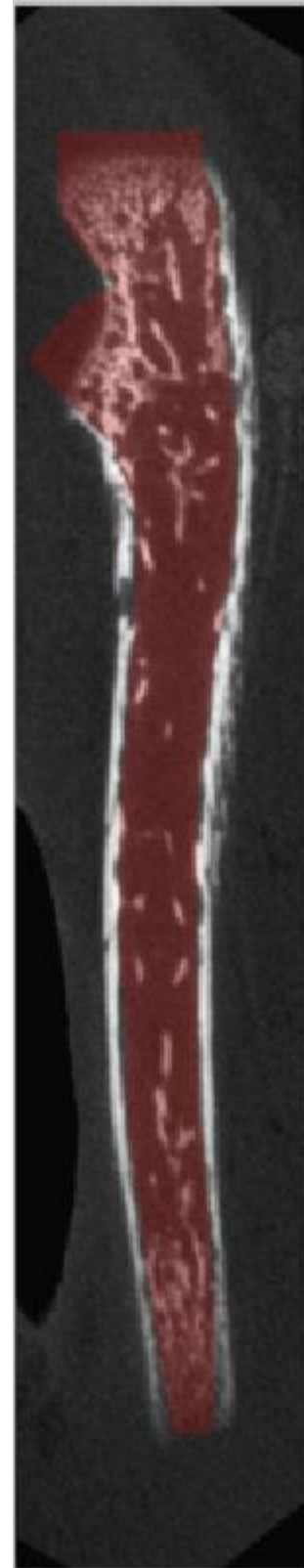
Transverse 3



Longitudinal 1

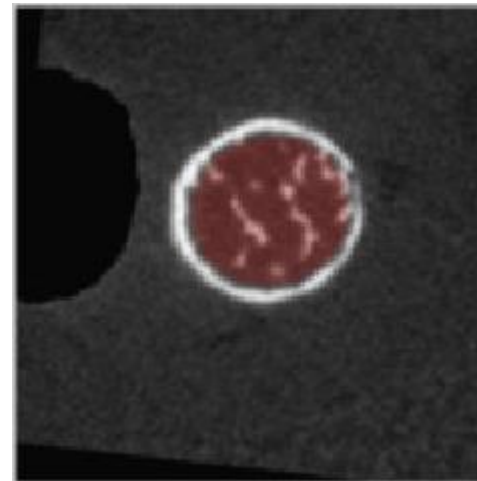


Longitudinal 2

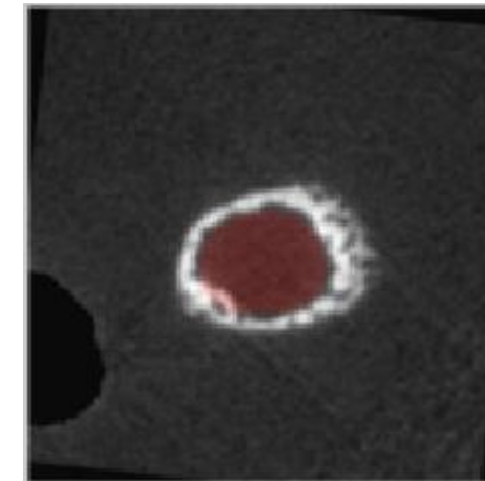


Ulna - P6  
Gray scale = Bone CT slide  
Semi-transparent red = Masked regions

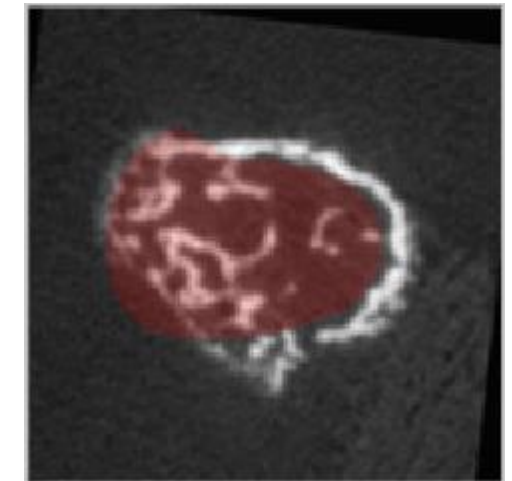
Transverse 1



Transverse 2



Transverse 3

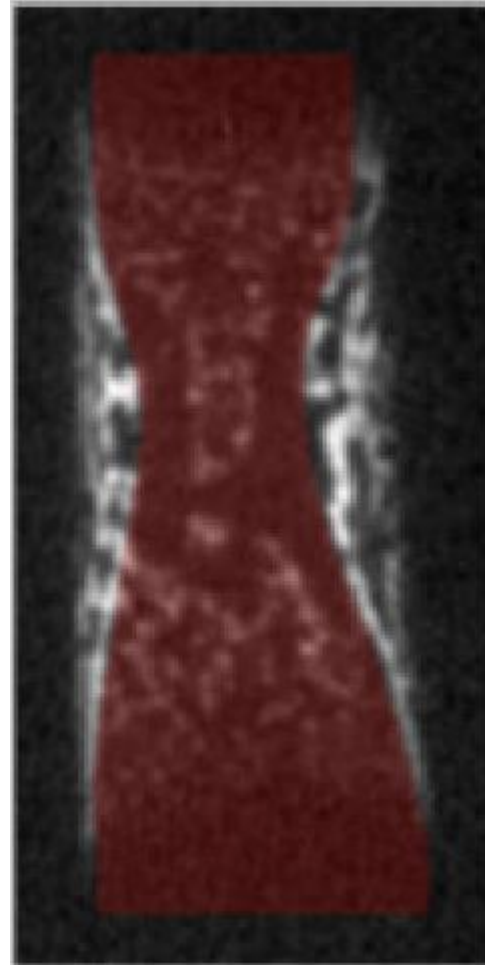


Femur – E16

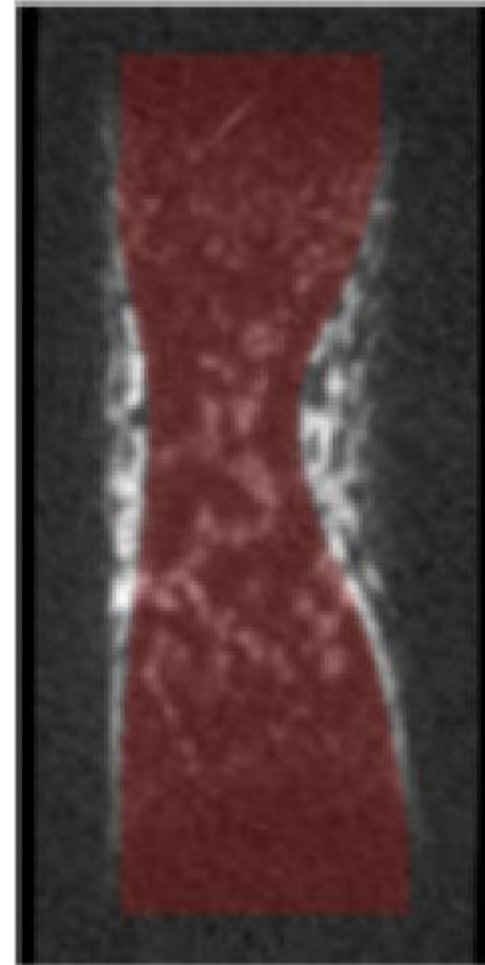
Gray scale = Bone CT slide

Semi-transparent red = Masked regions


Longitudinal 1



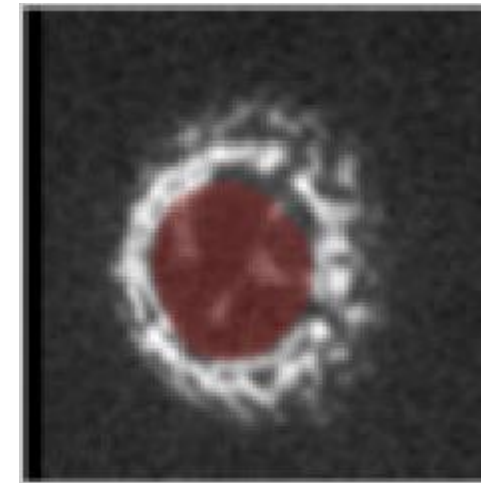
Longitudinal 2



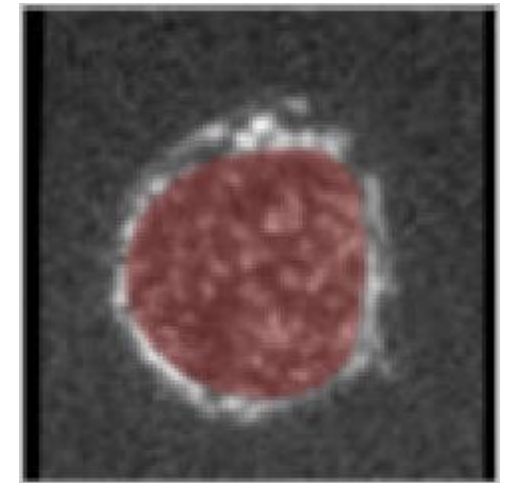
Transverse 1



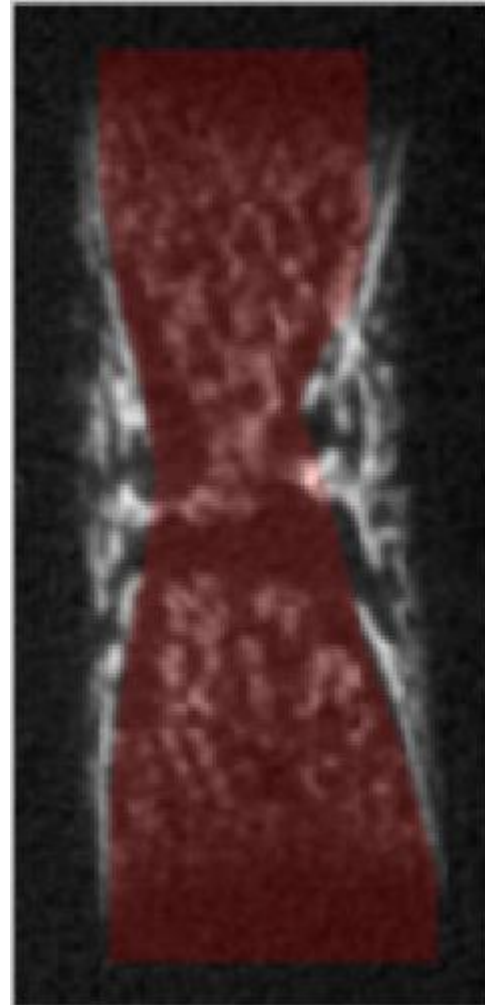
Transverse 2



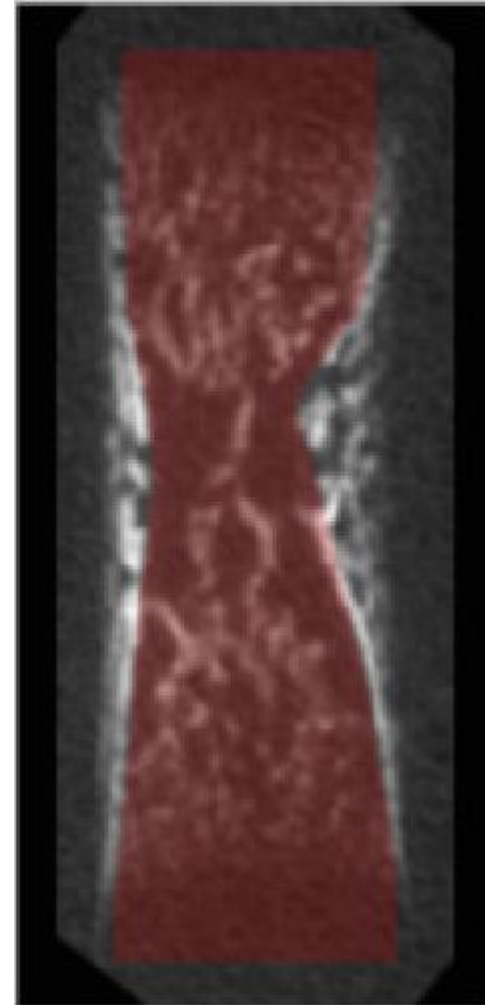
Transverse 3



Longitudinal 1



Longitudinal 2

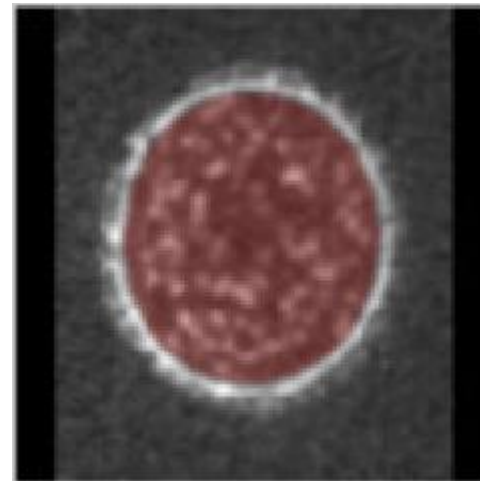


Femur - E17

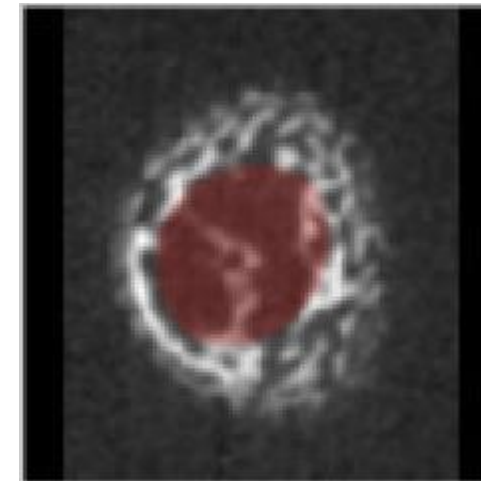
Gray scale = Bone CT slide

Semi-transparent red = Masked regions

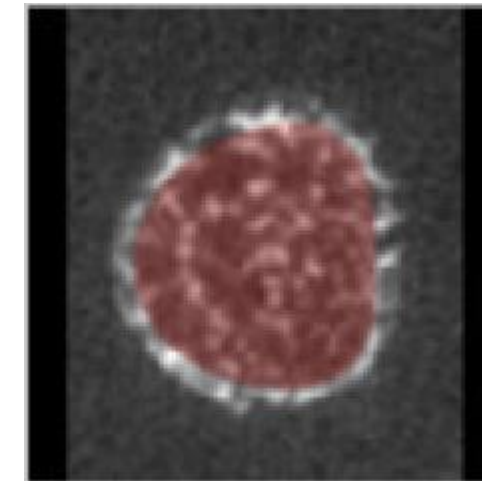
Transverse 1



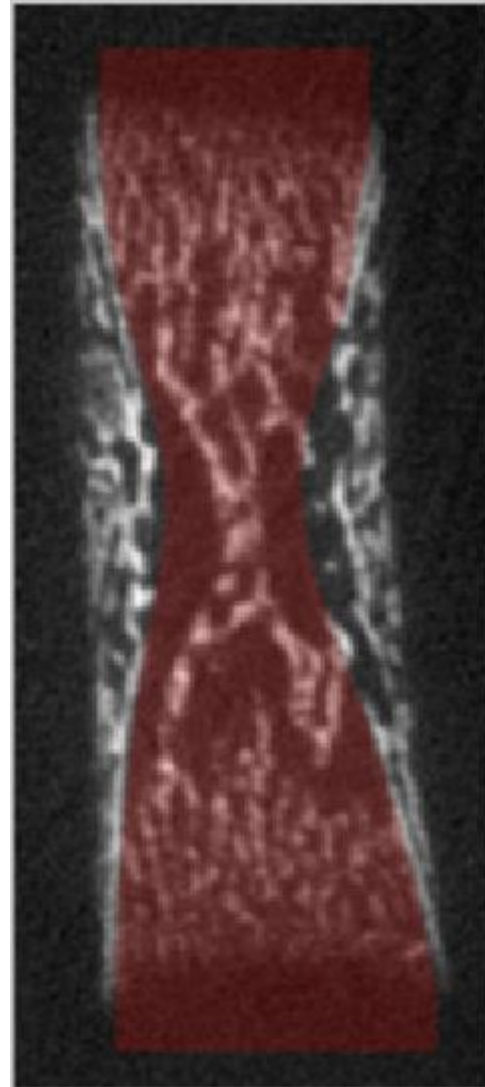
Transverse 2



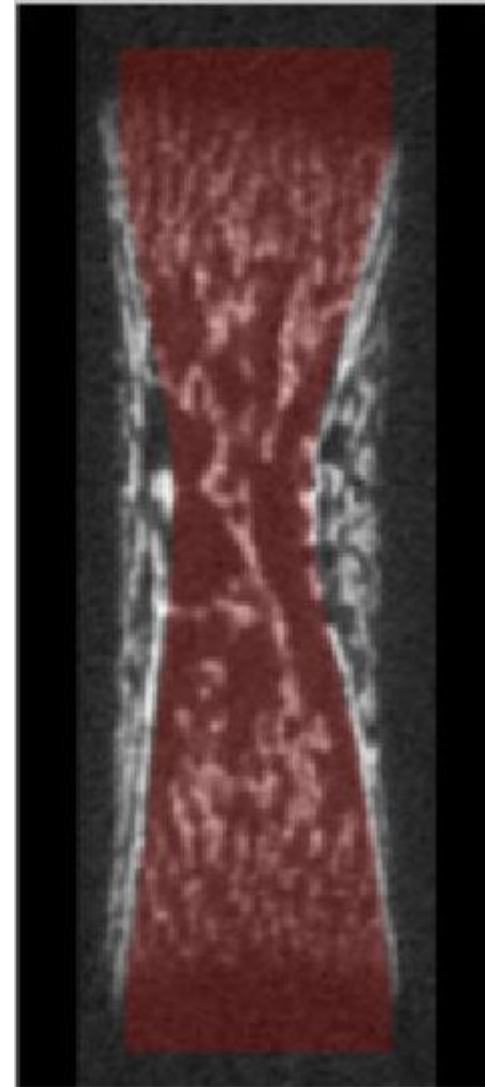
Transverse 3



Longitudinal 1

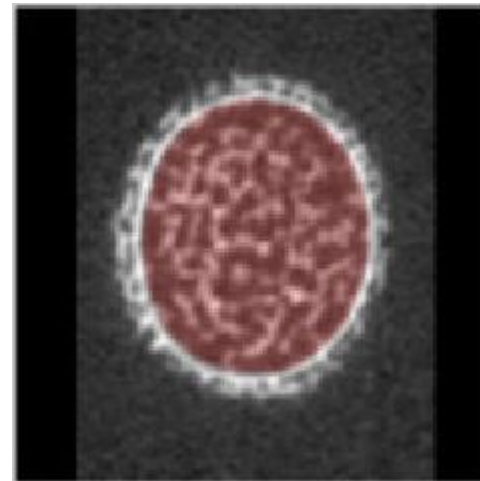


Longitudinal 2

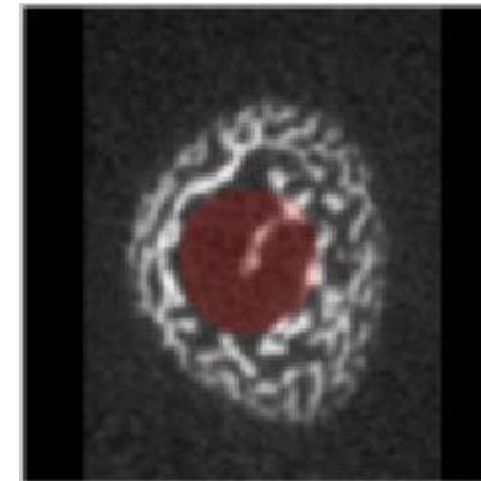


Femur – E18  
Gray scale = Bone CT slide  
Semi-transparent red = Masked regions

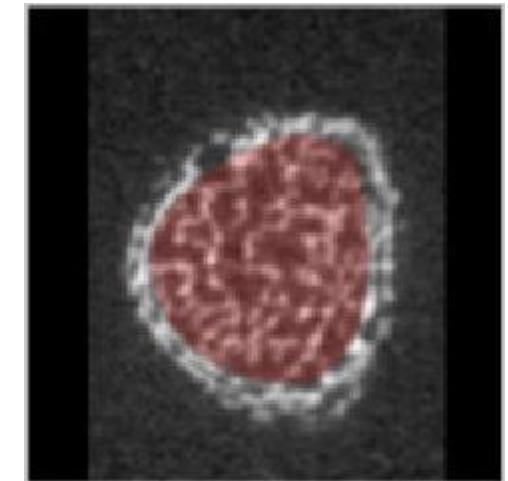
Transverse 1



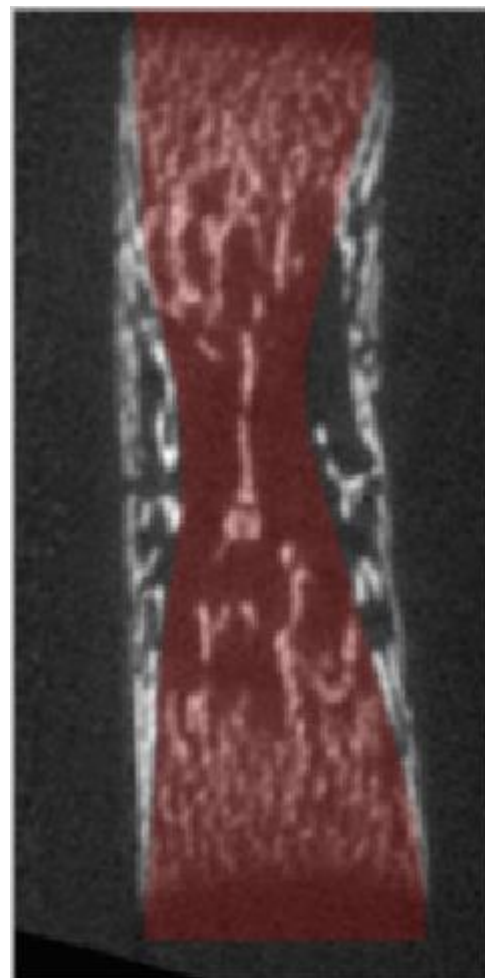
Transverse 2



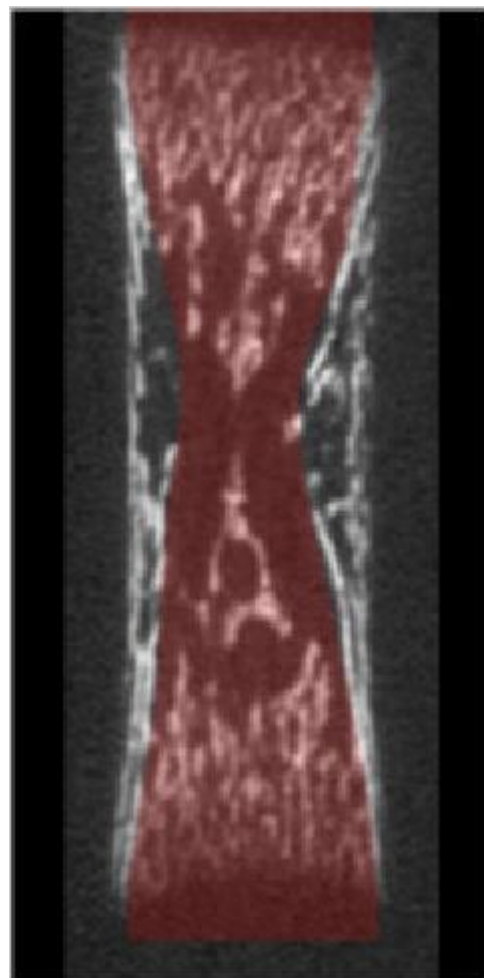
Transverse 3



Longitudinal 1

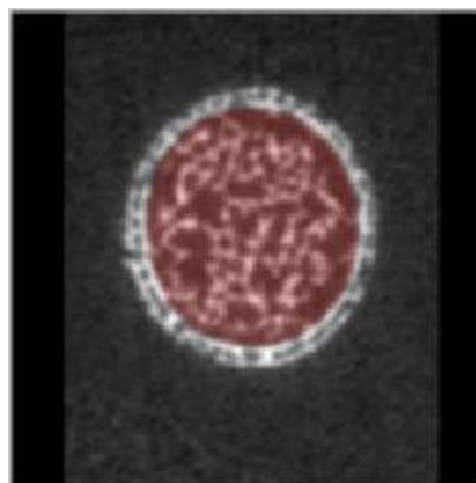


Longitudinal 2

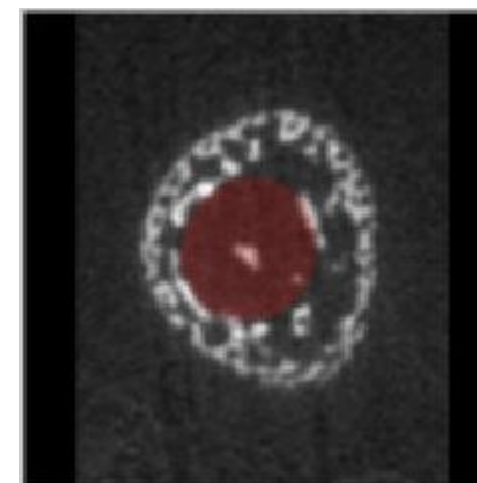


Femur - P1  
Gray scale = Bone CT slide  
Semi-transparent red = Masked regions

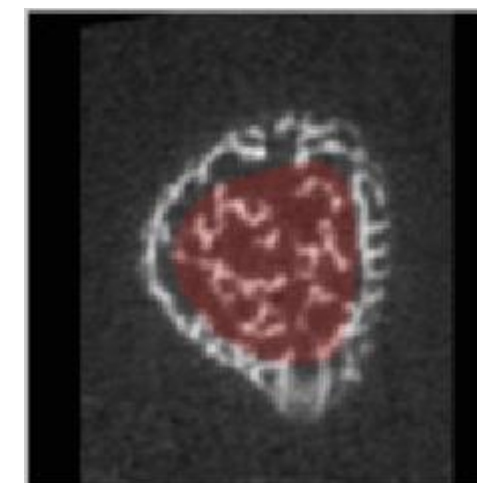
Transverse 1



Transverse 2

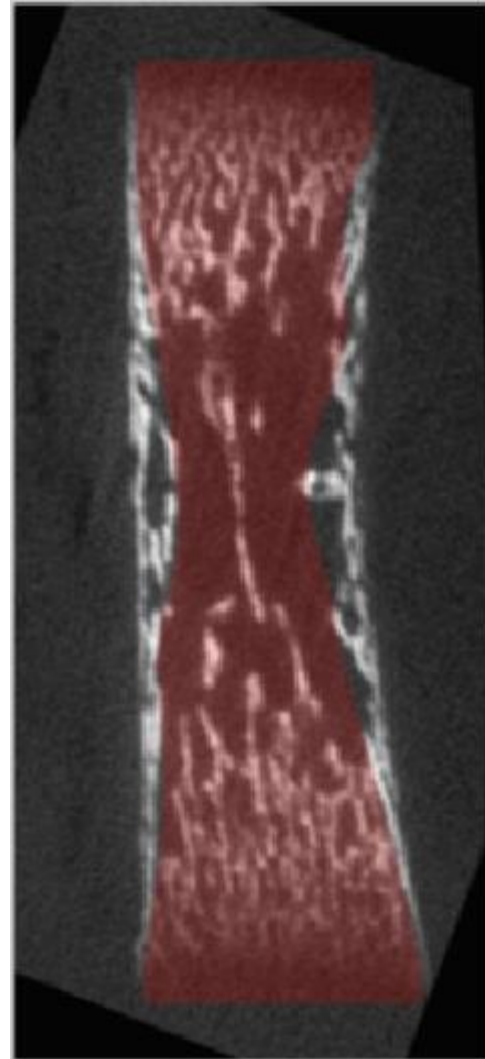


Transverse 3

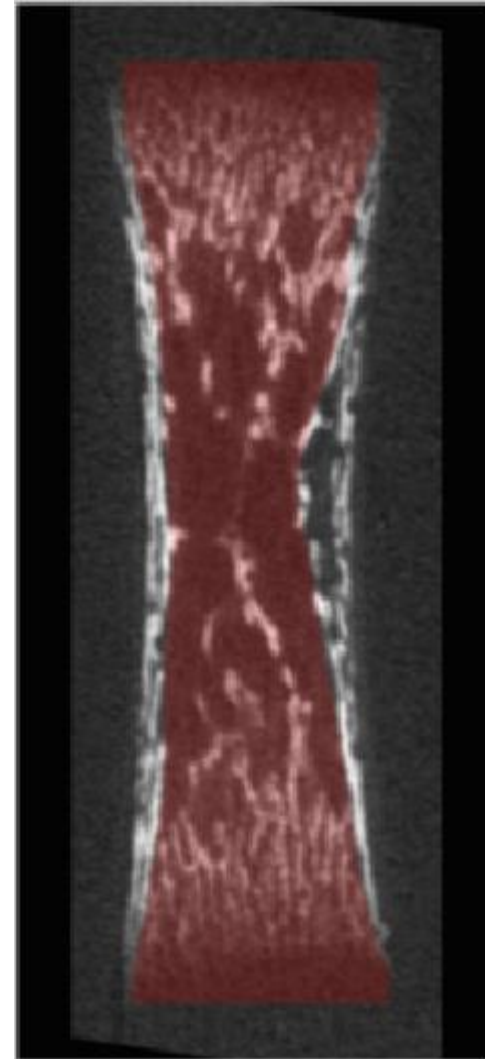




Longitudinal 1

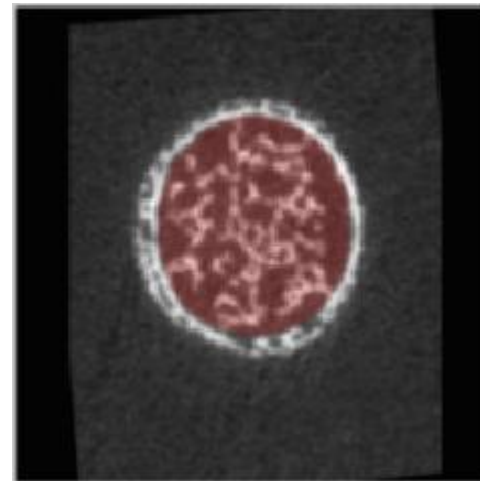


Longitudinal 2

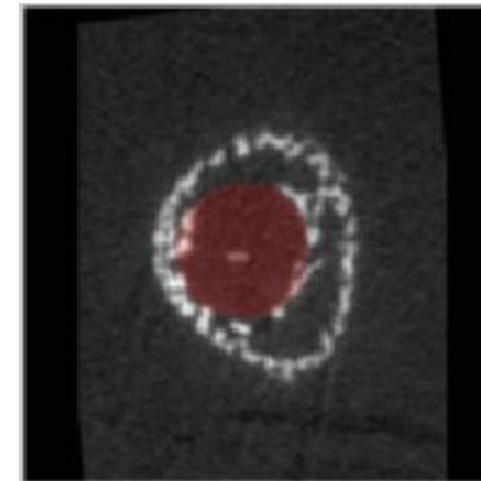


Femur - P2  
Gray scale = Bone CT slide  
Semi-transparent red = Masked regions

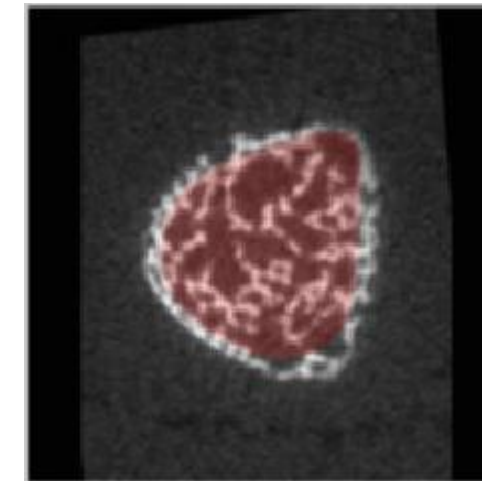
Transverse 1



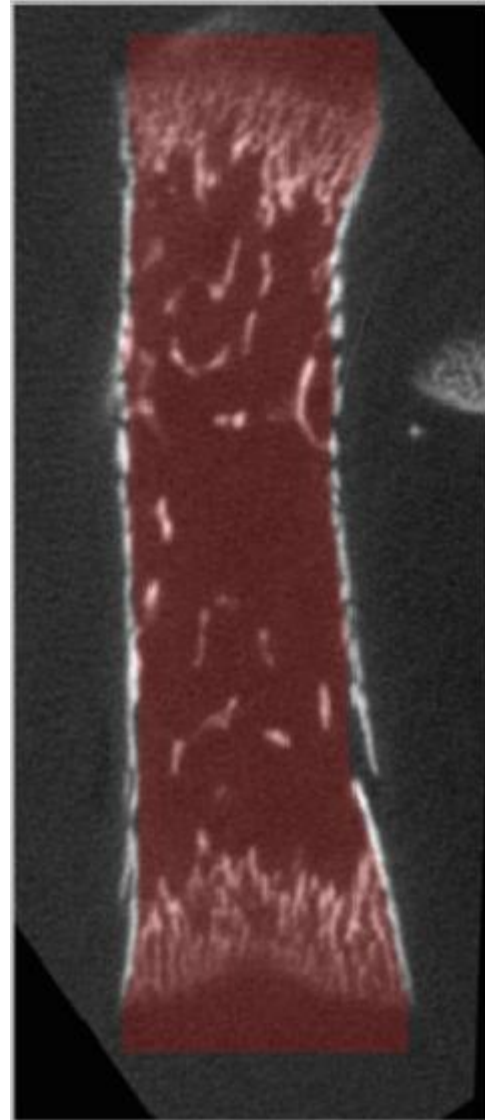
Transverse 2



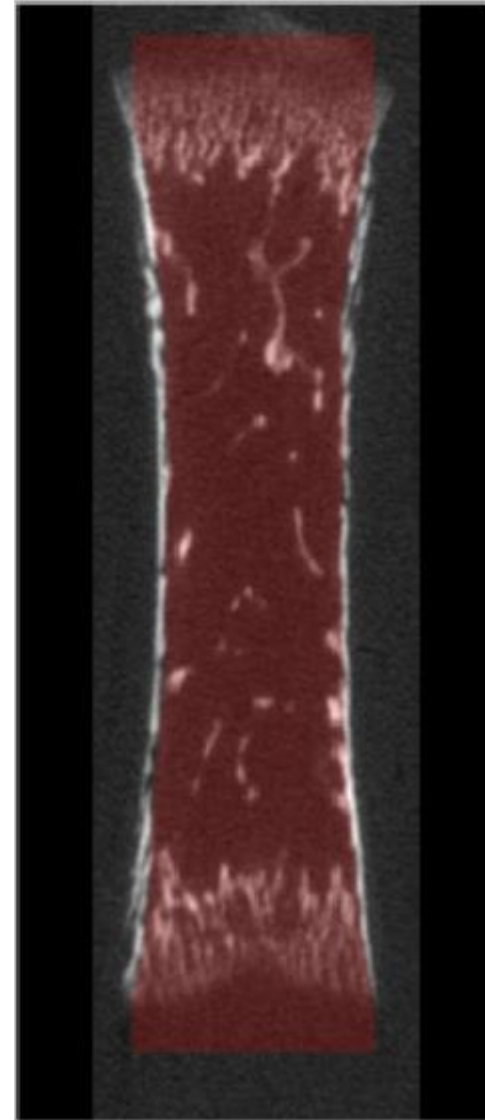
Transverse 3



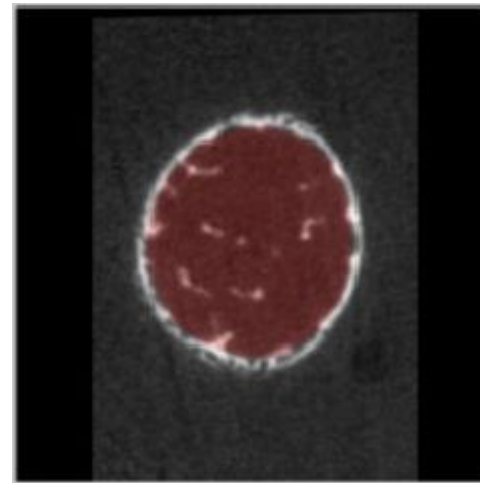
Longitudinal 1



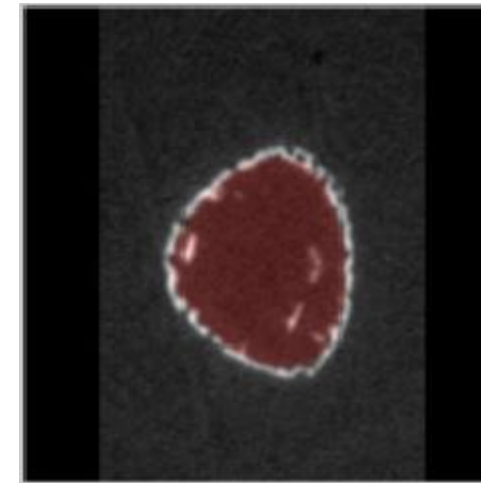
Longitudinal 2



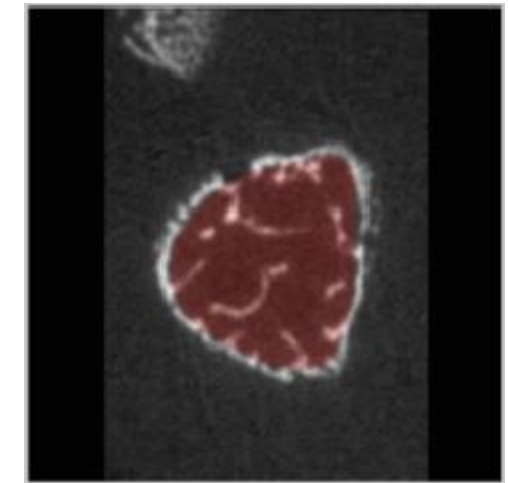
Transverse 1



Transverse 2



Transverse 3

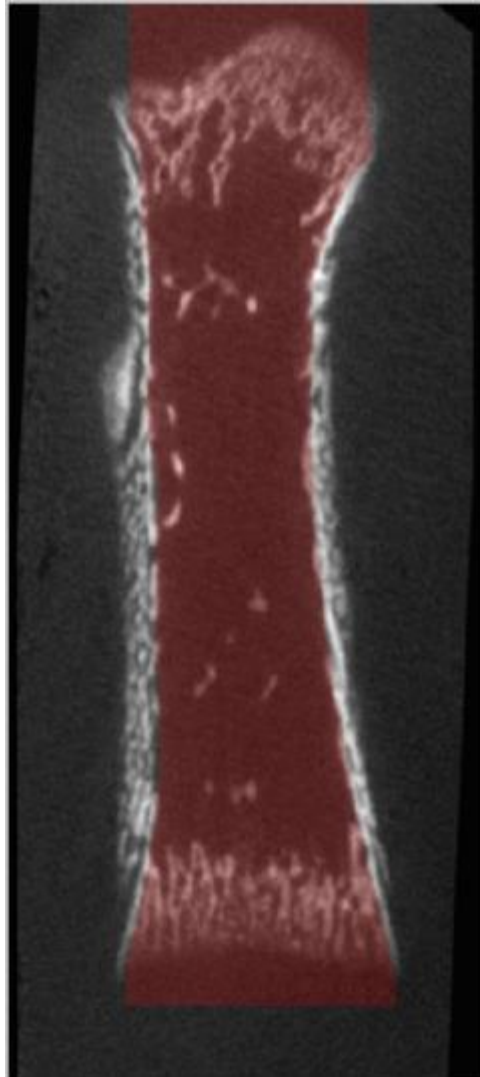


Femur – P4

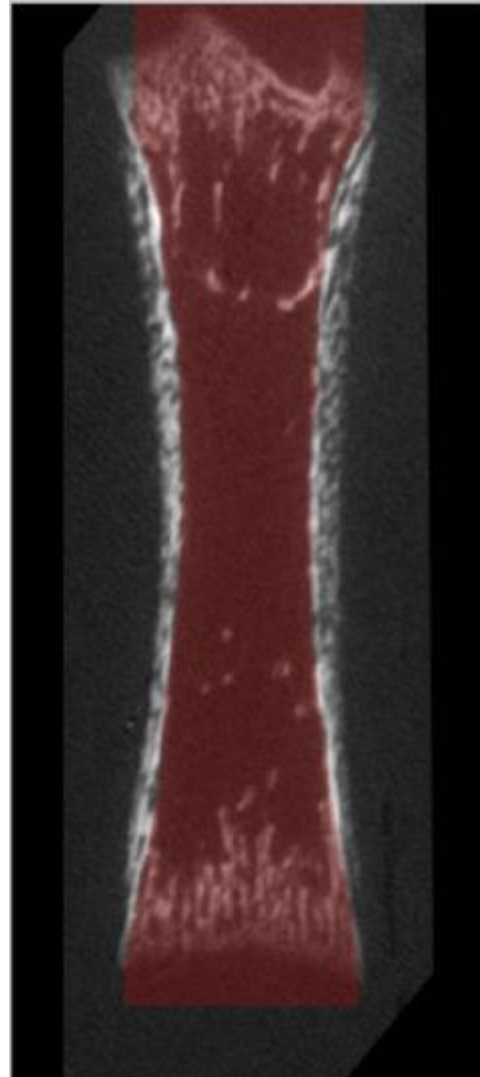
Gray scale = Bone CT slide

Semi-transparent red = Masked regions

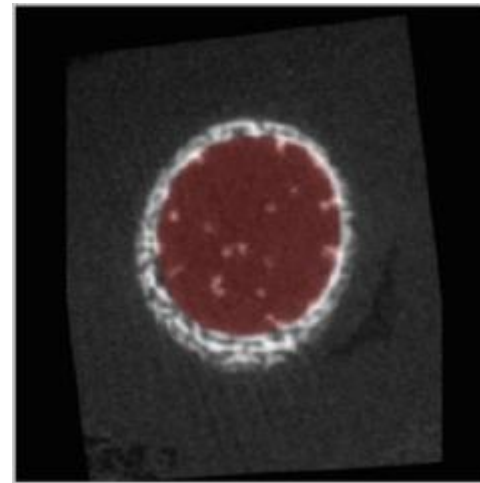
Longitudinal 1



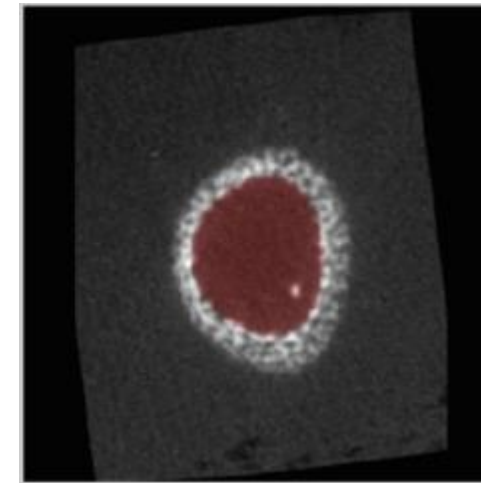
Longitudinal 2



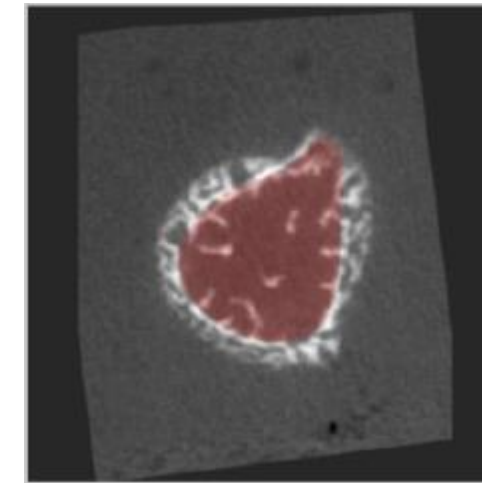
Transverse 1



Transverse 2



Transverse 3



Femur - P6

Gray scale = Bone CT slide

Semi-transparent red = Masked regions