

Postsurgical left anterior hemiblock and right bundle-branch block¹

John W. Downing, Jr.,² Samuel Kaplan, and Kevin E. Bove

From the Departments of Pediatrics and Pathology, Children's Hospital Research Foundation, College of Medicine, University of Cincinnati, Cincinnati, Ohio, U.S.A.

Combined left anterior hemiblock and right bundle-branch block after surgical closure of ventricular septal defects and correction of tetralogy of Fallot is evaluated in 240 patients. It was found that 7 of 109 patients or 6.4 per cent with ventricular septal defect and 14 of 131 patients or 10.7 per cent with tetralogy of Fallot developed this combination of conduction disturbances as a consequence of intracardiac operations. All patients are alive and completely asymptomatic 1 to 10 years after operation. No serious side effects have occurred except for transient heart block in the immediate postoperative period in 2 patients. The immediate prognosis is good for combined left anterior hemiblock and right bundle-branch block in children after surgical correction of these two types of congenital cardiac defects. The ultimate outlook, however, can be determined only after many more years of observation.

The prognostic importance of combined left axis deviation and right bundle-branch block has been emphasized recently (Watt and Pruitt, 1969; Lasser, Haft, and Friedberg, 1968). Kulbertus, Coyne, and Hallidie-Smith (1969) documented the occurrence of left axis deviation with right bundle-branch block before and after surgical closure of ventricular septal defect. They suggested that the prognosis of these conduction abnormalities might be unfavourable. The present report concerns our experience with this combination of conduction disturbances after closure of ventricular septal defects and after total correction of cyanotic tetralogy of Fallot.

Material and methods

One hundred and nine patients with isolated ventricular septal defects who underwent surgical closure and 131 patients who had total correction of tetralogy of Fallot were studied for the occurrence of combined left axis deviation and right bundle-branch block postoperatively. Their ages ranged from 2 to 18 years. Cases with preoperative evidence of left axis deviation or right bundle-branch block were excluded. Thus, patients who had partial or complete atrioventricular canals or

ventricular septal defects of the atrioventricular canal type were not included in this study. Electrocardiograms were available before and serially after the operation in all patients. In 10 patients preoperative vectorcardiograms were available, and postoperative vectorcardiograms were available on all except one patient. The Frank system was used for recording the vectorcardiograms.

Left axis deviation was considered to be present if the frontal plane axis was less than 0°. Since we were dealing with the paediatric age group, we modified the criteria of Grant (1956) and followed more closely those of Guntheroth (1965) who considers a frontal plane axis of less than 0° in children, to be left axis deviation. Right bundle-branch block was present when the duration of the QRS was 0.10 sec or longer and when a prominent R prime of 0.04 sec or more was present in the right precordial leads. No separation was made between complete and incomplete right bundle-branch block.

The clinical spectrum of the patients with ventricular septal defect varied widely (Table 1). Three children had congestive cardiac failure during the first year of life because of large defects which, just before surgical correction, were associated with severe pulmonary hypertension and large pulmonary blood flows. Three other patients had moderate to large pulmonary blood flows with normal pulmonary arterial pressures. The remaining child had moderate hyperkinetic pulmonary hypertension. None of the patients had pulmonary arterial banding during infancy, and closure of the defect was undertaken between the ages of 3 and 8 years. The defect was approached via a right ventriculotomy in 6 patients. In one the right atrium was opened and the ven-

Received 5 April 1971.

¹ Supported in part by a grant from the National Heart Institute, United States Public Health Service.

² Present address: Department of Pediatrics, Howard University, Freedmen's Hospital, Washington, D.C., U.S.A.

TABLE 1 *Clinical features of patients with ventricular septal defects*

Case No.	Congestive cardiac failure in infancy	Preoperative findings		Age and weight at operation	Surgical features			Follow-up	
		Pulm. artery pressure (mmHg)	Qp/Qs†		Cardiotomy	Location of VSD	Size of VSD (mm)	Years postop.	Clinical condition
1	Yes	80/26 (50)*	2.4:1	4 yr 9.3 kg	R. ventriculotomy	Typical membranous	12 × 6 (patched)	7	Asymptomatic
2	No	23/7 (11)	1.7:1	6 yr 21.4 kg	R. ventriculotomy	Anterior membranous	6 × 6 (patched)	2	Asymptomatic
3	No	27/10 (15)	3.5:1	6 yr 19.5 kg	R. atriotomy	Typical membranous	15 × 12 (patched)	1½	Asymptomatic
4	No	25/8 (15)	2.6:1	8 yr 29.5 kg	R. ventriculotomy	Typical membranous	9 × 7 (patched)	2	Asymptomatic
5	No	46/10 (19)	2.9:1	7 yr 20.7 kg	R. ventriculotomy	2 membranous	6 × 6 and 4 × 4 (sutured)	6	Asymptomatic
6	Yes	80/21 (45)	2.8:1	3 yr 9.1 kg	R. ventriculotomy	Typical membranous	12 × 10 (patched)		
		49/10 (19)	2.3:1	6 yr 19 kg	R. ventriculotomy	Recurrence in posterior portion	12 × 4 (patched)	3	Asymptomatic
7	Yes	80/36 (52)	2.1:1	4 yr 15 kg	R. ventriculotomy	Typical membranous	18 × 6 (patched)	5	Asymptomatic

* Mean pressure.

† Qp/Qs = pulmonary systemic flow ratio.

tricular septal defect was patched after the tricuspid valve was retracted. Inadequate closure of the defect necessitated a second operation in one boy (Case 6, Table 1). Left anterior hemiblock and right bundle-branch block were present after the first operation and did not complicate the second procedure. All the ventricular septal defects were infracristal, involved the membranous septum, were situated immediately below the aortic valve and were partially hidden by the medial leaflet

of the tricuspid valve. In one instance (Case 2, Table 1) the defect was somewhat more anterior than usual but otherwise had the characteristics described above.

The patients with tetralogy of Fallot all had an underdeveloped right ventricular infundibulum which resulted in severe right ventricular outflow obstruction. The ventricular septal defect was large in all patients and was situated just below the aortic valve. The right ventricular pressure

TABLE 2 *Clinical features of patients with tetralogy of Fallot*

Case No.	Palliative surgery		Corrective surgery			Follow-up	
	Age	Type	Age (yr)	Infundibular resection	Pericardial patch	Years postop.	Clinical condition
8			10	Yes	Outflow	2.5	Asymptomatic
9			3	Yes	Outflow	10	Asymptomatic
10			6	Yes	None	3	Asymptomatic
11			6	Yes	None	4	Asymptomatic
12			10	Yes	None	7	Asymptomatic
13	3 mth	Potts	17	Yes	Outflow	2	Asymptomatic
14	15 mth	Blalock	6	Yes	Outflow + PA	3	Complete heart block for 24 hr postop., now asymptomatic
15	5 yr	Blalock	13	Yes	Outflow + PA	3	Asymptomatic
16	3 yr	Potts	18	Yes	Outflow	2	Complete heart block for 21 days postop., now asymptomatic
17	3 yr	Blalock	6	Yes	Outflow + PA	2.75	Asymptomatic
18			8	Yes	None	4	Asymptomatic
19			9	Yes	None	2	Asymptomatic
20	2 yr	Blalock	14	Yes	Outflow	3	Asymptomatic
	10 yr	Blalock					
21	22 mth	Potts	8	Yes	Outflow	2	Asymptomatic

PA = pulmonary artery.

was systemic in all instances and the shunt across the ventricular septal defect was bidirectional or exclusively from right to left. The aorta arose in part from the right ventricle, but fibrous continuity of the mitral and aortic valves was maintained. Some of the clinical features of these patients are shown in Table 2. Seven patients underwent palliative aortic-pulmonary shunts before corrective surgery. The latter was undertaken between the ages of 3 and 18 years. At corrective surgery previous Blalock and Potts' shunts were obliterated. All patients had a right ventriculotomy and the ventricular septal defect was closed with a Teflon patch. Infundibular resection was required in all instances. The right ventricular outflow was reconstructed with a pericardial patch in 9 patients. In 3 of these patients (Cases 14, 15, and 17, Table 2), the pulmonary valve ring was divided so that the pericardial patch extended from the right ventricular outflow to near the bifurcation of the pulmonary artery.

Results

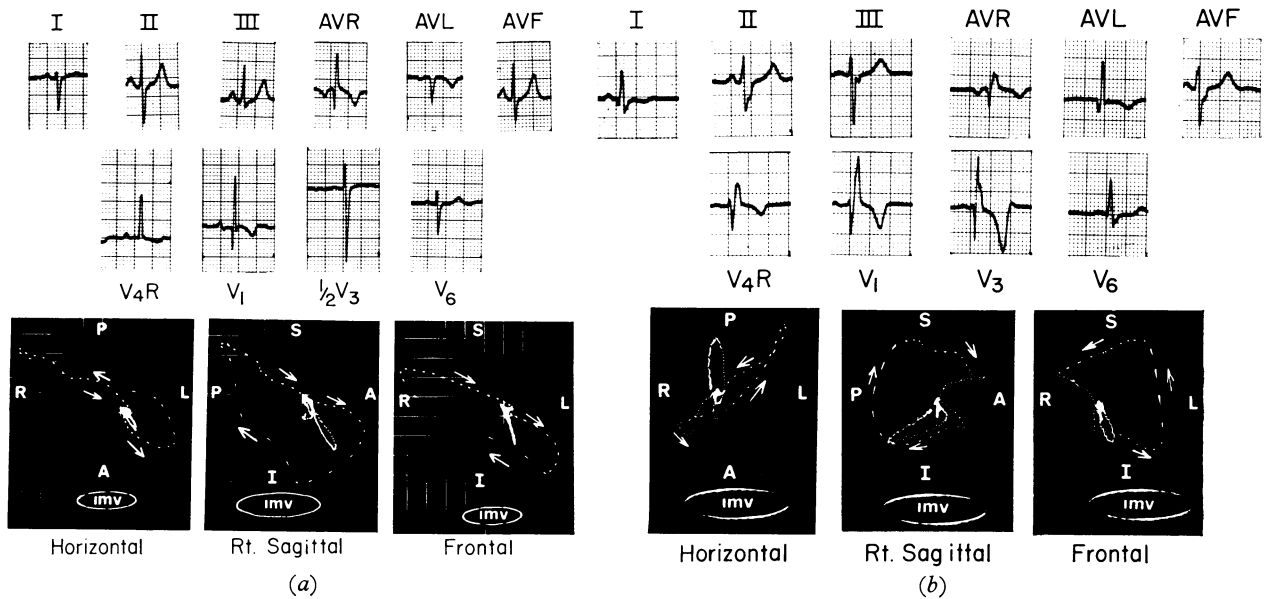
Of the total of 240 patients studied, 21 met the electrocardiographic criteria to be included in this report. Fourteen had tetralogy of Fallot, and 7 had isolated ventricular septal defect. Thus, 14 of 131 patients or 10.7 per cent with tetralogy of Fallot and 7 of 109 patients or 6.4 per cent with ventricular septal defect who had normal or right axis developed left axis deviation with associated right bundle-branch block postoperatively.

All of the 131 patients with tetralogy of Fallot developed right bundle-branch block after operation, but only 14 had left axis deviation. Among these 14 patients, 12 (86%) showed a superior frontal QRS loop postoperatively: 7 of these frontal loops were counterclockwise, 1 was clockwise, and 4 had a figure-of-eight pattern. All showed significant terminal slowing of the inscription of the loop (0.04 to 0.086 sec). Of the 7 patients with ventricular septal defects, 6 had significant terminal slowing as shown by the vectorcardiograms (0.026 to 0.076 sec) and 1 showed only preterminal slowing. Only 2 patients with ventricular septal defect demonstrated counterclockwise mostly superior loops. In the other 5 patients the loops were not predominantly superior.

A trivectorial analysis of the vectorcardiograms was undertaken to detect left axis deviation. From the frontal plane vectorcardiogram, the second (40 millisecond) vector was found to be of importance in determining left axis deviation regardless of the major QRS vector. Table 3 shows the trivectorial analysis of the patients with ventricular septal defect and shows the left superior orientation of the second vector.

The pre- and postoperative PR intervals were also measured. When compared with the preoperative electrocardiograms, the post-

FIG. 1 *Electrocardiogram and vectorcardiogram (Frank) of Case 8 with tetralogy of Fallot. (a) Preoperative, showing right axis deviation, right ventricular hypertrophy, and a clockwise frontal loop. (b) Postoperative, showing left axis deviation, right bundle-branch block, and a counterclockwise superior frontal loop.*



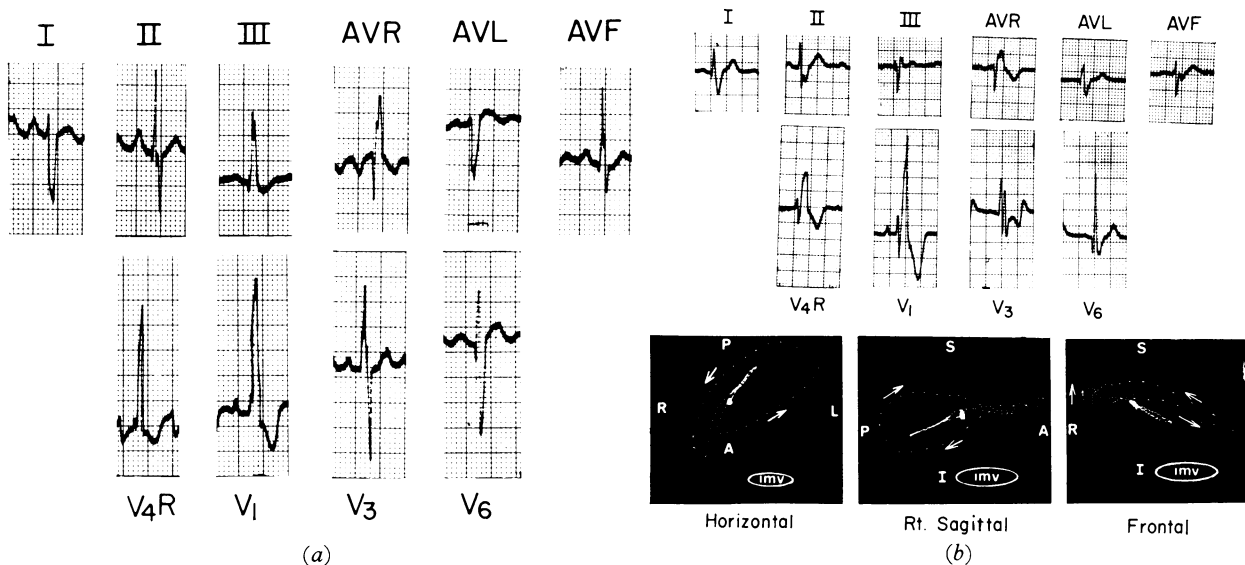


FIG. 2 Electrocardiograms of Case 6 with isolated ventricular septal defect and severe pulmonary hypertension. (a) Preoperative, showing right axis deviation, right ventricular hypertrophy, and possible associated right ventricular conduction defect. (b) Postoperative, electrocardiogram and vectorcardiogram (Frank) showing the change of frontal plane axis to the left, the development of advanced right bundle-branch block, and a figure-of-eight, mostly superior, frontal loop.

operative PR intervals were prolonged by 0.02 to 0.04 sec in 10 patients, shortened in 4, and unchanged in 8. In all instances the PR interval was corrected for heart rate.

Fig. 1 and 2 show pre- and postoperative electrocardiograms and vectorcardiograms of 2 patients. Fig. 3-6 and Table 3 summarize the pertinent electrocardiographic and vectorcardiographic features of the 21 patients. All of these have been followed for 1 to 10 years after operation and Tables 1 and 2 summarize their clinical course.

Six patients underwent cardiac catheterization 1 to 4 years postoperatively (Table 4). Four of these patients had tetralogy of Fallot and 2 had ventricular septal defects. The residual right ventricular outflow gradient varied from 3 to 38 mmHg in the tetralogy group, and in one of these patients a minute ventricular septal defect was shown only by left ventriculography. In 3 patients (Cases 14, 16, and 17) the right ventricular first derivative (rate of rise of pressure) was determined and found to be normal and in 2 of these (Cases 14 and 17) the left ventricular first derivative was also determined and found to be normal. Both patients with ventricular septal defect who were subjected to cardiac catheterization postoperatively had pulmonary hypertension preoperatively. In Case 1 the pulmonary arterial pressure fell from 80/26

mmHg to 35/8 mmHg four years after operation. Though the pulmonary arterial pressure fell from 80/21 mmHg to 49/10 mmHg in Case 6, evaluation of the postoperative haemodynamics is difficult since he has a residual ventricular septal defect.

Discussion

The common mechanisms for the production of right bundle-branch block in surgical repair of ventricular septal defects are injury to the right bundle during the placement of

TABLE 3 Trivectorial analysis of postoperative frontal plane vectorcardiograms of patients with ventricular septal defect (Frank system)

Case No.	Direction of major vectors		
	1st vector (20 msec)	2nd vector (40 msec)	3rd vector (60 msec)
1	-7	-23	+180°
2	+30	-20	-177°
3	+30	-18	+162°
4	+70	-4	-154°
5	+20	-4	-170°
6	-45	-40	-151°
7	-19	+18	+151°

TABLE 4 Postoperative cardiac catheterization data

Case No.	Diagnosis	Pressures (mmHg)			Systolic gradient	Cardiac index (l./min per m ²)	Shunt ratio	dp/dt max		Comment
		RA (mean)	PA	RV				LV	RV	
10	Tetralogy of Fallot	1	22/7	24/0	3	4.0				Small ventricular septal defect*
14	Tetralogy of Fallot	1	21/8	42/0	21	5.2	None	1155	312	
16	Tetralogy of Fallot	8	24/13	55/7	31	4.5	None		303	
17	Tetralogy of Fallot	6	16/7	54/2	38	3.3	None	1000	350	
1	Ventricular septal defect	9	35/8	43/2		5.8	None			Residual ventricular septal defect
6	Ventricular septal defect	-3	49/10	49/0		3.5	2.7:1			

RA = right atrium; PA = pulmonary artery; RV = right ventricle.

Systolic gradient in mmHg.

dp/dt max in mmHg per sec.

* Ventricular septal defect demonstrable only by left ventriculography.

sutures around the edges of the defect, and right ventriculotomy (Daoud *et al.*, 1964). Myomectomy in patients undergoing correction of tetralogy of Fallot also contributes to the development of this conduction disturbance. The location of the right bundle along the posterior-inferior aspect of infracristal ventricular septal defects and in tetralogy of Fallot has been confirmed by several investigators (Keith, 1909; Yater, Lyon, and McNabb, 1933; Lev, 1960, 1959; Kirklin *et al.*, 1957; Titus *et al.*, 1963b; Feldt, DuShane, and Titus, 1966). In some instances of muscular septal defects, however, the bundle may course along the posterior or anterior portion of the defect. In any case it appears that the bundle is maintained as close to its natural course as possible, being displaced only by the septal defect. In small, high posterior defects the right bundle may not be intimately related to the rim of the defect.

The anatomy of the atrioventricular bundle and of the left bundle-branch has been clarified by the work of Lev (1968), Hudson (1965), Truex and Bishof (1958), Titus, Daugherty, and Edwards (1963a), and Widran and Lev (1951). The bundle of His normally traverses the posterior region of the pars membranacea, and after reaching the summit of the muscular septum divides into a discrete right bundle-branch and a radiating left bundle-branch. The fan-like ramifications of the left bundle extend over the left ventricular septal surface and may be further divided into anterior or superior and posterior or inferior divisions. The ramifying fascicles of the left bundle invariably occupy the posterior and inferior margins of high ventricular septal defects. In cases of isolated ventricular septal defect and tetralogy of Fallot studied by Lev (1960 and 1959), a tendency for the

FIG. 3 Effect of surgical repair on QRS axis. TOF, tetralogy of Fallot; VSD, ventricular septal defect. The frontal plane axis has changed from right or normal to left axis deviation postoperatively.

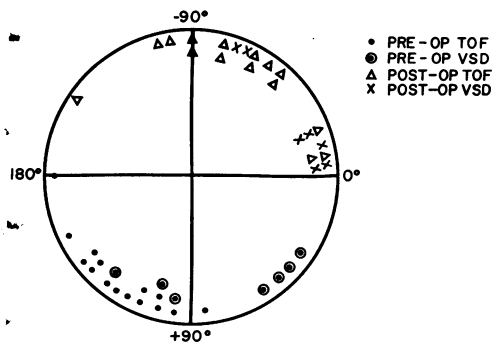
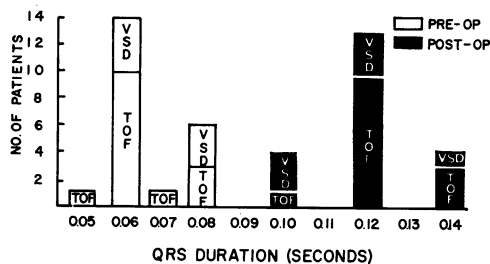


FIG. 4 Effect of surgical repair on scalar QRS duration. TOF, tetralogy of Fallot; VSD, ventricular septal defect. The postoperative QRS duration of the scalar electrocardiogram has much increased compared to the preoperative state in both TOF and VSD. This increase was present at the time of hospital discharge and was unchanged in serial tracings.



bundle of His to lie in close proximity to the inferior margin of the defect was observed in the latter only. This increases the liability to heart block stemming from injury to the atrioventricular bundle during repair of tetralogy of Fallot (Fryda, Kaplan, and Helmsworth, 1971).

It is our hypothesis that selective injury to the anterior fascicles of the left bundle-branch during placement of buttressed sutures in the repair of ventricular septal defects may produce left anterior (superior) hemiblock and thus left axis deviation. This mechanism has been confirmed experimentally by Watt and Pruitt (1969), and Watt *et al.* (1968) in primate hearts. In most ventricular septal defects a significant portion of the left bundle-branch is not intimately related to the defect. This may in part be the explanation for the fact that the majority of patients do not develop alteration of the electrical axis after surgical repair. In a histological study of hearts with recently repaired subaortic ventricular defects, Titus *et al.* (1963b) found significant amounts of haemorrhage in and around the left as well as right bundle-branches. It is the occurrence and resolution of haemorrhage and oedema around the anterior division of the left bundle which best accounts for the occasional transient left axis deviation that occurs after repair of ventricular septal defects.

It was of interest to compare the postoperative vectorcardiograms from patients with tetralogy of Fallot and those with isolated ventricular septal defect. As detailed under 'Results' a superior frontal loop was found in 86 per cent of the patients with tetralogy of Fallot. Of this number, a counterclockwise loop was seen in the majority while others had a figure-of-eight horizontal relatively superior frontal loop. On the other hand, only 2 of the patients with isolated ventricular septal defect had mostly superior counterclockwise frontal loops. Instead, a horizontal figure-of-eight loop was inscribed. Terminal slowing, pre-terminal slowing, or both were noted in all of the vectorcardiograms (Fig. 6). These findings suggest that postoperative conduction disturbance in some of the patients with tetralogy of Fallot closely resembles that seen in unoperated atrioventricular canal defects (Rosenbaum *et al.*, 1970). Because this pattern was not seen in the majority of patients who had repair of isolated ventricular septal defects, we suspect that the additional surgical manipulation involved in total repair of Fallot's tetralogy may have resulted in more trauma to the anterior division of the left bundle-branch. The tendency cited above for the bundle of His and a larger proportion of the

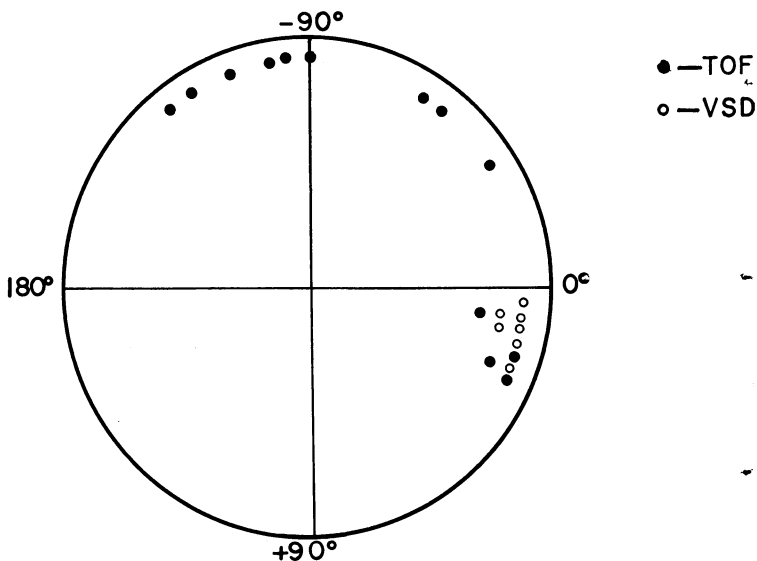
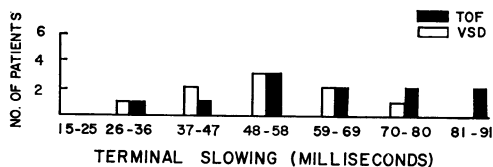


FIG. 5 Postoperative vectorcardiographic maximum QRS axis (Frank system). TOF, tetralogy of Fallot; VSD, ventricular septal defect. The postoperative vectorcardiograms show a difference in the frontal plane maximum QRS vector of patients with TOF and VSD. The more superior orientation is seen more frequently in TOF patients.

left bundle-branches to be in greater jeopardy during a corrective procedure for tetralogy of Fallot than in correction of isolated ventricular septal defect may also have been a factor. It is of interest that the postoperative scalar tracings in patients with ventricular septal defects demonstrated left axis deviation, but the major axes of the accompanying vectorcardiograms were not superior. Instead, they were horizontal and leftward. When com-

FIG. 6 Postoperative terminal QRS slowing. TOF, tetralogy of Fallot; VSD, ventricular septal defect. Analysis of the postoperative Frank vectorcardiograms showed terminal slowing in patients with TOF and VSD. The more prolonged slowing tended to be in TOF patients.



pared with preoperative vectorcardiograms, however, there had been an obvious change of axis to the left.

Our experience indicates that the immediate prognosis of left anterior hemiblock with associated right bundle-branch block after ventricular septal defect closure or correction of tetralogy of Fallot is good. No patient has developed permanent complete heart block though 2 patients had transient episodes of heart block in the immediate postoperative period. No deaths have occurred. All patients are asymptomatic and active physically. They are seen at regular intervals in the cardiac clinic, and good follow-up has been maintained from 1 to 10 years after operation. Six patients underwent cardiac catheterization after operation. During left ventricular catheterization, these patients are in danger of developing complete heart block since complete left bundle-branch block may be induced by this procedure. A pacing catheter in the right ventricle should be available for treatment of this complication. Two of our patients, however, had left heart catheterization and selective left ventriculography without complications.

It is likely that cardiac catheterization in the other patients would yield similar results, as shown in Table 4, since they lead normal active lives, are asymptomatic, and clinical and radiographic signs indicate a good haemodynamic result. Our experience with this group of patients seems to indicate that postoperative right bundle-branch block with associated left anterior hemiblock does not carry a grave prognosis in children. However, since the sudden onset of complete heart block is unpredictable in these patients, the long-term prognosis must be guarded (Kulbertus and Collignon, 1969). This is exemplified by one of our patients (who will be reported elsewhere) who died suddenly 11 years after operation for a ventricular septal defect. This patient was not included in our present report since he had left axis deviation before operation. None of the patients in our study had known endocardial cushion defects. In this respect this study differs from the report of Kulbertus *et al.* (1969) who did include such patients. It is known that these patients are at a higher risk for the development of complete heart block after surgical repair of their defects. Perhaps the ultimate prognosis of our patients will not be determined until they reach the age at which sclerotic changes in the fibrous skeleton of the heart occur. It is not known whether surgically induced right bundle-branch block and associated left anterior hemiblock carry the same ominous

outlook as in those patients in whom these changes have occurred secondary to idiopathic sclerotic alteration of the conduction system (Davies, 1967).

We appreciate the helpful comments of Drs. Te-chuan Chou and Ralph C. Scott.

References

- Daoud, G., Kaplan, S., Benzing, G., and Gallaher, M. E. (1964). Auscultatory findings of pure infundibular stenosis. *American Journal of Diseases of Children*, **108**, 73.
- Davies, M. J. (1967). A histological study of the conduction system in complete heart block. *Journal of Pathology and Bacteriology*, **94**, 351.
- Feldt, R. H., DuShane, J. W., and Titus, J. L. (1966). The anatomy of the atrioventricular conduction system in ventricular septal defect and tetralogy of Fallot: correlations with the electrocardiogram and vectorcardiogram. *Circulation*, **34**, 774.
- Fryda, R. J., Kaplan, S., and Helmsworth, J. A. (1971). Postoperative complete heart block in children. *British Heart Journal*, **33**, 456.
- Grant, R. P. (1956). Left axis deviation: an electrocardiographic-pathologic correlation study. *Circulation*, **14**, 233.
- Guntheroth, W. G. (1965). *Paediatric Electrocardiography*. W. B. Saunders, Philadelphia.
- Hudson, R. E. B. (1965). *Cardiovascular Pathology*, Vol. I. Edward Arnold, London.
- Keith, A. (1909). Malformations of the heart. *Lancet*, **2**, 519.
- Kirklin, J. W., Harshbarger, H. G., Donald, D. E., and Edwards, J. E. (1957). Surgical correction of ventricular septal defect: anatomic and technical considerations. *Journal of Thoracic Surgery*, **33**, 45.
- Kulbertus, H., and Collignon, P. (1969). Association of right bundle-branch block with left superior or inferior intraventricular block; its relation to complete heart block and Adams-Stokes syndrome. *British Heart Journal*, **31**, 435.
- Kulbertus, H. E., Coyne, J. J., and Hallidie-Smith, K. A. (1969). Conduction disturbances before and after surgical closure of ventricular septal defect. *American Heart Journal*, **77**, 123.
- Lasser, R. P., Haft, J. I., and Friedberg, C. K. (1968). Relationship of right bundle-branch block and marked left axis deviation (with left parietal or perinfarction block) to complete heart block and syncope. *Circulation*, **37**, 429.
- Lev, M. (1959). The architecture of the conduction system in congenital heart disease. II. Tetralogy of Fallot. *Archives of Pathology*, **67**, 572.
- Lev, M. (1960). The architecture of the conduction system in congenital heart disease. III. Ventricular septal defect. *Archives of Pathology*, **70**, 529.
- Lev, M. (1968). The conduction system. In *Pathology of the Heart*, 3rd ed. Ed. by S. E. Gould. Charles C. Thomas, Springfield, Illinois.
- Rosenbaum, M. B., Corrado, G., Oliveri, R., Castellanos, A., and Elizari, M. V. (1970). Right bundle branch block with left anterior hemiblock surgically induced in tetralogy of Fallot. *American Journal of Cardiology*, **26**, 12.
- Titus, J. L., Daugherty, G. W., and Edwards, J. E. (1963a). Anatomy of the atrioventricular conduction system in ventricular septal defect. *Circulation*, **28**, 72.

- Titus, J. L., Daugherty, G. W., Kirklin, J. W., and Edwards, J. E. (1963b). Lesions of the atrioventricular conduction system after repair of ventricular septal defect: relation to heart block. *Circulation*, **28**, 82.
- Truex, R. C., and Bishof, J. K. (1958). Conduction system in human hearts with interventricular septal defects. *Journal of Thoracic Surgery*, **35**, 421.
- Watt, T. B., Jr., Freud, G. E., Durrer, D., and Pruitt, R. D. (1968). Left anterior aborization block combined with right bundle-branch block in canine and primate hearts: an electrocardiographic study. *Circulation Research*, **22**, 57.
- Watt, T. B., Jr., and Pruitt, R. D. (1969). Character, cause, and consequence of combined left axis deviation and right bundle-branch block in human electrocardiograms. *American Heart Journal*, **77**, 460.
- Widran, J., and Lev, M. (1951). The dissection of the atrioventricular node, bundle and bundle branches in the human heart. *Circulation*, **4**, 863.
- Yater, W. M., Lyon, J. A., and McNabb, P. E. (1933). Congenital heart block: review and report of the second case of complete heart block studied by serial sections through the conduction system. *Journal of the American Medical Association*, **100**, 1831.

Requests for reprints to Dr. Samuel Kaplan, Children's Hospital, Cincinnati, Ohio 45229, U.S.A.