

# Intracavitary Cardiac Neoplasms\*

## A Review of Fifteen Cases

LAURENCE P. STERNS, ROBERT S. ELIOT, RICHARD L. VARCO,  
AND JESSE E. EDWARDS

*From the Department of Pathology, The Charles T. Miller Hospital, St. Paul, Minnesota, and the Departments of Surgery, Medicine and Pathology, University of Minnesota, Minneapolis, Minnesota, U.S.A.*

In the patient suspected of having either valvular or myocardial disease, the underlying process may be a space-occupying tumour of a cardiac chamber. It is recognized that such lesions may be thrombi or tumours arising primarily within the heart or secondarily deposited as metastases. Intracavitary neoplasms may cause functional disturbances similar to those encountered in intrinsic valvular disease by interfering with valvular function. Occasionally, such tumours may invade the conduction system provoking a variety of arrhythmias and conduction disturbances, including complete heart block and bundle-branch block.

When the presence of such tumours is recognized, some patients may either be cured or improved by surgical or medical means. In order to review the pathological and clinical manifestations of intracavitary neoplasms of the heart, it is the purpose of this communication to summarize the features in 15 patients with such tumours. A specimen from each is in the pathological collection of the Cardiovascular Registry of The Charles T. Miller Hospital or of the University of Minnesota Hospitals. Emphasis will be placed upon those characteristics that either led to a clinical diagnosis or appeared to be of major clinical significance. In 11 of the patients the cardiac tumours were primary, whereas in 4 the tumours were metastatic. The 15 intracavitary cardiac tumours are divided into 3 categories as follows: (1) primary malignant (2); (2) primary benign (9); and (3) metastatic tumours (4).

### OBSERVATIONS

#### *Primary Malignant Cardiac Tumours*

In the 2 patients with primary malignant tumours of the heart with intracavitary extension, symptoms

of cardiac disease began at the age of 26 years and 60 years, respectively. In each instance, the tumour proved fatal within a year of the appearance of symptoms. In neither case was the correct diagnosis made during life.

*Case 1\**. The patient, a woman, first became ill at the age of 26 years. The initial symptoms were those of fatigue, thoracic pain, and dyspnoea. These symptoms progressed in severity as signs of pulmonary hypertension, right ventricular failure, and tricuspid regurgitation developed. The electrocardiogram showed short P-R intervals and prolonged QRS complexes suggesting the Wolff-Parkinson-White syndrome. Death following a clinical picture of intractable left and right-sided cardiac failure occurred one year after the onset of symptoms. At no time had the patient been considered well enough to permit physiological or angio-cardiographic studies.

At necropsy, the left atrial cavity was nearly filled with a tumour that had originated from the mid-portion of the atrial septum and had extended both through the orifice of the mitral valve and into the orifices of both right pulmonary veins and that of the left lower pulmonary vein (Fig. 1).

Histological examination of the mass identified it as a malignant mesenchymoma (Fig. 2).

*Case 2†*. This 60-year-old patient, when first examined one year before death, was complaining of dyspnoea. The results of the initial examination were suggestive of Ebstein's malformation of the tricuspid valve with a transatrial right-to-left shunt. One year later the dyspnoea had increased in severity and was accompanied by cyanosis and evidence of loss of weight. Cardiomegaly was present. The liver was firm but not pulsatile, and the spleen was enlarged so as to extend to a level 6 cm. below the left costal margin. The electrocardiogram showed atrial fibrillation and complete right bundle-branch block.

Received April 5, 1965.

\* This study was supported by Research Grant HE-5694 and Training Grant 5 T1 HE 5570 of the National Heart Institute, United States Public Health Service.

\* Case reported by Stemmerman, G. N., Kim, P. M., and Berk, M. C. (1956). *J. Lancet*, 85, 213.

† We are indebted to Dr. Carl S. Alexander for the use of this material.

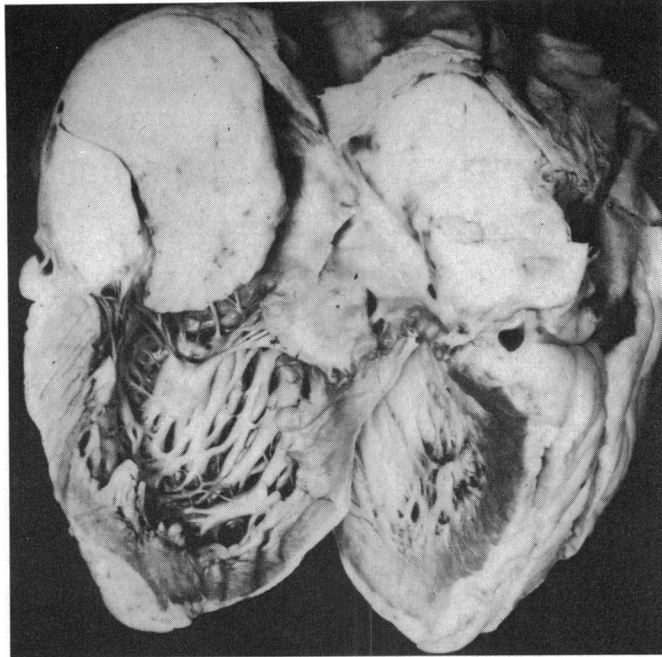


FIG. 1.—Case 1. Left atrium and left ventricle. A malignant mesenchymal tumour which had originated in the atrial septum involves a considerable portion of the left atrial cavity. Orifices of the pulmonary veins are also occluded by the tumour.

The state of the patient gradually deteriorated, being characterized by increasing dyspnoea, cyanosis, and finally death.

At necropsy, multiple tumours were attached to the right ventricular wall and protruded into the cavity. The largest partially obstructed the right ventricular out-flow tract (Fig 3 A). Focally, the right ventricular endocardium was thickened by non-tumour-containing fibrous tissue. Such tissue caused the septal leaflet of the tricuspid valve to be adherent to the ventricular septum.

Histological studies identified this tumour as a rhabdomyosarcoma (Fig. 3B).

*Comment on Cases 1 and 2.* The first case of primary malignant cardiac tumour involved a young woman who presented with a bizarre arrhythmia and congestive cardiac failure. Although no explanation for the arrhythmia is immediately apparent in this patient, arrhythmias occurring in instances of cardiac tumours have been mentioned by others (Gilchrist and Millar, 1936; Lisa, Hirschhorn, and Hart, 1941; Whorton, 1949).

In the second case, involving an older patient, Ebstein's malformation of the tricuspid valve was suspected. Possibly, this was derived from the fact that the septal leaflet of the tricuspid valve was fused to the ventricular septum by fibrous tissue.

The endocardial fibrous tissue was either incidental to the tumour or may have been related to it as a reaction to some unidentified substance produced by the tumour.

#### *Primary Benign Cardiac Tumours*

In 8 of the 9 patients included in this group the tumours were myxomas of the left atrium. Six of these were correctly diagnosed or suspected during life and removed surgically in 4 cases. In one in whom the correct diagnosis was suspected, however, the patient expired from occlusion of the mitral valve before he could be operated upon. In the ninth patient the benign intracardiac tumour was a myxoma of the right atrium.

The patients in this group ranged in age from 12 to 68 years, about half being in the fourth and fifth decades of life.

*Case 3.* At 36 years of age, this female patient noticed a progressive decrease in tolerance to exercise over several months. Physical examination revealed a high-pitched holosystolic murmur, best heard at the apex and radiating to the left sternal border and left axilla. A palpable thrill was noted in the fourth left intercostal space at the mid-clavicular line. The electrocardiogram

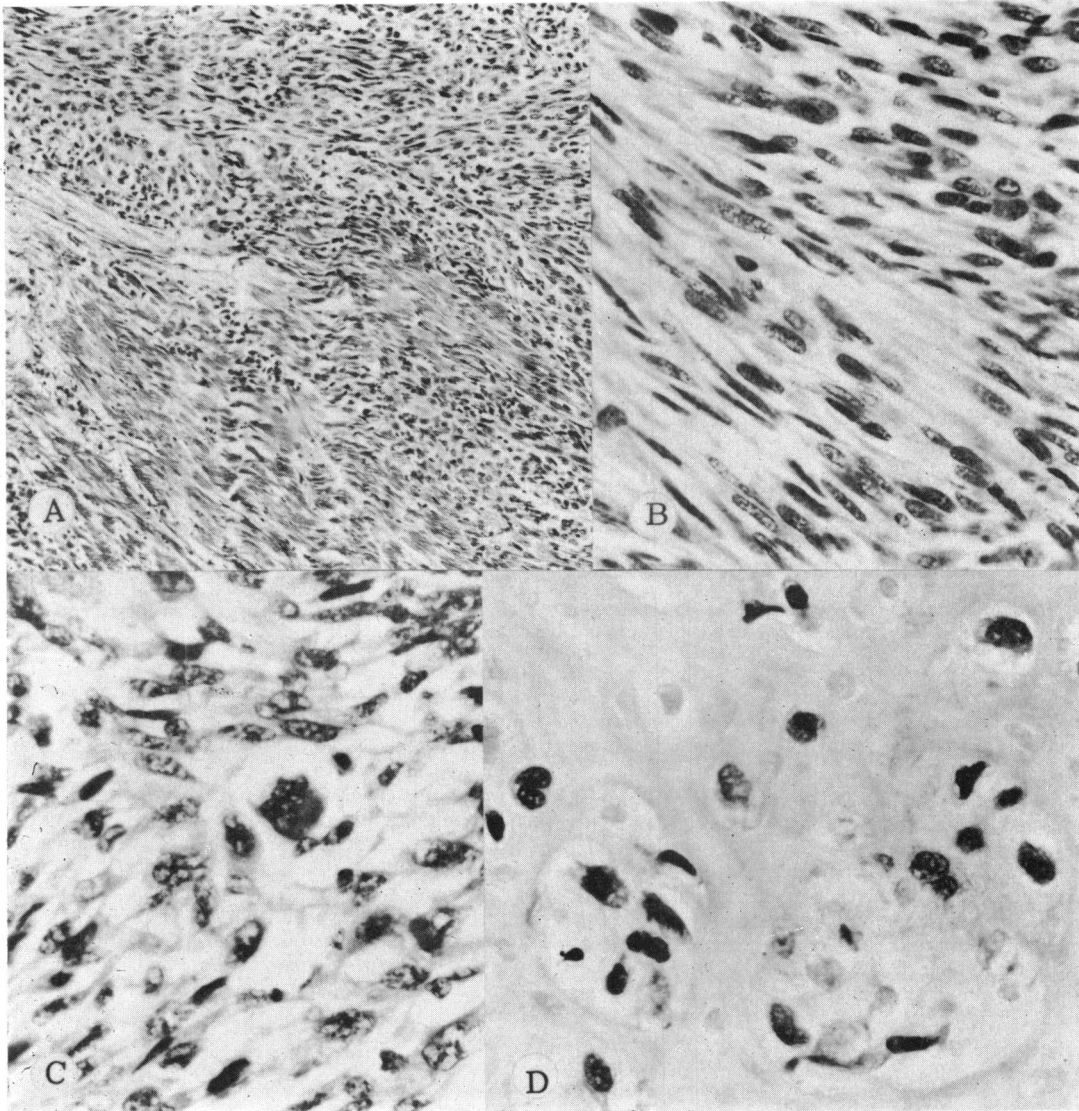


FIG. 2.—Case 1. Photomicrographs of mixed mesenchymal tumour. (A) Low-power view showing involvement of cardiac muscle bundles by interlacing bundles of malignant tumour. (H. and E.  $\times 125$ .) (B) Segment of a fibroblastic-like portion of the tumour. (H. and E.  $\times 400$ .) (C) A relatively anaplastic area of the tumour containing a giant cell. (H. and E.  $\times 40$ .) (D) An area of the tumour forming cartilage. (H. and E.  $\times 400$ .)

suggested right atrial enlargement and right bundle-branch block. Special studies included a left ventriculogram and retrograde aortogram. The left ventriculogram, which showed regurgitation of contrast material into the left atrium, indicated a space-occupying mass of the left atrium.

At operation, a myxoma, its broad base attached to the atrial septum at the region of the interatrial ostium

secundum, was successfully removed from the left atrium.

*Case 4.* A 51-year-old man had progressive dyspnoea, wheezing, and orthopnoea for 2 years. A murmur of mitral incompetence was noted. The electrocardiogram revealed signs of biatrial enlargement and right bundle-branch block.

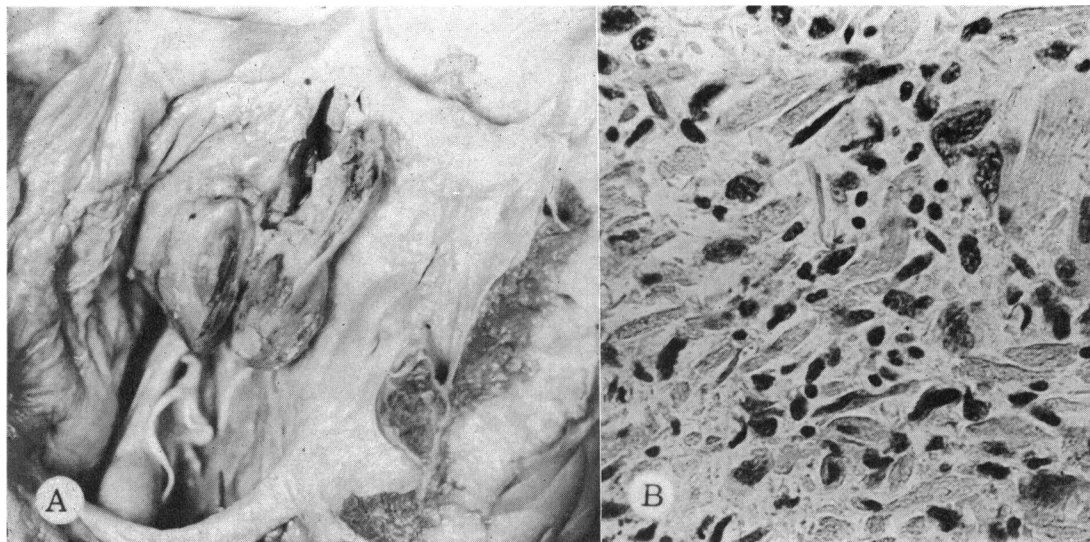


FIG. 3.—Case 2. (A) Outflow portion of right ventricle and pulmonary valve. Immediately beneath the pulmonary valve is a mass of tumour which, histologically, proved to be a rhabdomyosarcoma. Endocardial thickening of the right ventricle is also present. (B) Photomicrograph of a representative section of the right ventricular tumour shows features of a rhabdomyosarcoma. (H. and E.  $\times 400$ .)

The clinical impression was either mitral stenosis or left atrial myxoma. The latter diagnosis was confirmed at operation when a pedunculated myxoma was removed from the left atrium.

*Case 5.* This 52-year-old woman gave a history of a questionable "heart attack" 2 years earlier. There were no symptoms of cardiac failure. Physical examination revealed only a blowing pansystolic murmur at the apex and a very accentuated second pulmonary sound.

The electrocardiogram showed signs of left atrial enlargement and atrial flutter, and "incomplete" right bundle-branch block. A left ventriculogram revealed signs of mitral insufficiency and a space-occupying mass of the left atrium. The latter, a myxoma, was then successfully removed.

After operation, the patient returned to good health. One year following operation, the electrocardiogram showed a normal axis and minimal signs of left atrial enlargement.

*Case 6.* This 47-year-old female patient experienced dyspnoea for 5 years and noted peripheral oedema for one year before seeking medical attention. Auscultation revealed a grade 1 apical systolic murmur, accompanied by a short grade 1-2 (on the basis of 1-4) presystolic murmur at the apex.

An electrocardiogram revealed signs only of left atrial enlargement and right ventricular hypertrophy. Based on the clinical impression that either mitral stenosis or left atrial tumour was the problem, she was operated upon. A large myxomatous mass was successfully removed from the left atrium but the patient expired 4 days after operation. Cerebral air embolism was the suspected cause of death; there was no necropsy.

*Case 7.* This 13-year-old girl manifested dyspnoea, pulmonary oedema, and transient arthralgia over a period of several months. The initial clinical impression was that of rheumatic mitral valvular disease. Radiographs revealed left atrial enlargement. The symptoms continued, complete A-V block developed, and the patient died suddenly before a definitive diagnosis was made.

Necropsy revealed a large pedunculated left atrial myxoma originating from the mid-atrial septum. The tumour extended through and occluded the mitral orifice (Fig 4A). Emboli from the friable primary tumour were found in splenic and renal arteries (Fig. 4B).

*Case 8.* This 68-year-old woman died of causes unrelated to the cardiovascular system. At necropsy, a broad-based left atrial myxoma, 3 cm. in diameter, was discovered originating from the atrial septum. Because of its small size, no apparent haemodynamic effects of the tumour had resulted. No emboli were found.

*Case 9.* A 58-year-old woman expired from complications of a recurrent malignant meningioma. The only significant cardiovascular finding was the belated development of a grade 1 (basis of 1-4) holosystolic murmur at the apex. At necropsy, a left atrial myxoma, 3 cm. in diameter, was found arising from the atrial septum below the region of the fossa ovalis.

*Case 10.* One year before death, this 42-year-old man (a specimen was submitted by Dr. Donald J. Stevenson) was first seen complaining of increasing shortness of breath. Moderate cardiomegaly was noted at this time and a diagnosis of mild congestive cardiac failure was

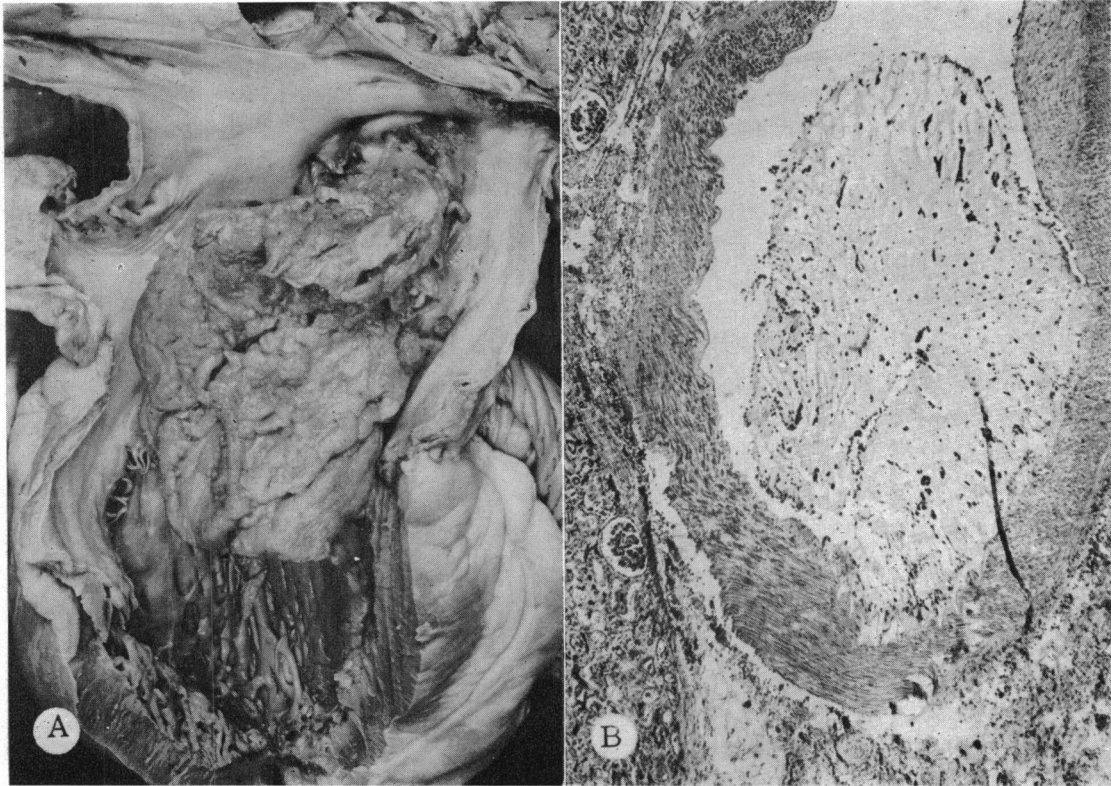


FIG. 4.—Case 7. Myxoma of left atrium. (A) Left atrium and left ventricle. A large myxoma arising from the atrial septum occupies a considerable part of the left atrial cavity and protrudes through the mitral valve. (B) Photomicrograph of an intrarenal artery shows partial occlusion by an embolus of myxomatous tissue believed to have originated in the tumour of the left atrium. (H. and E.  $\times 57$ .)

made. Dyspnoea, orthopnoea, and thoracic pain increased over the following year. When the patient was admitted to the hospital the jugular venous pressure was raised, and the liver was palpable 8 cm. below the right costal margin and was tender. A grade 2 (on the basis of 1–4) apical systolic murmur was heard, which was not constant. On certain subsequent examinations no murmurs were audible. An electrocardiogram revealed right bundle-branch block and numerous unifocal premature ventricular contractions. The clinical impression was that of left atrial disease or of mitral valvular disease.

After one week in the hospital, the patient suddenly developed massive swelling of the entire left lower extremity, followed shortly by emesis, cyanosis, and death.

At necropsy, thrombophlebitis of the left femoral vein was found, along with numerous pulmonary emboli and pulmonary oedema. Examination of the heart revealed a prominent left atrial appendage. The left atrial cavity was almost completely filled by a  $6 \times 6 \times 5$  cm. mass attached to the posterior aspect of the atrium by a

stalk 0.4 cm. in diameter. This mass was light tan to reddish-brown in colour and had numerous villous projections on its surface.

Histological examination identified this mass as a myxoma.

*Case 11\**. A 54-year-old diabetic man with Kimmelstiel-Wilson syndrome developed increased jugular pressure, peripheral oedema, and dyspnoea during the final few months of life. Examination revealed a præcordial grade 1 holosystolic murmur which increased in intensity with inspiration.

At necropsy, a pedunculated mass 7 cm. in diameter was found in the right atrium, the base being attached to the atrial septum. The lower aspect of the mass engaged the orifice of the tricuspid valve (Fig. 5).

*Comment on Cases 3–11.* In 8 of the 9 cases of atrial myxoma signs of chronic cardiac disease in the form of decreased tolerance to exercise, dyspnoea,

\* Case reported by Tiffany, F. B., Woodburn, R. L., and Edwards, J. E. (1963). *Minn. Med.*, **46**, 1141.



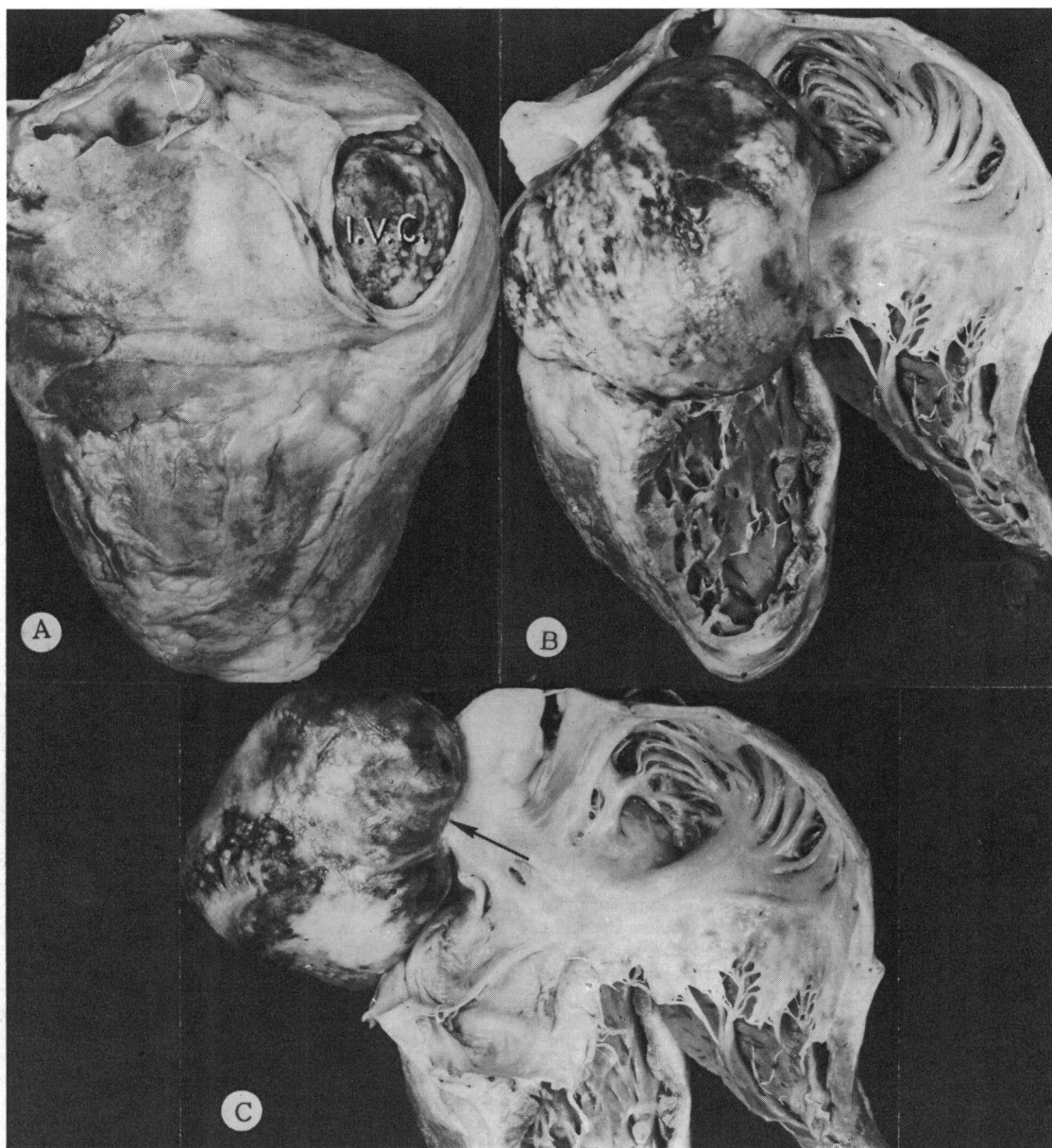


FIG. 5.—Case 11. Myxoma of right atrium. (A) Exterior of heart from behind. The orifice of the inferior vena cava (I. V. C.) is occluded by a mass within the right atrial cavity. (B) Interior of right atrium and right ventricle. The myxoma involves a considerable portion of space in the right atrial cavity and protrudes through the orifice of the tricuspid valve. (C) Right atrium and right ventricle. The myxoma has been displaced posteriorly to reveal the attachment of the tumour by a pedicle (point of arrow) to the septal wall of the atrium.

orthopnoea, and oedema were observed. This, coupled with the presence of murmurs, led to suspicion of valvular cardiac disease.

As emphasized in several early reports (Yater, 1931; Fawcett and Ward, 1939; Prichard, 1951), the appearance of such clinical patterns in the absence of a past history of acute rheumatic fever should suggest the possibility of an intracardiac neoplasm. Although observed in only one patient in this series, embolism has been considered a frequent complication of left atrial myxoma. Changes in the character of murmurs with changes in position of the body were first noted in a patient with left atrial myxoma by Pavlowsky, as mentioned by Göttel (1919). Although this may be a valuable sign, it is interesting to note that it was not observed in any of our patients. Of the 4 patients with left atrial myxoma undergoing operation (Cases 3–6) electrocardiographic findings appeared to follow a definite pattern in 3. Disturbances of conduction, as evidenced by a right bundle-branch block, were consistently present, as were signs of enlargement of one or of both atria. Of special interest was the presence of an RSR' complex in lead V1 in 2 patients (Cases 4 and 5). In the latter, this finding was no longer present one year after removal of the tumour.

In our experience about one-third of patients having mitral valvular disease exhibit an electrocardiographic pattern of RSR' in the right-sided præcordial leads. The same finding was observed in two of the patients with left atrial myxoma in our series. Thus, while this pattern is by no means specific, its presence should bring to mind the possibility of an atrial myxoma.

In our experience, left ventriculography has been useful in the diagnosis of left atrial myxomas. The value of this procedure lies in the occurrence of mitral insufficiency, either as a natural event or as a feature of premature ventricular contraction. Then, if contrast material regurgitates into the left atrium, a filling defect serves as an important diagnostic sign.

Late phase forward angiocardiograms from the pulmonary trunk are often unsatisfactory and may be risky. Transseptal punctures from the right atrium or transbronchial punctures are contraindicated on account of the inherent danger of embolism.

#### *Metastatic Tumours*

Although tumours that metastasize to the heart are recognized as being 20 to 40 times more common than primary cardiac neoplasms, most secondary tumours are epicardial in location. Only 4

examples of space-occupying metastatic tumours were found in our patients.

*Case 12.* A 33-year-old man first noted dyspnoea and hæmoptysis one year before his final hospital admission. Physical examination revealed a grade 2 (on the basis of 6) blowing diastolic murmur at the apex and a short systolic murmur in the same area. Peripheral oedema appeared shortly thereafter, and electrocardiograms indicated the presence of atrial fibrillation. The clinical course continued downward and the patient died.

At necropsy, a primary malignant tumour of the abdominal paravertebral muscles was found and metastases were present in each lung and in the heart. A large metastatic tumour involved the lumen of the right upper pulmonary vein. From the latter site, the tumour grew into the left atrial cavity where it assumed a mushroom shape and occupied a considerable extent of the space of that chamber (Fig. 6 A).

Histological examination identified the primary and secondary tumours as rhabdomyosarcoma.

*Case 13.* During the final months of his life, this 61-year-old man with an inoperable bronchogenic carcinoma experienced increasing dyspnoea. Previously normal electrocardiographic patterns gave way to non-specific changes in leads V1 and V3.

At necropsy a squamous cell carcinoma of the right lower lobe bronchus was found to extend through the pericardium to the base of the heart. It then involved the posterior walls of the cavities of both atria and also compromised the lumen of one pulmonary vein. The tumour extended into the lumen of each atrial cavity in plaque-like fashion from the corresponding posterior wall.

*Case 14.* This 63-year-old man was known to have multiple myeloma for several years. Electrocardiograms taken at yearly intervals until the time of death were significant in that they showed a progressive lengthening of the P–R interval and, terminally, non-specific changes of the S–T segments and T waves.

At necropsy, nodules of plasma cell myeloma were noted involving the walls of both right and left atria and extending into the atrial cavities. The larger masses were in the right atrium: one of these obstructed the right atrial orifice of the superior vena cava (Fig. 6 B).

*Case 15.* This 64-year-old woman underwent a radical mastectomy for carcinoma 18 months before the final admission to hospital. During this interval, progressive shortness of breath and anterior thoracic pain were experienced. Examination on admission showed the lips to be very cyanotic and the liver to be enlarged and nodular.

Radiological examination of the thorax revealed pulmonary nodules, presumed to be metastatic, as well as cardiomegaly. The patient's condition rapidly deteriorated and resulted in death.

At necropsy, 2 intracardiac metastatic masses were noted. The first was a polypoidal structure 6 × 5 × 3.5 cm. attached to the endocardium of the right atrium by a short stalk, 1.5 cm. in its greatest diameter. The surface of this mass was yellowish-pink and nodular. Arising within the lateral wall of the right ventricle a

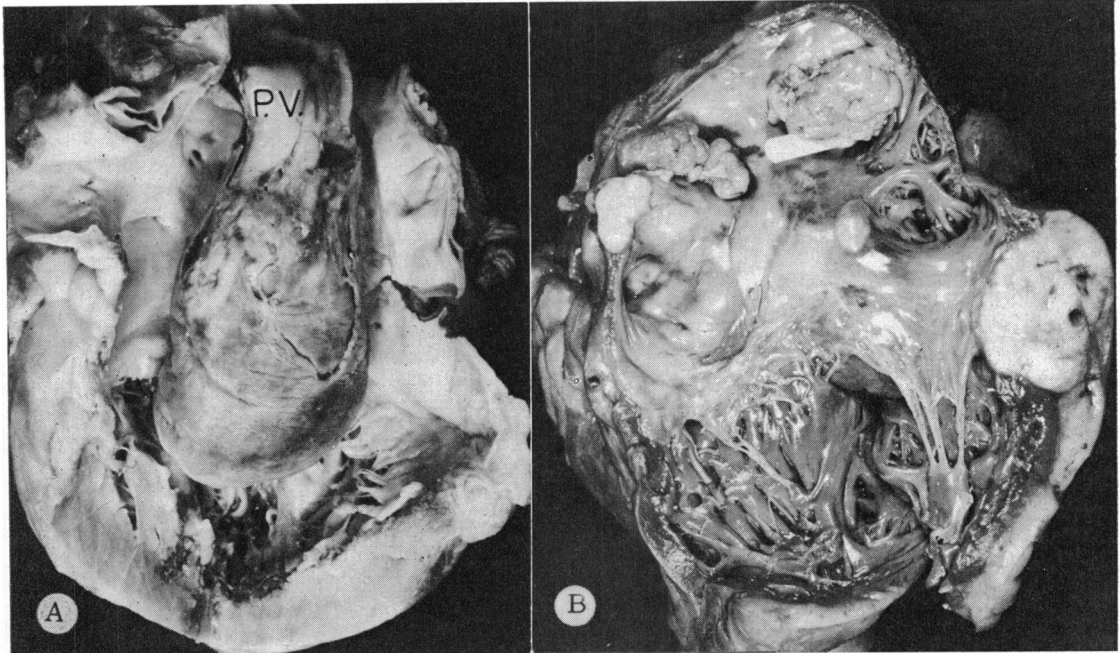


FIG. 6.—(A) Case 12. Left atrium and left ventricle. Extending through a pulmonary vein (P. V.) a pedunculated metastatic tumour of the lung occupies the left atrium and presents through the mitral valve. The tumour was a rhabdomyosarcoma which was primary in the paravertebral muscles. (B) Case 14. Multiple myeloma. Multiple nodules of metastatic myeloma involve the right atrium and the junction of the right atrium and right ventricle. At the probe a tumour mass in the right atrial wall occludes the ostium of the superior vena cava.

second metastatic mass, measuring 4 cm. in diameter, projected into the cavity of the right ventricle (Fig. 7).

*Comment on Cases 12-15.* In each of our 4 patients with intracavitary metastatic tumour, one or both atria were involved. This is in keeping with experience in general, in that when a malignant tumour involves a cavity of the heart an atrium is more commonly involved than is a ventricle.

The space-occupying effects of such tumours may be represented by peripheral oedema as noted in Case 12 and by dyspnoea as in Case 13. The obstructive effects of intracavitary malignant tumours, particularly those involving the right atrium, may give rise to a clinical picture resembling constrictive pericarditis. In the patient known to have a malignant tumour, such effects may be mistaken for the more common situation of metastatic disease of the pericardium.

#### COMMENT

In a number of the cases discussed in this review, particularly those with malignant tumours, the clinical diagnosis of an intracavitary tumour had not been made. This deficiency may result from several

factors. Among these is the fact that such tumours are sufficiently uncommon to be responsible for early elimination from the differential diagnosis on the basis of rarity. Another factor is applicable to the patient with a known malignant tumour of an extracardiac site. In such patients the clinician tends to lump all signs and symptoms under a general category of "metastatic disease" without attempting to determine the significance of specific clinical manifestations. When two conditions are associated only one of which is known to be present, as in the case of Kimmelstiel-Wilson syndrome and right atrial myxoma, abnormal signs may be interpreted as a manifestation of the better recognized condition. Hence, in this case, some element of the peripheral oedema might have been caused by the right atrial myxoma, yet the Kimmelstiel-Wilson syndrome alone was charged with this abnormality.

#### SUMMARY

Space-occupying neoplasms of cardiac chambers, either primary or metastatic, may give rise to clinical signs and symptoms nearly indistinguishable from those of other forms of cardiac disease, particularly valvular and myocardial.



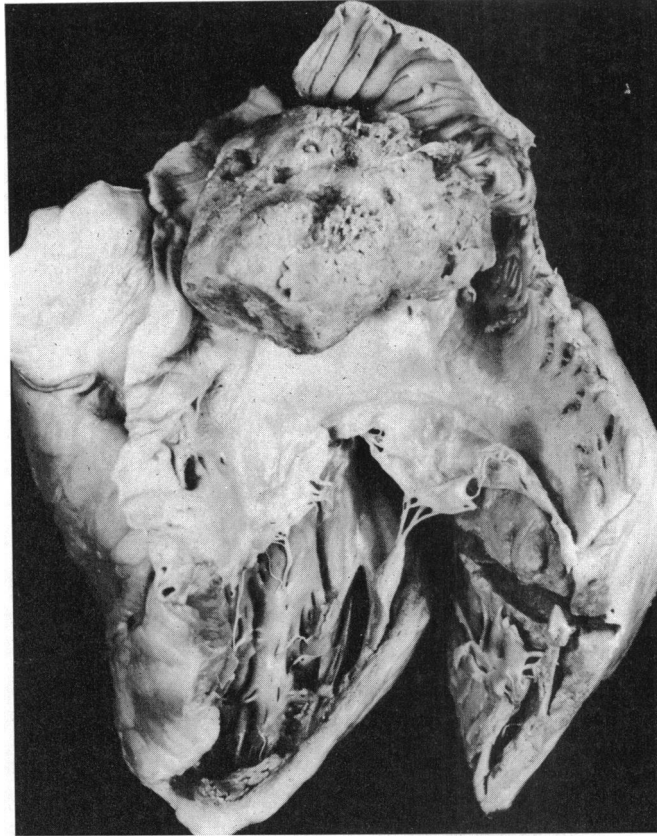


FIG. 7.—Case 15. Right atrium and right ventricle. Metastatic carcinoma involves the septal wall of the right atrium and the tumour protrudes into the right atrial cavity to occupy a considerable portion of the space in this chamber. A tumour was also present in the left atrial chamber.

Fifteen cases of tumours involving the cavities of the heart with pathological confirmation were studied. Two were examples of primary malignant cardiac tumours, one arising in the left atrium, the other in the right ventricle. Each of the 9 examples of primary benign tumours was a myxoma: 8 involved the left atrium, and one the right atrium.

Four cases of metastatic tumour to the cardiac cavities were observed. One was an example of a bronchogenic carcinoma with secondary involvement of both atria. The second was an example of metastatic rhabdomyosarcoma which had originated in the abdominal paravertebral muscles and extended from a metastatic focus in the lung through a pulmonary vein to occupy space in the left atrial cavity. The third case was that of a malignant myeloma in which both atria were involved but in which the obstructive effects were manifested in the right atrium. The final case was represented by 2 metastatic lesions from carcinoma of the breast; one compromised the lumen of the right atrium, and

the second mass protruded from the right ventricular wall into the cavity of the right ventricle.

#### REFERENCES

- Fawcett, R. E. M., and Ward, E. M. (1939). Cardiac myxoma; A clinical and pathological study. *Brit. Heart J.*, 1, 249.
- Gilchrist, A. R., and Millar, W. G. (1936). Paroxysmal auricular tachycardia associated with a primary cardiac tumour. *Edinb. med. J.*, 43, 243.
- Göttel, L. (1919). Ein Fall von primärem Herztumor. *Dtsch. med. Wschr.*, 45, 937.
- Lisa, J. R., Hirschhorn, L., and Hart, C. A. (1941). Tumors of the heart. Report of four cases and review of literature. *Arch. intern. Med.*, 67, 91.
- Prichard, R. W. (1951). Tumors of the heart. Review of the subject and report of one hundred and fifty cases. *Arch. Path.*, 51, 98.
- Whorton, C. M. (1949). Primary malignant tumors of the heart. *Cancer (N.Y.)*, 2, 245.
- Yater, W. M. (1931). Tumors of the heart and pericardium. Pathology, symptomatology and report of nine cases. *Arch. intern. Med.*, 48, 627.