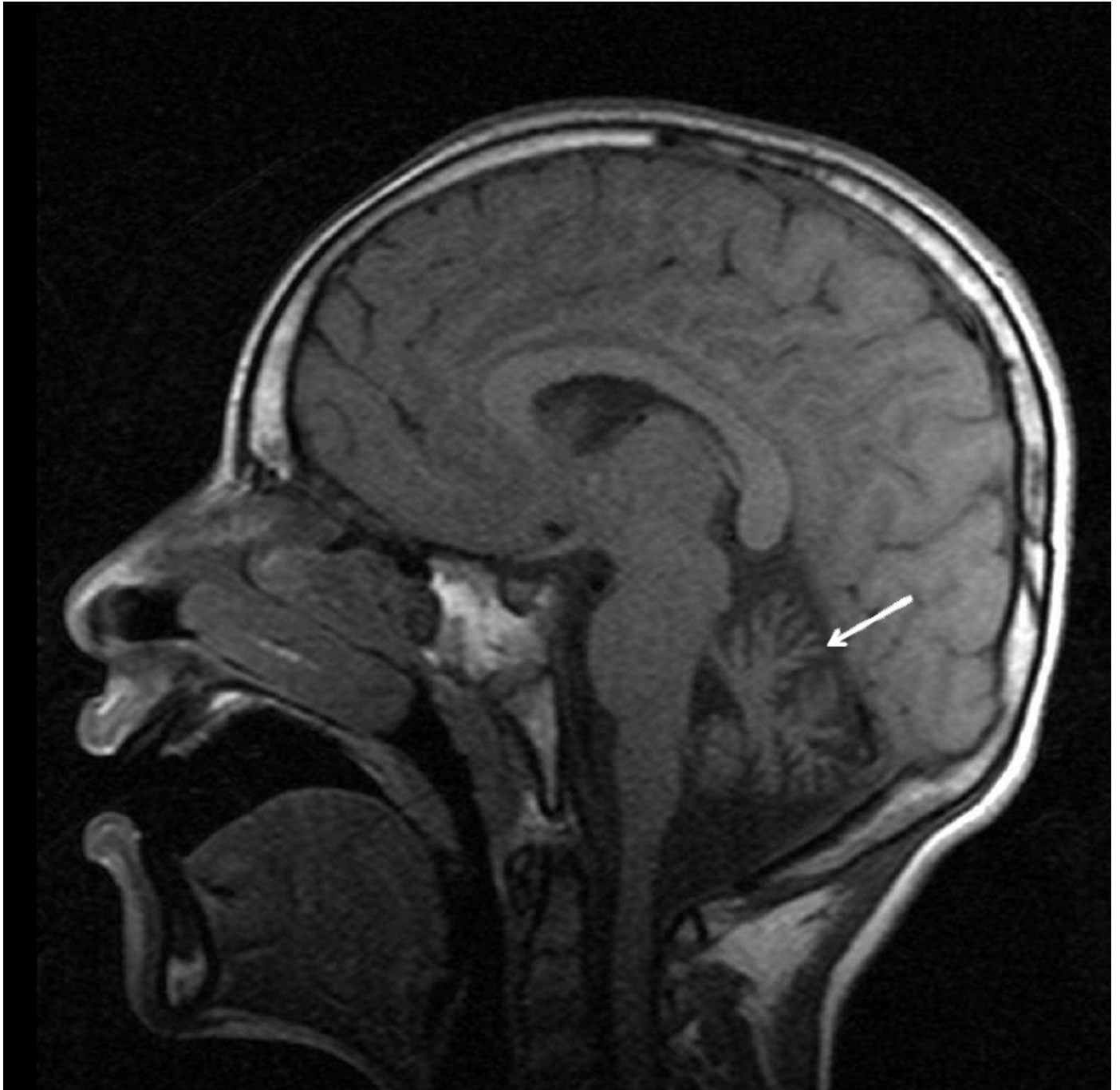


Additional file 1



MRI scan of index patient showing atrophy (white arrow)