

# Localised airway narrowing in sarcoidosis

JW HADFIELD, RL PAGE, CDR FLOWER, JE STARK

From Papworth Hospital, Papworth Everard, Cambridge, and Addenbrooke's Hospital, Cambridge

**ABSTRACT** Four patients developed multiple narrowings or occlusions of bronchi during the early stages of sarcoidosis when the chest radiograph showed no evidence of pulmonary fibrosis. Three of the patients had symptoms of breathlessness and wheezing and all had an obstructive defect of ventilation. Bronchography showed stenoses that were not apparent at bronchoscopy. It is concluded that the possibility of bronchial narrowing should be considered in patients who develop breathlessness or wheezing at any stage of sarcoidosis, and that bronchoscopy should be supplemented by bronchography.

Granulomatous lesions of the bronchial mucosa are so common in sarcoidosis that bronchial mucosa is one of the sites most likely to yield diagnostic material at biopsy.<sup>1</sup> On the other hand, narrowing of the bronchi sufficient to cause symptoms or major abnormalities of lung function is generally considered to be uncommon and to occur only in the later stages of pulmonary sarcoid when fibrosis of the lungs has developed.

During 1974-9 we have seen seven patients with localised bronchial narrowing in association with sarcoidosis. Three of these patients had advanced fibrotic changes in the lung and stenosis of the well-recognised pattern described by Citron and Scadding.<sup>2</sup> The other four patients developed multiple localised narrowings of bronchi at an early stage of the disease and with no radiographic evidence of pulmonary fibrosis and are described in this report.

## Diagnosis and investigations

The diagnosis of sarcoidosis in all four patients was confirmed by biopsy of bronchial mucosa, which showed non-caseating epithelioid and giant-cell granulomas, and by the absence of acid-alcohol fast bacilli in sputum and biopsy specimens. A Kveim test was positive in all three patients on whom it was performed. Mantoux tuberculin tests gave negative results in all patients, as did prick skin tests against common allergens. No patient had an excess of eosinophils in the peripheral blood. All patients had tests of lung function including spirometry, flow volume loops, and carbon monoxide transfer factor (single breath).<sup>3</sup> Bronchograms were carried out at

the time of fiberoptic bronchoscopy in three patients using aqueous propylidone and as a separate procedure in one patient.

## PATIENT 1

*Multiple areas of narrowing of segmental bronchi in a man with erythema nodosum and bilateral hilar lymphadenopathy*—A 32-year-old accountant, who did not smoke and had no personal or family history of asthma or atopic disease, became mildly breathless on exertion and noticed an expiratory wheeze. Three months later, in December 1978, he developed erythema nodosum; at this time a chest radiograph showed bilateral hilar node enlargement and clear lungs. On examination an expiratory wheeze could be heard over both lungs. Spirometry showed a one-second forced expiratory volume (FEV<sub>1</sub>) of 2.1 litres and forced vital capacity (FVC) of 3.4 l (predicted 5.2 l). There was no improvement after inhalation of isoprenaline. The TLCO was 23.8 ml min<sup>-1</sup> mm Hg<sup>-1</sup> (7.93 mmol min<sup>-1</sup> kPa<sup>-1</sup>) (predicted 35 ml min<sup>-1</sup> mm Hg<sup>-1</sup> (11.66 mmol min<sup>-1</sup> kPa<sup>-1</sup>)). The KCO was 109% of the predicted value. A presumptive diagnosis of sarcoidosis was made and the erythema nodosum subsided without specific treatment. Effort dyspnoea and wheeze persisted with no change in the radiographic appearances, and in April 1979 FEV<sub>1</sub> was 2.3 l, FVC 3.8 l, and TLCO unchanged. A flow volume loop (fig 1) showed a pattern usually attributed to lower airways obstruction. At fiberoptic bronchoscopy the mucosa of the left upper lobe had a "cobblestone" appearance and there was complete occlusion of the apicoposterior segment of the left upper lobe. The remainder of the bronchial tree appeared normal, but a bronchogram showed narrowing of both segmental bronchi of the left upper lobe and in addition

Address for reprint requests: Dr JE Stark, Chest Department, Addenbrooke's Hospital, Hills Road, Cambridge CB2 2QQ.

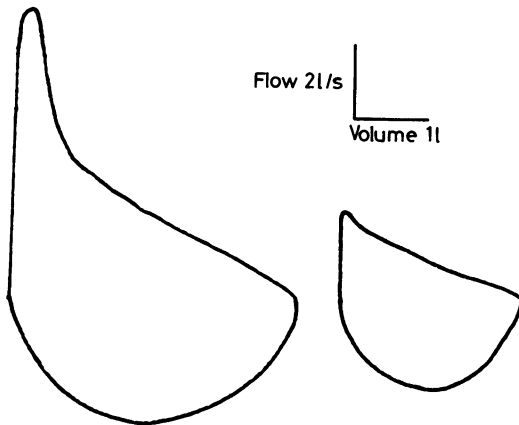


Fig 1 Flow-volume loops: on the left from patient 1, showing a pattern typical of small airways obstruction; and on the right from patient 3, showing a pattern more typical of intrathoracic large airways obstruction.

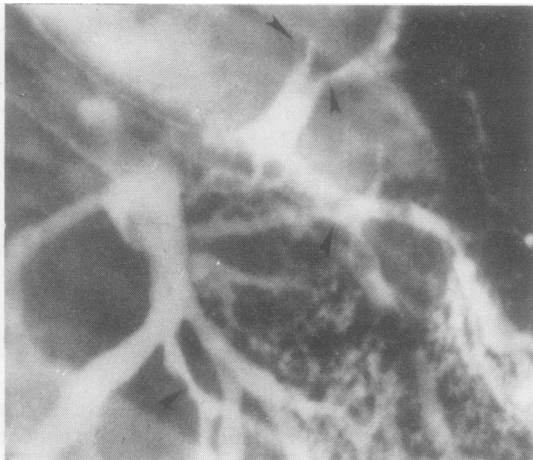


Fig 2 Part of the bronchogram of patient 1, showing localised areas of narrowing in the left-upper-lobe and left-lower-lobe segmental bronchi.

narrowing of most of the segmental bronchi of both lower lobes (fig 2). Biopsy of the mucosa of the left-upper-lobe bronchus showed non-caseating epithelioid and giant-cell granulomas consistent with sarcoidosis.

Treatment was started with prednisone at a dose of 30 mg daily and the wheeze and breathlessness subsided within one month. At this time FEV<sub>1</sub> was 2.65 l and FVC 4.1 l. The dose of prednisone was reduced slowly to 20 mg daily and after three months of treatment FEV<sub>1</sub> was 3.4 l and FVC 4.65 l. A chest radiograph at this stage showed some lessening of the hilar node enlargement.

The dose of prednisone was gradually reduced to 10 mg daily and 11 months after starting corticosteroid treatment the chest radiograph was normal, FEV<sub>1</sub> was 3.4 l, and FVC was 4.4 l. A further fiberoptic bronchoscopy showed normal bronchial mucosa with some persisting narrowing of the left upper lobe segmental bronchi. A bronchogram showed that although many segmental bronchi were still narrowed there had been a considerable improvement. The prednisone has been gradually reduced to 10 mg on alternate days and the patient has remained free of breathlessness and wheeze. Two years after presentation the FEV<sub>1</sub> was 3.4 l, FVC 5.0 l, and TLC<sub>0</sub> 30 ml min<sup>-1</sup> mm Hg<sup>-1</sup> (10 mmol min<sup>-1</sup> kPa<sup>-1</sup>). The chest radiograph has remained normal and no further bronchoscopy or bronchography has been performed.

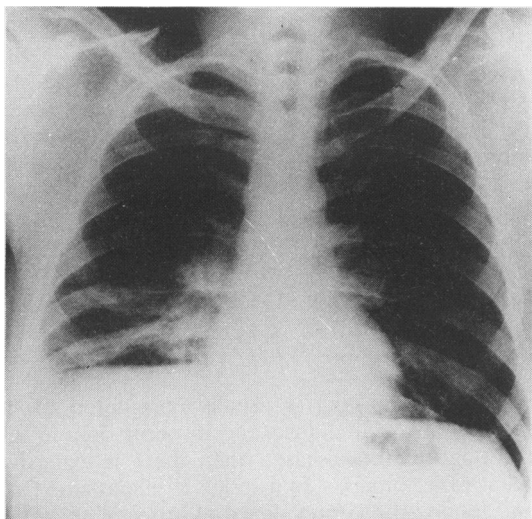
#### PATIENT 2

*Narrowing of lobar and segmental bronchi in a patient with bilateral hilar lymphadenopathy and patchy shadowing of lobar distribution*—A 28-year-old lorry driver developed grand mal epilepsy in March 1978, having previously been in good health. Computerised axial tomography showed low-density areas in the left temporal and right frontotemporal regions, within which there were multiple small areas of density enhancement after the injection of contrast medium. The patient had no respiratory symptoms but his chest radiograph showed bilateral hilar node enlargement with patchy shadowing in the right middle and lower lobes (fig 3). FEV<sub>1</sub> was 2.4 l and FVC 3.8 l (predicted 5.4 l). There was no improvement in these values after the inhalation of isoprenaline. TLC<sub>0</sub> was 68% of predicted and KCO was normal. A flow volume loop showed a pattern similar to that of patient 1, suggesting lower airways obstruction.

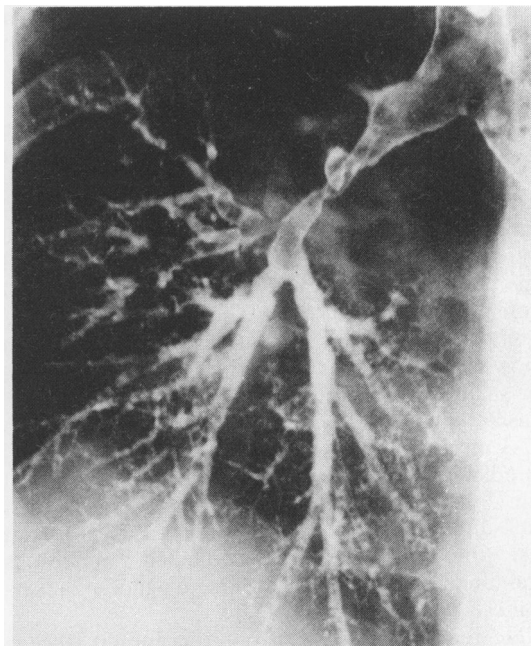
At fiberoptic bronchoscopy there was generalised hyperaemia of the bronchial mucosa and narrowing of the intermediate and middle-lobe bronchi. Bronchography showed irregularity of the lumen of the intermediate bronchus and narrowing of all the segmental divisions of the right lower lobe (fig 4). There was also narrowing of the middle-lobe bronchus at its bifurcation. Biopsy of the mucosa from the middle lobe showed non-caseating giant-cell granulomas and the Kveim test showed similar appearances.

#### PATIENT 3

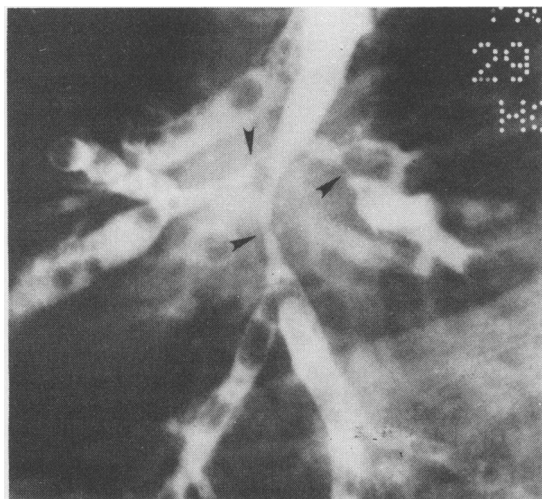
*Longstanding severe narrowing of the bronchus of the right upper lobe with chest radiograph showing right paratracheal lymph node enlargement and loss of volume in the right lung*—In 1974 a 37-year-old housewife was found to have left supraclavicular



**Fig 3** Chest radiograph of patient 2, showing bilateral hilar node enlargement and loss of volume and infiltration of the right middle and lower lobes.



**Fig 5** Bronchogram of patient 3, showing complete occlusion of the right-upper-lobe bronchus and severe narrowing of the intermediate bronchus.



**Fig 4** Detail from the bronchogram of patient 2, showing severe narrowing of the segmental bronchi in the right lower lobe.

lymphadenopathy when she presented with an 18-month history of cough, effort dyspnoea, and wheezing. She had never smoked and had no past history of asthma or allergic disease. Her chest radiograph showed right paratracheal lymphadenopathy and loss of volume of the right lung as evidenced by mediastinal shift. A bronchogram showed an occluded bronchus of the right upper lobe and narrowing of the intermediate bronchus (fig 5). There was no filling of the middle-lobe bron-

chus or of the apical segmental bronchus to the lower lobe. The patient was thought to have a bronchial carcinoma but a rigid bronchoscopy, while confirming the occlusion, failed to show any endobronchial lesion apart from a pale mucosa. Biopsy of the bronchial mucosa and of the supraclavicular gland showed non-caseating epithelioid and giant-cell granulomas. Spirometry at that time showed an FEV<sub>1</sub> of 1.25 l and FVC of 2.55 l (predicted FVC 3.6 l). TLCO was 92% of predicted and KCO 157% of predicted. There was a 25% improvement in FEV<sub>1</sub> and a 15% improvement in FVC after the inhalation of isoprenaline. The flow-volume loop suggested intrathoracic large airways obstruction (fig 1). Treatment was started with prednisone 30 mg daily, which was reduced to a maintenance dose of 10 mg daily after four months. Although the patient became less dyspnoeic there was no improvement in the results of pulmonary function tests.

Four years after her initial presentation she was admitted with right-upper-lobe pneumonia. A fiberoptic bronchoscopy performed during recovery showed persisting occlusion of the right upper lobe and the bronchographic appearances were identical to those found four years previously. The pneumonia cleared with antibiotics and physiotherapy. The patient has remained on cor-

ticosteroids but pulmonary function testing has failed to show any improvement since that time.

#### PATIENT 4

*Multiple areas of subsegmental bronchial narrowing in a man with bilateral hilar lymphadenopathy and widespread nodular shadowing*—A 22-year-old aircraft fitter presented in October 1975 with a four-month history of nocturnal cough and occasional wheeze. He had smoked 15 cigarettes a day until this time but had no personal or family history of asthma or atopic disease. There were no abnormalities on examination but his chest radiograph showed bilateral hilar gland enlargement and nodular shadowing in both mid and upper zones. FEV<sub>1</sub> was 2.9 l, FVC was 4.1 l (predicted 4.9 l), and TLCO 27.3 ml min<sup>-1</sup> mm Hg<sup>-1</sup> (9.1 mmol min<sup>-1</sup> kPa<sup>-1</sup>) (predicted 31.5 ml min<sup>-1</sup> mm Hg<sup>-1</sup> (10.5 mmol min<sup>-1</sup> kPa<sup>-1</sup>)). The FEV<sub>1</sub> improved by less than 20% after the inhalation of isoprenaline. The Kveim test biopsy specimen contained numerous granulomas consistent with the diagnosis of sarcoidosis.

He remained well with only occasional wheeze associated with purulent sputum until July 1976, when he developed vomiting and was found to have a serum calcium concentration of 3.78 mmol/l (15.3 mg/100 ml). Treatment was started with prednisone at a dose of 60 mg daily and the serum calcium returned to normal. During the first two weeks of corticosteroid treatment spirometry showed improvement—FEV<sub>1</sub> rose from 3.2 l to 3.6 l and FVC from 4.9 l to 5.5 l. The prednisone dosage was reduced to 10 mg daily and the patient remained symptom free with serum calcium levels within the normal range. The chest radiograph showed persistent bilateral hilar gland enlargement with widespread nodular shadowing and loss of volume in the right upper lobe, as evidenced by elevation of the horizontal fissure and right hilum. By March 1978 the dose of prednisone had been reduced to 5 mg on alternate days. After this he complained of wheezing that occurred only when he lay down. At this stage FEV<sub>1</sub> was 3 l, FVC 4.5 l, and TLCO 84% of predicted. His chest radiograph had remained unchanged and fiberoptic bronchoscopy showed that the mucosa was abnormal throughout the bronchial tree with erythema and cobblestone appearance. Biopsy of mucosa showed characteristic appearances of sarcoidosis. The right-lower-lobe bronchus was narrow but no other abnormalities were identified. For technical reasons a bronchogram did not adequately outline the right bronchial tree, but there was localised narrowing of subsegmental divisions of the left upper lobe at their origins. The dose of prednisone was increased to 20 mg daily and the

postural wheeze disappeared. FEV<sub>1</sub> increased to 3.5 l and FVC to 5.1 l; TLCO remained at 85% of predicted.

The patient has remained on prednisone, which has been reduced to 10 mg on alternate days. The improvement in FVC has been maintained, although he has had a persistent mild obstructive defect, the flow-volume loop being typical of lower airways obstruction. The chest radiograph has shown complete clearing of the nodular shadowing, although the loss of volume in the right upper lobe has persisted.

#### Discussion

Bronchial narrowing is usually considered to be uncommon in sarcoidosis and to occur only in the late stage of the disease, when there is extensive pulmonary fibrosis.<sup>2,4</sup> In a series of 99 patients Olsson<sup>5</sup> found an 8% prevalence of bronchial narrowing at bronchoscopy at various stages of the disease, and earlier reports<sup>4,6,14</sup> suggest a frequency of 2–3%. The occurrence of bronchial stenosis in the early stages of sarcoidosis has been described much less often but our experience suggests that it may not be uncommon. We have found only two previous reports of bronchial stenosis in patients who like our first patient had radiographically normal lungs.<sup>5,8</sup>

Physiological evidence of airway obstruction is common in fibrotic pulmonary sarcoidosis,<sup>9,10</sup> but may also be present in the earlier stages.<sup>11,12</sup> The most commonly observed abnormalities are frequency dependence of dynamic compliance and abnormal closing volumes, suggesting that the obstruction principally affects small airways. Bower and Dantzber<sup>12</sup> reported that 64% of their patients had an obstructive defect at the time when the lungs were radiologically clear and that such a defect could be detected by flow-volume loops. Three of our four patients had breathlessness with wheezing in the early stages of sarcoidosis and all had clear evidence of expiratory airways obstruction. In three patients (cases 1, 2, and 4) flow-volume loops were of a shape characteristic of obstruction of lower airways; but the fourth patient (case 3), who had narrowing of the intermediate bronchus and complete occlusion of the right-upper-lobe bronchus, had a flow-volume loop of a pattern usually associated with intrathoracic large airway obstruction.

The patients we describe all had bronchoscopically visible narrowing of lobar or segmental bronchi with or without associated abnormal appearances of the mucosa, but bronchography showed many additional areas of narrowing in bronchi that had appeared on inspection to be normal. Recognition of localised changes in bronchial calibre through the bronchoscope is not easy and we have had similar

difficulties in detecting localised dilatation of bronchi in patients with bronchiectasis. In both these conditions we find bronchography at the end of fiberoptic bronchoscopy to be of great value.

The mechanism of bronchial narrowing is not clear. Hilar glands may very rarely compress central airways<sup>13</sup> and granulomas probably may compress small peripheral airways<sup>11</sup> or presumably cause narrowing by infiltration of the mucosa. In the later stages of sarcoidosis cicatricial fibrosis and distortion of airways is the likely cause of obstruction.<sup>4</sup> We do not know the basis of obstruction in our patients but its persistence in some cases, despite treatment with corticosteroids and despite reduction in size of previously enlarged nodes, suggest that fibrotic changes may have occurred in the bronchi at a relatively early stage of the disease. Two of our patients (cases 1 and 4) have improved symptomatically while receiving corticosteroids but have a persisting obstructive defect of ventilation, and in case 3 there has been no improvement during corticosteroid treatment.

We suggest that the possibility of bronchial narrowing should be considered in patients with sarcoidosis who develop breathlessness or wheezing at any stage of the disease, and that bronchoscopy should be supplemented by bronchography in investigation of these patients.

We gratefully acknowledge the help of Dr PGI Stovin in the histological examinations.

## References

- <sup>1</sup> Mitchell DM, Mitchell DN, Collins JV, Emerson CJ. Transbronchial lung biopsy through fiberoptic bronchoscope in diagnosis of sarcoidosis. *Br Med J* 1980;**280**:679-81.
- <sup>2</sup> Citron KM, Scadding JG. Stenosing non-caseating tuberculosis (sarcoidosis) of the bronchi. *Thorax* 1957;**12**:10-23.
- <sup>3</sup> Cotes JE. *Lung function*. 4th ed. Oxford: Blackwell Scientific Publications, 1979:235.
- <sup>4</sup> Scadding JG. *Sarcoidosis*. London: Eyre and Spottiswoode, 1967:138-40.
- <sup>5</sup> Olsson T, Björnstad-Petersen H, Stjerberg NL. Bronchostenosis due to sarcoidosis. *Chest* 1979;**75**:663-6.
- <sup>6</sup> Harrison BDW. Upper airway obstruction—a report on 16 patients. *Q J Med* 1976;**45NS**:625-45.
- <sup>7</sup> Huzly A, Hoffman A, Seidd H, *et al*. Les bronches dans la sarcoidose. *Bronches* 1963;**13**:531-58.
- <sup>8</sup> Benedict EB, Castleman B. Sarcoidosis with bronchial involvement. *N Engl J Med* 1941;**224**:186-9.
- <sup>9</sup> Cullen JH, Katz HL, Kaemmerlen JT. Chronic diffuse pulmonary infiltration and airway obstruction. *Am Rev Respir Dis* 1965;**92**:775-80.
- <sup>10</sup> Sharma OM. Airway obstruction in sarcoidosis. *Chest* 1978;**73**:6-7.
- <sup>11</sup> Levinson RS, Metzger LF, Stanley NN, *et al*. Airway function in sarcoidosis. *Am J Med* 1977;**62**:51-9.
- <sup>12</sup> Bower JS, Dantzker DR. Airway obstruction in sarcoidosis. *Am Rev Respir Dis* 1977;**115**(4):91.
- <sup>13</sup> Di Benedetto RJ, Ribaud C. Bronchopulmonary sarcoidosis. *Am Rev Respir Dis* 1966;**64**:952-8.
- <sup>14</sup> Weisner B. Diagnostic bronchologique de la sarcoidose. *Bronches* 1973;**23**:104-11.