

## Normal axonemal structure and function in Kartagener's syndrome: an explicable paradox

M GREENSTONE, A RUTMAN, D PAVIA, D LAWRENCE, PJ COLE

From the Host Defence Unit, Department of Medicine, Cardiothoracic Institute, Brompton Hospital; and the Royal Free Hospital, London; and Clatterbridge Hospital, Bebington, Wirral, Merseyside

Kartagener's syndrome is a clinical triad consisting of bronchiectasis, sinusitis, and situs inversus. Its association with ciliary abnormalities was first described in 1976<sup>1</sup> and since then there have been many reports confirming this association. It is believed that an inherited defect, usually of dynein formation, causes impaired ciliary beating, resulting in poor mucociliary clearance and consequent recurrent or chronic infection in upper and lower respiratory tracts. Because the sperm tail has an identical ultrastructure to the ciliary axoneme, immotile spermatozoa and male infertility are an integral part of this condition.<sup>1,2</sup> We report a male patient with Kartagener's syndrome who was fertile and had normal respiratory tract cilia.

### Case report

A 43 year old man was admitted for investigation of bronchiectasis. As a child he had measles, varicella, and a cough for some months after the latter. Dextrocardia was diagnosed on mass miniature radiography at the age of 11 years. Intermittent rhinorrhoea occurred throughout childhood and a sinus washout was performed at the age of 27 years because of recurrent headaches. He remained well, however, until he was 15, when he developed pneumonia. At the age of 21 he had a further episode of pneumonia after (left sided) appendicectomy. Since then he had suffered cough productive of purulent sputum most days and required one or two courses of antibiotics a year for acute chest infections. At the age of 24 he fathered a healthy girl, who remains well. Examination showed total situs inversus and chest auscultation revealed crackles in the left mid zone. Investigation showed a normal blood count, immunoglobulins, and sweat test result. Auto-antibodies and *Aspergillus fumigatus* precipitins were absent from the serum. Spirometry indicated mild irreversible airways obstruction (FEV<sub>1</sub> 2.5 litres, FVC 3.8 l, FEV<sub>1</sub>/FVC 66%). Sinus radiographs showed antral mucosal thickening but normal frontal sinuses. A chest radiograph showed dextrocardia with changes of cystic bronchiectasis in the left "middle" lobe. Nasal mucociliary clearance on two occasions was 12 and 15 minutes (normal < 30 minutes<sup>3</sup>) and during measurement of tracheobronchial clearance<sup>4</sup> there was rapid clearance of technetium 99 labelled polystyrene particles from the lungs, although this was partly assisted by cough (fig 1). Fibreoptic bronchoscopy showed bronchial

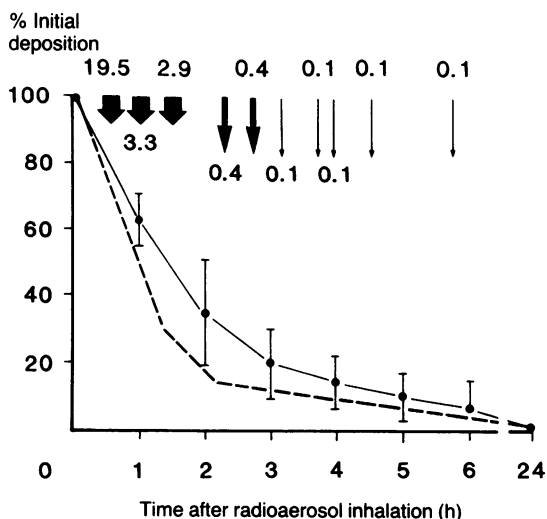


Fig 1 Tracheobronchial clearance for patient (dotted curve), with mean and SD tracheobronchial clearance for a group of six healthy subjects shown for comparison. The arrows indicate the times of sputum production, with percentages of initial tracheobronchial deposition within each sample.

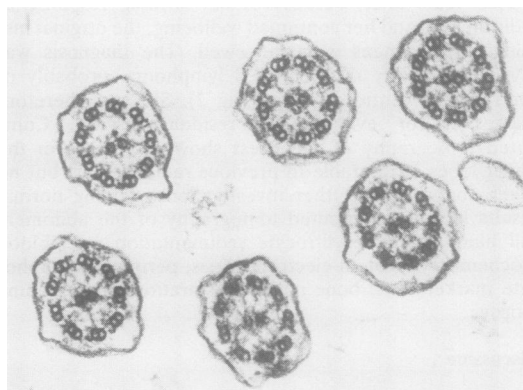


Fig 2 Electron micrograph of bronchial cilia showing normal arrangement of microtubular structures and normal complement of dynein arms. ( $\times 57\,000$ .)

Address for reprint requests: Dr M Greenstone, St Luke's Hospital, Bradford BD50NA.

Accepted 23 April 1985

situs inversus and purulent secretions in the left "middle" and right upper lobes. Ciliary beat frequency<sup>5</sup> of nasal and bronchial epithelium (mean(SD)) was 14.7(1) and 15.9(2) Hz (normal range 11–16 Hz). Full motility was observed in both specimens with no evidence of ciliary dyskinesia. Transmission electron microscopy of nasal and bronchial cilia (total 134 cilia) was normal with normal microtubular structures and full complement of dynein arms (fig 2). A sperm count revealed  $54 \times 10^6$  sperm/ml, of which 40% were motile and progressing well at four hours (normal 40–50%). The sperm tail ultrastructure was normal.

## Discussion

This patient, although clinically suffering from Kartagener's syndrome, did not have the usual associated impairment of mucociliary clearance in upper and lower respiratory tract. Furthermore, there was no impairment of in vitro ciliary function or any abnormality of ultrastructure. Although it is known that ciliary function may be impaired in the presence of normal appearances on electron microscopy,<sup>2</sup> in this case both were normal. It was therefore not surprising that, as he did not have the dynein arm defect or any other defect of ultrastructure, his sperm tails were functionally normal.

This case demonstrates that Kartagener's syndrome is not always associated with functional or structural ciliary abnormalities. The incidence of situs inversus in most community based studies is of the order of 1 in 10 000 of the population.<sup>6</sup> In one hospital based study the incidence of bronchiectasis diagnosed radiologically among patients with dextrocardia was almost 20%,<sup>7</sup> although only 1.5% of bronchiectatic patients have dextrocardia.<sup>8</sup> In this case the situs inversus is, we believe, a coincidence. Our patient is most likely to have developed his bronchiectasis after a pneumonic illness as an adolescent or young adult. Certainly his symptoms did not indicate a lifelong history of impaired respiratory tract mucociliary clearance, in that he did not recall daily productive cough as a child—at least until his first episode of pneumonia at the age of 15 years. Bronchiectasis is frequently accompanied by sinusitis,<sup>8,9</sup> the incidence depending on the population studied.

Another important aspect of this case is that it may help to explain some of the apparent incongruities concerning male infertility in Kartagener's syndrome. Rott described 12 children born to men with Kartagener's syndrome.<sup>10</sup> The

question of paternity was not investigated and it is possible that the propositus was not the true father in every case. In the patient reported by Jonsson and colleagues,<sup>11</sup> however, there was a discordance between the dynein deficient cilia and the actively motile and structurally normal sperm tails. Investigation in our patient provides a third possible explanation for male fertility in this condition—namely, the occurrence of the clinical syndrome without any associated defect of ciliary structure and function. It seems likely that some of the fertile men with Kartagener's syndrome who have been reported had a similar fortuitous association of situs inversus and bronchiectasis and that, in these cases, Kartagener's syndrome was not due to the more common inherited abnormality of ciliary function.

## References

- 1 Afzelius BA. A human syndrome caused by immotile cilia. *Science* 1976;193:317–9.
- 2 Pedersen M. Specific types of abnormal ciliary motility in Kartagener's syndrome and analogous respiratory disorders. *Eur J Respir Dis* 1983;63, suppl 127:78–90.
- 3 Stanley P, MacWilliam L, Greenstone M, Mackay I, Cole P. Efficacy of a saccharin test for screening to detect abnormal mucociliary clearance. *Br J Dis Chest* 1984;78:62–5.
- 4 Pavia D, Sutton PP, Agnew JE, Lopez-Vidriero MT, Newman SP, Clarke SW. Measurement of bronchial mucociliary clearance. *Eur J Respir Dis* 1983;64, suppl 127:41–56.
- 5 Rutland J, Cole PJ. Non-invasive sampling of nasal cilia for measurement of beat frequency and study of ultrastructure. *Lancet* 1980;ii:564–5.
- 6 Baker-Cohen KF. Visceral and vascular transposition in fishes and a comparison with similar anomalies in man. *Am J Anat* 1961;109:37–55.
- 7 Miller D, Divertie MB. Kartagener's syndrome. *Chest* 1972;62:130–5.
- 8 Perry KMA, King DS. Bronchiectasis. A study of prognosis based on a follow-up of 400 patients. *American Review of Tuberculosis* 1940;41:531–48.
- 9 Sanderson JM. Results of treatment of bronchiectasis by surgery. *Thorax* 1975;30:239.
- 10 Rott HD. Kartagener's syndrome and the syndrome of immotile cilia. *Hum Genet* 1979;46:249–61.
- 11 Jonsson MS, McCormick JR, Gillies CG, Gondos B. Kartagener's syndrome with motile spermatozoa. *N Engl J Med* 1982;307:1131–3.