Thorax 1986;**41**:176–189

Pathogenesis of pleurisy, pleural fibrosis, and mesothelial proliferation

AMANDA HERBERT

From the Department of Histopathology, Southampton General Hospital, Southampton

Systemic and pulmonary diseases that affect the pleura are usually characterised by accumulation of fluid in the pleural cavity or by fibrous healing of damaged mesothelium. Some of the reactive changes in the mesothelial cells and fibroblasts concerned in these processes may closely mimic neoplasia and must be distinguished from metastatic carcinoma and malignant mesothelioma. Before we consider the pathogenesis of these conditions it is necessary to understand the development and structure of pleura, the unique mechanism for regeneration of mesothelium, and the factors responsible for breakdown of this mechanism and for the resulting fibrous repair.

Development and structure of the pleura

The pleura and other serous cavities develop from the extraembryonic coelom, which appears in the blastocyst as early as the second week of embryonic life. The parietal pleura is derived from the somatopleura, which also covers the amnion and lines the trophoblast; whereas the visceral pleura is derived from the splanchnopleura, which also surrounds the yolk sac.[1] The pleural connective tissue and its highly specialised mesothelial lining are thus derived entirely from mesoderm: parietal and visceral pleurae develop separately in the early embryo, preserving certain structural and functional differences in the adult.

The anatomical layers of the pleura are shown diagramatically in the figure. The mesothelium and a thin layer of submesothelial connective tissue cover a well developed network of fibres that form the external elastic lamina. This is separated from the internal elastic lamina by the interstitial layer, which contains lymphatics and blood vessels and is continuous with the interlobular connective tissue. The internal elastic lamina is present in both parietal and visceral pleura, although in the latter it is indistinguisable from the elastic of the peripheral alveoli.[2]

Address for reprint requests: Dr Amanda Herbert, Department of Histopathology, Southampton General Hospital, Southampton SO9 4XY.

PLEURAL LYMPHATICS

The lymphatic flow in the adult lung is directed by valves.[2 3] Subpleural lymphatic vessels, situated in the deep aspect of the interstitial layer, drain along the surface of the lung, as well as through intrapulmonary lymphatic vessels, to the hilar lymph nodes.[2] Intralobular pulmonary lymphatics drain outwards to the subpleural network.[3] The anterior parietal and diaphragmatic lymphatics drain to the internal mammary chain. The posterior parietal and diaphragmatic lymphatics drain mainly to the intercostal and paravertebral nodes, but also through the diaphragm to the retroperitoneal nodes.[2]

The controversy about the existence of stomata between the pleural space and lymphatics has been resolved largely by scanning electron microscopy and is reviewed by Whitaker *et al.*[4] The existence of subdiaphragmatic stomata, as described by Allen in 1936,[5] has been confirmed.[6] Stomata have also been shown to be present in the parietal pleura of the caudal and ventral mediastinum and the lower part of the costal pleura, in both experimental animals and man.[7] The distribution of the stomata is similar to that of the aggregates of macrophages and specialised mesothelial cells refered to as "Kampmeier foci"[8 9]: these structures are not found in the visceral pleura.[7] Large particles and cells pass through the stomata,[7] while protein is absorbed exclusively through the pleural lymphatics.[10 11]

PLEURAL BLOOD SUPPLY

There has been disagreement about the origin of the blood vessels in the interstitial layer of the pleura. Although von Hayek[12] stated that the pulmonary arteries supplied the visceral pleura, others have shown that in man the pleura is supplied by branches of the bronchial arteries.[2 3] According to Miller, the subpleural veins drain to the pulmonary vein, whereas Nagaishi has shown that some drain to the pulmonary veins and others via the extrapulmonary bronchial vein to the right atrium.[2 3]

THE MESOTHELIUM

The mesothelial cells form a complete layer of cells

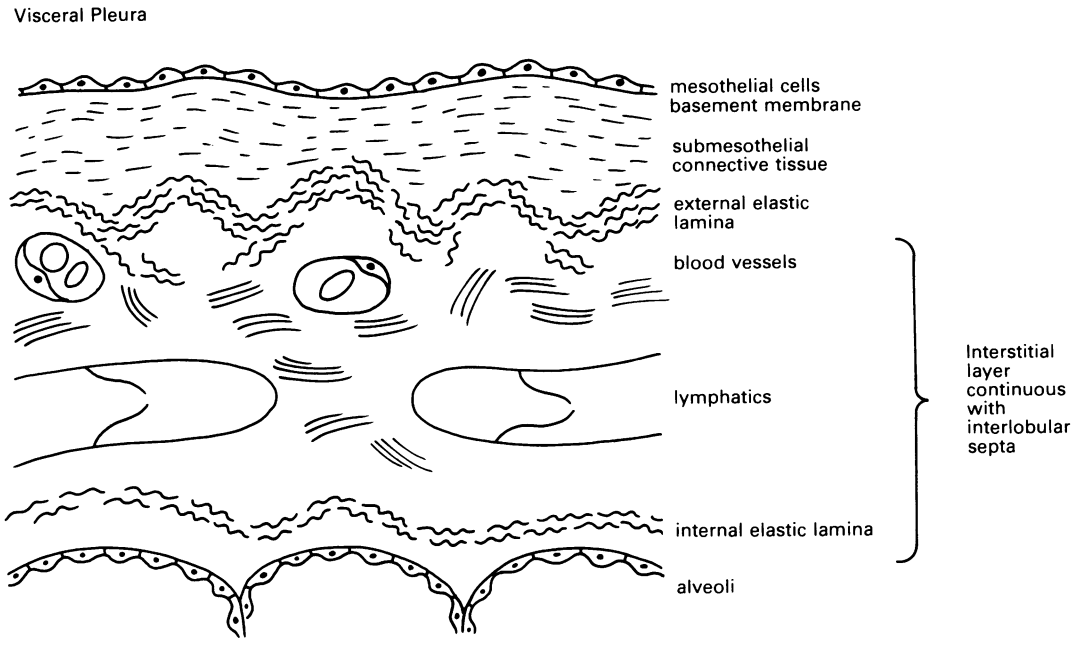

Diagram of the anatomical layers of the pleura.

connected by overlapping cytoplasmic processes with variable tight and gap junctions, many of which appear to be in a state of formation and dismantlement.[13] The cells are flattened, with the cytoplasm raised over a central nucleus. Surface microvilli are more numerous on visceral than parietal mesothelial cells, possibly because of the greater absorptive potential of the visceral pleura.[14] The micrcovilli are closely associated with pinocytotic vesicles and vacuoles that communicate with the luminal surface, intercellular channels, and the basal lamina.[4 15] Experimental studies, reviewed by Whitaker *et al*,[4] including cytochemical analysis of membrane associated enzymes, provide evidence that mesothelial cells are engaged in active transport rather than passive diffusion, supporting observations made many years ago by Starling and Tubby.[16] Fluid and small particles are transported through pinocytotic vesicles or intercellular channels,[15] depending on size.[4] The microvilli have a cell coat or glycocalyx, with a strong affinity for acid mucopolysaccharide; and it has been suggested that the slippery villous surface protects the pleura from frictional damage.[17] The role of the microvilli and glycocalyx in lubricating the pleural cavity is, however, uncertain and recent research has indicated that the pleura may be lubricated by phospholipid surfactants, producing a dry, hydrophobic surface analogous to an empty polythene bag.[18 19]

Mesothelial cells in culture synthesise hyaluronic acid, but in far smaller quantities than do fibroblasts, possibly reflecting their divergent differentiation at an early stage of embryogensis.[20] In culture they also produce small or even large amounts of collagen.[20 21]

There is evidence that mesothelial cells are capable of phagocytosis.[22] Although they can usually be distinguished from serosal macrophages, which are are derived from the bone marrow,[23] intermediate forms are sometimes seen,[24 25] raising the possibility that mesothelial cells in effusions may develop into facultative macrophages. Furthermore, mesothelial cells may contain non-specific esterase, acid phosphatase, alpha naphthol acetate esterase, α_1 antitrypsin and α_1 antichymotrypsin, all of which are present in macrophages but in greater amounts.[25-28]

Injury and repair

INJURY TO MESOTHELIAL CELLS

Mesothelial cells are highly susceptible to damage from agents that they do not normally encounter, such as air,[29 30] water,[31] asbestos,[22] foreign protein,[32] silica,[33] and even saline.[30] All these cause swelling of the cells, clubbing of microvilli, and separation of the cells from each other and from the basal lamina, resulting in exfoliation. The denuded surface

then shows an exudative inflammatory reaction, frequently accompanied by an effusion.

REGENERATION OF MESOTHELIUM

The exact mechanism of mesothelial regeneration is controversial, although there has been general agreement with Hertzler's observation that "the entire surface becomes endothelialised simultaneously, and not gradually, from the border, as in epidermitisation of skin wounds.[34] This process begins within 24 hours by the appearance of macrophages on the wound surface and is generally complete by 8–10 days.[4] The main controversy has revolved around the origin of the new mesothelial cells. Initial observations indicated that they may be derived from submesothelial fibroblasts[35 36]; but Johnson and Whitting[37] proposed that serosal macrophages might differentiate into mesothelial cells, a theory supported by light and transmission electron microscopic studies[38 39] and later by scanning electron microscopy.[40] Recent experiments, combining several investigative techniques, have indicated that mesothelial cells adjacent to the wound and on the opposing serous surface exfoliate, proliferate, and repopulate the area, replacing the macrophages that initially seal the wound.[41] This would confirm that mesothelial regeneration can occur without the participation of the underlying connective tissue,[40] and suggests that there is not transformation of either macrophages or fibroblasts into mesothelial cells. Many years ago Cameron *et al*[42] showed that detached mesothelial cells proliferate to repair peritoneal defects and, although it was subsequently accepted that this mechanism may play a part in mesothelial repair,[37 40] it was regarded as minor and relatively unimportant.[43 44]

FIBROUS REPAIR OF SEROSAL SURFACES

Although extensive areas of bare submesothelial connective tissue can be replaced by mesothelium, even minor surgical procedures sometimes give rise to dense peritoneal adhesions.[35] Similarly, fibrous obliteration of the pleura may follow both pleurisy and effusion—although, on the other hand, large amounts of fluid and even blood may be reabsorbed without any resultant fibrosis.[45] There has been extensive research into the pathogenesis of fibrous adhesions and the important factors in their development are the presence of blood,[46] extensive and persistent crushing or abrasion of the mesothelium,[47] the presence of foreign material,[48] and local ischaemia.[49] The critical factor appears to be the presence of a fibrinous exudate and whether or not this is absorbed.[47 49] This is closely related to the fibrinolytic power of serosal surfaces, which was recognised for many years before it was shown to be a specific property of mesothelial cells.[50–53] Newly regenerated mesothelium has greatly enhanced fibrinolytic activity, but fibrinolytic activity is depressed by damage to mesothelial cells and by dilution with serosal fluid.[30 52] Persistent depression of fibrinolysis is associated with the development of fibrosis.[47]

Despite their common origin from mesoderm, mesothelial cells, macrophages, and fibroblasts appear to be separate specialised populations of cells, which, although they overlap in their functional characteristics, play different parts in the response to injury. The mesothelium has great power of regeneration, but when this breaks down the pleural space becomes obliterated by fibrous connective tissue.

Manifestations of benign pleural disease

PLEURAL EFFUSION

Pleural effusions occur in human disease when alterations in the hydrostatic and colloid osmotic pressures result in transudation, or when alterations in capillary permeability associated with the inflammatory response result in exudation of protein rich fluid. Once an effusion has formed, whatever its cause, it is in a dynamic state, with a turnover rate of 30–75% per hour.[54] Protein is removed exclusively by the lymphatics, and may be blocked by ligating the thoracic duct.[10] Lymphatic flow has been measured in man as an average of 0.37 ml/kg per hour during the day, falling to 0.2 ml/kg per hour during the night, possibly because of the reduction in movement of the diaphragm and intercostal muscles.[11] The removal of *para*-aminohippurate (a relatively small molecule) through the pleural capillaries was estimated to be 4.5 mg/kg per hour, 13 times higher than the rate of lymphatic drainage and roughly correlating with a blood flow of 300 ml/h in an average adult.[11]

It has been accepted that fluid is secreted by the parietal pleura and reabsorbed by the visceral pleura, largely because of visceral capillary pressure has been thought to be that of the pulmonary circulation[19 55 56]—although recently some doubt has been cast on this.[57 58] In 1957 Agostoni *et al* demonstrated a visceral pleural absorptive force of 15 mm Hg in thoracotomised dogs.[59] Later Black,[60] using Agostoni's work as a basis, calculated that the parietal pleural secretory pressure is 6 cm H_2O, and the visceral pleural resorptive force 13 cm H_2O. Pulmonary and systemic capillary pressure and the osmotic pressure of pleural fluid and plasma were taken into account. It was assumed that the visceral pleural capillary pressure was the same as the pulmonary arterial pressure.

Black's calculations result in a net pressure of 7 cm H_2O favouring absorption, which would be even greater in the absence of fluid in the pleural space.

The presence of fluid in the normal pleural space has been doubted[19] and is difficult to explain if Black's figures are accepted. These calculations have recently been recognised as an oversimplification,[57 58] and they are not consistent with the anatomy of the human lung as described by Miller and Nagaishi, who showed that although subpleural veins drain, at least in part, into the pulmonary vein, the visceral pleural arteries in man are branches of the bronchial arteries.[2 3] The net hydrostatic pressure in the visceral pleural capillaries must therefore be higher than in the pulmonary circulation but lower than in the systemic circulation. A modification of the theory is necessary to explain how effusions can form with relatively low protein concentrations, and why pleural effusion does not result in pulmonary oedema.[11] The classical theory also tends to overlook the role of the mesothelium in active transport of fluid and the anatomical separation of the visceral and parietal capillaries by mesothelium, submesothelial connective tissue, and the external elastic lamina. Nevertheless, the visceral pleura would appear to have greater absorptive potential than the parietal pleura and probably a considerably lower hydrostatic capillary pressure, which would tend to limit the development of effusions.

Transudates

Transudates occur when the plasma colloid osmotic pressure is reduced, as in hypoalbuminaemia, or when the systemic or pulmonary venous pressure is increased; an additional factor is reduced renal excretion of sodium, which occurs in both cirrhosis and congestive cardiac failure. Transudates are not usually associated with primary pathological conditions of the pleura. The protein concentration is less than 3.0 g/100 ml, corresponding to a specific gravity of 1.016, and the cell count is low. When cells are present, typically they are degenerate mesothelial cells and macrophages with signet ring forms.[61] Polymorphs are absent but lymphocytes may be present, which may be explained by reduced lymphatic flow through the thoracic duct when there is systemic venous hypertension.[55]

Congestive cardiac failure In man a combination of systemic and pulmonary venous hypertension is more likely to cause pleural effusion than is systemic venous hypertension alone. It is therefore common in the congestive cardiac failure of heart disease but rare in right ventricular failure due to chronic lung disease.[55] Effusions in congestive cardiac failure may contain many proliferating mesothelial cells in addition to degenerating forms with vacuolated cytoplasm.[61 63] This would imply damage to the mesothelium, and Spriggs and Boddington suggest that the presence of an appreciable number of mesothelial cells indicates a pulmonary complication such as infarction.[61]

Nephrotic syndrome This is a classic cause of an effusion, which is invariably a transudate, and is caused by severe reduction in plasma colloid osmotic pressure. Pleural effusion develops at a stage when oedema and ascites are already present,[56] indicating that the resorptive potential of the pleura is reduced.

Cirrhosis Pleural effusion in cirrhosis is usually associated with ascites[64] but may occur in its absence.[65 66] Ten per cent of patients with cirrhosis develop a pleural effusion,[64] most frequently on the right side. Studies with radiolabelled albumin have shown that fluid is transferred directly across the diaphragm, presumably in response to the negative intrapleural pressure.[64 67] Lieberman *et al* showed diaphragmatic defects in some of the patients in their study, and suggested that these rather than the transdiaphragmatic lymphatics are the route of the fluid; this is supported by recent reports.[65 66] Although effusions are typically transudates, occasionally proliferating and often atypical mesothelial cells are present in large numbers.[62 63] These cells may appear very similar to malignant cells, and a cytogenetic study of ascitic fluid from patients with alcoholic cirrhosis has shown karyotypic abnormalities indistinguishable from malignancy.[68] The authors suggested that a mutagenic effect of alcohol might be implicated, but abnormal karyotypes have been demonstrated on rare occasions in mesothelial cells from other types of reactive effusions.[69]

Exudates

Exudative pleural effusions form when an acute inflammatory response causes increased permeability of pleural capillaries to protein and cells. The mesothelial cells round up and separate, allowing the passage of cells and protein into the pleural space. Both leucocytes[70] and fibrin[32] can be shown to pass between cells in experimental peritonitis. A further factor, which is often not emphasised, is the obstruction of lymphatic drainage by hilar lymphadenopathy. Exudates may or may not be purulent; the latter type includes eosinophilic and lymphocytic exudates.

NON-PURULENT EXUDATES Non-purulent exudates contain neutrophils, lymphocytes, macrophages, exfoliated mesothelial cells, eosinophils, and basophils, roughly in that order of frequency. The percentage of the cell types varies. Lymphocytes or eosinophils may predominate, for example, in the later stages of a pneumonic effusion.[61]

Pneumonia The incidence of effusion in pneumonia varies with the type of organism and is reviewed in detail by Light.[57] It is much higher with β haemolytic streptococcus (90%) than pneumococcus (40–60%), and occurs in about 20% of cases of viral pneumonia.

Organisms are grown from the fluid in less than half such effusions, with the exception of staphylococcus and *Haemophilus influenzae* in children and *Escherichia coli* and anaerobic organisms in adults. Anaerobic lung infections frequently cause effusions and are often associated with alcoholism and factors predisposing to inhalation. The cell counts are very high, usually over 10×10^6/l, 90% being neutrophils. Exfoliated mesothelial cells are present but are not prominent, possibly reflecting the lack of cell damage and the frequency of complete resolution, which occurs in about 90% of cases. Large, particularly blood stained, effusions may fail to resolve, and if they are not drained lead to fibrous pleurisy and respiratory impairment.[56]

Pulmonary infarction An assessment of the incidence of pleural effusion in pulmonary thromboembolism is complicated by the fact that unrelated causes of effusion may also be present. Bynum and Wilson reported that 40% of patients had effusions directly attributable to thromboembolism when other causes had been excluded, and that only half of these had radiological evidence of pulmonary infarction. Two thirds of those with radiological evidence of infarction had effusions: these were larger, more often blood stained, and more likely to persist.[71] The fluid is blood stained in up to 65% of cases of effusion related to thromboembolism,[72] suggesting that not all infarcts are radiologically visible. Effusions in the absence of infarction may be attributed to transient pulmonary ischaemia, atelectasis, or right sided heart failure. The cell count tends to be high, with a composition that varies with the time from the onset of the disease.[73] There may be a high percentage of neutrophils, in which case the picture is similar to that of a pneumonic effusion. One important difference is the frequent presence of exfoliated mesothelial cells in large numbers, which may be atypical and closely mimic malignant cells,[63 73] probably reflecting ischaemic damage. Most of these effusions resolve, but those associated with radiological evidence of infarction may persist and give rise to localised pleural fibrosis.[71]

Malignancy Malignant infiltration is a common cause of pleural effusion, and the histological and cytological examination of pleural biopsy material and fluid is largely directed towards the identification of malignant cells. Not all such effusions contain malignant cells, and they may show the features of a non-purulent inflammatory exudate, a lymphocytic effusion, or, very occasionally, a transudate.[61] Effusions in which malignant cells cannot be identified may be caused by concomitant pneumonia, congestive heart failure, and hypoproteinaemia,[74] or by the obstructive pneumonitis or bronchiectasis of lung cancer. This is relevant to whether a patient with lung cancer meets the criteria for operability, since even blood stained effusions may be produced by inflammation rather than malignant infiltration.[75] There is also evidence that effusion in lung cancer,[76] malignant lymphoma,[77] and Hodgkin's disease[78] is more likely to be caused by disease of mediastinal lymph nodes than by pleural infiltration by tumour, and this may also be a factor in the development of effusions in other forms of metastic cancer,[79] particularly breast cancer. Goldsmith *et al* reported that effusions in breast cancer were present in 63% of patients with pulmonary lymphangitic spread, but also in 40% of patients without such metastases. Particularly in the latter group, the effusion was more often on the same side as the primary tumour.[80] Seventy five per cent of malignant effusions are caused by lung cancer, breast cancer, or malignant lymphoma[81] and in all three cases the effusions are at sites that share lymphatic drainage with the pleura. Cytological examination gives positive results in 50–60% of clinically malignant effusions. This proportion is increased by 10–20% by the use of cytogenetic investigations[69] or immunocytochemical methods.[82] The remaining patients may well not have direct infiltration of the pleura.

Eosinophilic effusion

An eosinophilic effusion is defined as one in which there are more than 10% of eosinophils and it may occur in pneumonic effusion, particularly those associated with viral and pneumococcal infection; in the latter it tends to develop two to three weeks after the onset of the disease.[83] It is said to be rare in tuberculosis and malignancy, with the exception of Hodgkin's disease.[57] A high percentage of eosinophils has been reported in collagen disease,[83] and is a particular feature of the effusions that occur as a response to pneumothorax. Surgical specimens from patients having a pleurectomy for spontaneous pneumothorax show appreciable swelling and activation of the mesothelial cells, with an infiltrate of eosinophils and histiocytic giant cells. The picture may bear a superficial resemblance to the infiltrate of eosinophilic granuloma (histiocytosis X), and probably represents a direct response of mesothelial cells to the irritant effect of air.[85] Other causes include hypersensitivity to drugs and parasitic infections.[57]

Lymphocytic effusion

A lymphocytic effusion is usually defined as an exudative effusion containing more than 50% of lymphocytes, but much higher percentages are seen in some effusions, particularly in tuberculosis and malignancy. Lymphocytes from malignant effusions cultured with phytohaemagglutinin undergo blast

transformation[86] and form rosettes with sheep erythrocytes.[87] The ratio of T to B lymphocytes is greater in pleural fluid than peripheral blood, suggesting migration of T lymphocytes into effusions in the presence of cancer.[87] A recent study using monoclonal antibodies to T cell subsets has shown that these changes occur in all types of lymphocytic effusions, not only those associated with cancer.[88] The predominant subset in all types of effusion was helper-inducer (OKT4 positive). Tuberculous and malignant effusions also showed a relative increase in the E rosetting, OKT3 negative subset recently described as natural killer cells.[89] Lymphocytes in reactive effusions may be so numerous that they mimic malignant lymphoma or chronic lymphatic leukaemia.[61] Since the latter are most commonly B cell lines, an increase in the ratio of B to T cells in the fluid may be useful in differentiating malignant from benign lymphoid cells.[90]

Tuberculosis Tuberculous pleurisy remains one of the major non-malignant causes of a pleural effusion. Classically, it occurs as a complication of primary infection, and is regarded as an expression of delayed hypersensitivity to bacilli entering the pleural space. The experimental work of Paterson is accepted as the model for the development of tuberculous effusions in man.[91] Tubercle bacilli introduced into the pleura of tuberculin sensitised guinea pigs induce a vigorous pleurisy with effusion, whereas tuberculin negative controls do not have effusions but develop disseminated tuberculosis. This experimental model correlates well with clinical tuberculous pleurisy, as was shown in a clinical and pathological study by Stead *et al*, in which a focal pulmonary tuberculosis lesion was found in direct continuity with the pleura in 13 out of 15 men undergoing thoracotomy for this condition.[92] The pleura showed extensive replacement by a layer of tuberculous granulation tissue, which was decorticated. Effusions occur less frequently in postprimary tuberculosis, but the pathology is similar.

Despite the extensive and severe pleural reaction, most tuberculosis effusions resolve spontaneously even in the absence of treatment, although 65% of the patients who recover initially develop pulmonary or extrapulmonary tuberculosis within the following five years.[93] Although tuberculous pleurisy presents as an acute illness in young people, the onset is more insidious in older patients[94]; and now that primary tuberculosis occurs more frequently in an older age group a tuberculous effusion is more likely to be confused with other forms.[95]

At the very earliest stage there are neutrophils in the fluid, but usually there is a high proportion of lymphocytes. Mesothelial cells are characteristically absent, which may suggest the diagnosis.[96] Abram's needle biopsy yields 70–80% positive results in tuberculosis[95 97–99] because pleural disease is usually widespread. The lack of mesothelial cells can be partly explained by destruction of mesothelium, but this is not entirely consistent with the clinical resolution that often occurs. Spriggs and Boddington[96] quote an early, unsubstantiated histological study by Saltykow,[100] in which an intact mesothelium was seen under a fibrinous exudate; and this may explain the lack of mesothelial cells in the pleural fluid.[83] Others have shown that mesothelial cells may be present in tuberculous effusions, particularly where there is active disease of the pleural surface.[62 63] Sometimes they show atypical proliferative changes. Possibly the hilar lymph node disease, which is prominent in primary but far less so in postprimary tuberculosis,[101] is important either as an additional source of bacilli entering the pleural space[102] or as a cause of obstruction to lymphatic drainage. A reduced clearance of protein has been found in both experimental[103] and clinical tuberculous pleurisy.[104]

Yellow nail syndrome Lymphocytic effusion is a feature of the yellow nail syndrome, in which there is hypoplasia of lymphatics.[105] It must be distinguished from chylothorax, which occurs when the thoracic duct ruptures or is obstructed.[106 56] Chyle is rich in lymphocytes, but also contains triglycerides in a greater quantitity than is ever found in the blood. The most common causes are trauma, thoracic operations, and malignant lymphoma. It is also a feature of lymphangioleiomatosis.[107]

PURULENT EFFUSION In empyema fluid there are large numbers of dead and dying neutrophils, with many smeared nuclei. The appearance is quite different from that of a non-purulent exudate, and signifies bacterial infection of the pleural membrane itself, which can be demonstrated by culture of the fluid. Tuberculous empyema produces a very similar picture.[61] Mesothelial cells are seldom observed except in the very early stages. The widespread destruction of the mesothelial lining accounts for the fibrous scarring that invariably accompanies this condition.

Other causes of effusion

Other causes of effusion are reviewed extensively elsewhere,[55–57] and will not be described in detail. Effusions occur in rheumatoid disease,[108] systemic lupus erythematosus,[109] myxoedema,[110] uraemia,[111] postmyocardial infarction syndrome,[112] sarcoidosis,[113] mediastinal irradiation,[114] and asbestos exposure. Peritoneal effusions of many types may be associated with pleural effusions, including pancreatitis,[115] subphrenic abcess,[116] peritoneal dialysis,[117] viral hepatitis,[118] and the Meigs-Salmon syndrome.[119]

A variable proportion of cases of pleural effusion remains unexplained. In the past idiopathic effusions, particularly in young people, would have been considered tuberculous unless proved otherwise.[93] Recently there has been emphasis on asbestos exposure as a possible cause,[120 121] but an extensive survey of patients with pleural thickening on radiographs failed to show a significant association with asbestos exposure.[122] A proportion of patients with unexplained pleural effusions subsequently develop malignant lymphoma, mesothelioma, or carcinoma.[123]

PLEURAL FIBROSIS

The mechanisms concerned in mesothelial injury and repair and the circumstances in which pleural effusion may undergo fibrous organisation are important in the pathogenesis of pleural fibrosis. This may take several forms, which may or may not be associated with mesothelial regeneration.

Pleural adhesions

Localised damage to the pleura, from whatever cause, may result in minor degrees of pleural fibrosis or adhesions between the lung and the chest wall, which become relined by mesothelium derived from surrounding mesothelial cells.[41] Pleural adhesions have less clinical importance than those that form in the peritoneum, but they may result in the development of abnormal communications between the pulmonary and chest wall vasculature and lymphatic drainage. These may play a part in the spread of disease and the pathogenesis of air embolism and metastatic cerebral abscess.[45]

Diffuse fibrosing pleurisy

At its most extensive, fibrosing pleurisy totally obliterates the pleural cavity, with limitation of chest movement and consequent respiratory disability. It may follow any prolonged exudative or blood stained effusion, but is particularly liable to occur in tuberculous pleurisy, empyema, and asbestos exposure. Rarely, it is associated with rheumatoid effusions,[124] uraemia,[111] pancreatitis,[115] or traumatic haemothorax.[45]

Whatever the cause of the fibrosis, the pleural lining is replaced by a layer of dense collagenous tissue, which may be several centimetres thick and extends from the interstitial layer deep to the external elastic lamina, often affecting the interlobular septa. It can be stripped easily from the lung (unless there is underlying pulmonary fibrosis) and from the diaphragm, but with much more difficulty from the chest wall, where it may infiltrate the intercostal muscle. The mediastinal pleura is usually not affected in reactive pleurisy, in contrast to malignant mesothelioma.[45] The superficial layer is composed of organising purulent exudate, tuberculous granulation tissue, rheumatoid nodules, or fibrinosanguinous exudate, depending on the aetiology. Histologically, benign fibrous pleurisy may be difficult to distinguish from mesenchymal malignant mesothelioma. The intact elastic lamina may be helpful,[125] and the orientation of the granulation tissue is less haphazard than in malignant mesothelioma.[126] Fibrous pleurisy appears to be entirely mesenchymal, whereas the fibroblastic component of mesothelioma often looks more epithelial and may include cells that express epithelial cell markers.[127] And although mesothelial cells may form clefts in fibrous pleurisy,[128] they are not prominent,[92 126] presumably because they have been largely destroyed in the original inflammatory process.

Benign asbestos pleural effusion and fibrosis

Pleural fibrosis is a feature of pulmonary asbestosis,[129 130] but has only recently been recognised as a cause of restrictive lung disease in the absence of appreciable pulmonary fibrosis.[131 132] Diffuse fibrosis may follow acute asbestos pleurisy with effusion,[128] and is probably caused by direct damage to the mesothelium. Asbestos is known to have a direct cytotoxic effect on mesothelial cells,[22] but the mechanism whereby the fibres reach the pleural space is unknown. The association of asbestos exposure with benign pleural effusion was first reported by Eisenstadt[133] and further cases were described by Gaensler and Kaplan[134] and Mattson, who suggested that asbestos is a frequent cause of apparently idiopathic effusions.[120] Such recurrent and often blood-stained effusions frequently lead to fibrosis. Although this condition is relatively benign (in one series patients were followed for up to nine years), decortication may be required and a considerable number of patients later develop mesothelioma or lung cancer.[135]

Pleural plaques

Hyaline pleural plaques must be distinguished from pleural fibrosis, and they probably arise by a completely different mechanism. They consist of raised, sharply defined, serpiginous, shiny yellow white lesions, which are not associated with adhesions and can be readily stripped from the chest wall.[136] Microscopially they are composed of avascular, poorly cellular collagen, which shows hyaline degeneration and often calcification. They are most frequently found on the posterior costal parietal pleura, where they tend to follow the lines of the ribs, and the diaphragmatic pleura, where they are often firmly adherent to the central tendon.[137] They also occur on the mediastinal pleura and cardiac fold but rarely on the visceral

pleura. The incidence of hyaline plaques in routine necropsies has been found to be 11–12% in urban communities[137–139] and almost 40% in a mining community in Finland.[140] In these series they were strongly associated with an occupational and environmental exposure to all types of asbestos and with the presence of asbestos bodies in lung tissue. Analysis of pleural plaques has revealed fine asbestos fibres, less than 2 μm long, mainly in the calcified central zones.[141] Some plaques occur in the apparent absence of asbestos exposure,[142 143] but may be related to fibres in the environment such as the amphibole asbestos tremolite.[130] and also non-asbestos minerals. Asbestos fibre counts of the lungs of patients with pleural plaques show a relative predominance of commercial amphiboles (crocidolite and amosite), contrasting with the predominance of chrysotile fibres found in controls.[144] The presence of plaques does not correlate with the degree of pulmonary asbestosis.[130]

The sites of formation of pleural plaques coincide with pathways of lympathic drainage of the pleura and in particular with the Kampmeier foci, which are the sites of uptake of particulate matter into the parietal pleural lymphatics. The pathogenesis of pleural plaques is incompletely understood but Thompson has shown that they develop deep to an intact mesothelium, which suggests that direct mesothelial damage does not play a part in their development.[145] This is supported by the absence of surface adhesions[146] and of mesothelial hyperplasia.[147] Fibres less than 5 μm are readily taken up by macrophages[22] and are carried in lymphatics to hilar and mediastinal lymph nodes. It has been postulated that they might also reach the parietal pleura via lymphatics[138]; but this seems unlikely as it would require retrograde flow against valves, and there is no reason for there to be lymphatic obstruction. It seems more likely that the fibres are held up at the site of uptake into the lymphatics; but how they reach the pleural space, in the absence of pleural or pulmonary scarring, remains unexplained—although Thompson has suggested direct penetration through the visceral pleura.[145] A recent experimental study has shown that asbestos fibres introduced directly into the pleural space in rabbits produced extensive plaques; but these did not form if the animals had previously been treated with nitrogen mustard, when a severe pleurisy with fibrosis developed.This study suggests that the formation of plaques depends on mobilisation of pleural macrophages, which is prevented in the animals treated with nitrogen mustard as a secondary effect of inhibiting polymorphs from entering the pleural space.[148] This experimental work may be relevant to clinical conditions in that the immunological abnormalities that have been described in asbestosis[149] have not been observed in people with pleural plaques.[150]

Shrinking pleuritis with rounded atelectasis (folded lung)

The association of a visceral pleural plaque or an area of localised fibrosis with an underlying area of atelectasis can give a highly characteristic radiological appearance of a rounded pleural based mass with curvilinear shadows extending towards the hilum,[151] which can simulate a peripheral tumour.[152] This lesion was first described by Blesovsky in three patients, all of whom had some degree of occupational exposure to asbestos.[153] Thoracotomy revealed an area of pleural fibrosis overlying the atelectatic segment, which readily re-expanded after removal of the plaque of fibrosis. Long term follow up in a recent series has shown recurrence after surgery in one patient.[154] Subsequent cases confirmed the association with pleural plaques,[151 155] but not all patients had a history of asbestos exposure.[151] Dernevik and coworkers have reported immunological abnormalities in patients with this syndrome who had been exposed to asbestos and also to quartz.[156] The visceral lesion has usually been described as a glistening fibrous plaque, typically not adherent to the overlying parietal pleura.[151] Probably the atelectasis results from the contraction of collagen that occurs during the development of the plaque,[157] and it is unlikely to result from pleural effusion as this has seldom been present in reported cases.[155 158] This view of the pathogenesis of folded lung is consistent with the hypothesis that pleural plaques are submesothelial structures, not associated with mesothelial damage.

Localised fibrous mesothelioma

The term localised fibrous mesothelioma is commonly used to describe a rare group of primary tumours unrelated to asbestos exposure, which arise in the visceral or parietal pleura, often as pedunculated masses. They are composed of immature mesenchymal spindle cells admixed with mature hyalinised collagen and sometimes areas resembling haemangiopericytomas. Large, thin walled blood vessels are often present. Although usually covered by normal mesothelium, they frequently contain clefts of bronchiolar epithelium or mesothelium towards the periphery.[159] Associated systemic manifestations include finger clubbing[160] and hypoglycaemia.[161] Although most are benign, a small proportion show histological evidence of malignancy and may recur; but they very rarely metastasise.[162] Most authors now hold the view that these tumours are derived from submesothelial mesenchymal cells[125 159 163] and should be clearly distinguished from true mesotheliomas, as originally proposed by Klemperer and Rabin.[164]

Some ultrastructural studies, however, favour a mesothelial origin.[165-167] This view was supported by the belief that regenerating mesothelial cells were derived from submesothelial fibroblasts,[44 45] which has now been shown to be highly unlikely.[41 42]

MESOTHELIAL PROLIFERATION

The ability of mesothelial cells to proliferate and mimic primary or secondary neoplasia is a major problem in the interpretation of cytological preparations and biopsy material. It can be understood far better on the basis of the functional changes that have already been discussed with reference to mesothelial damage, exfoliation, and regeneration. A distinction must be made between the changes seen in exfoliated cells and those seen in the intact lining of the pleural surface.

Proliferation of exfoliated mesothelial cells

Mesothelial cells are not evident in washing from normal serous surfaces[61] but may be abundant in many forms of effusion. Their morphology changes when they exfoliate, and nuclei become active, often with one or more prominent nucleoli. Mitoses may be present, as the fluid acts as a tissue culture medium.[63] Surface microvilli and pinocytotic vesicles tend to disappear, presumably because their function is altered; and surfaces either are smooth or have characteristic surface blebs.[24] The nuclei may become hyperchromatic and the cytoplasm vacuolated.[61] Although some of these changes are compatible with a response to injury, others are more suggestive of active regeneration. Exfoliated mesothelial cells may also have a limited phagocytic function.

Metastatic malignant cells can usually be distinguished from mesothelial cells as a separate population with malignant nuclear characteristics and features that sometimes identify specific tumour types.[63] These cells are shown by cytogenetic analysis to have clonal karyotypic abnormalities—a reliable though time consuming way of identifying malignant cells in effusions, which can, however, be used to supplement the cytological diagnosis.[69]

It must be emphasised that mesothelial cells may show extreme nuclear atypia, possibly as a result of cell damage, and occasionally isolated karyotypic abnormalities similar to those seen in malignant cells,[68 69] resulting in an occasional "false positive" diagnosis of malignancy. These atypical mesothelial cells may show obvious signs of response to injury, and have homogenous, hyperchromatic, or multiple nuclei; but there may be a more coarse and active chromatin pattern with multiple nucleoli, closely resembling malignancy. They are typically seen in pulmonary infarction, cirrhosis, and uraemia, and as a result of chemotherapy or irradiation.[63] They can be distinguished from metastatic carcinoma because they do not form a separate population, but are part of a range of appearances that includes normal mesothelial cells. Typical mesothelial cells are recognised by the characteristic, sharply defined cytoplasm, condensed around the nucleus, and often separated from adjacent cells by intercellular gaps.[63] This type of mesothelial atypia is less often encountered in histological sections because the mesothelial cells will have exfoliated. When these cells line the inflamed surface in biopsy specimens they do not have the infiltrative pattern of a tumour and are less likely to be confused with malignancy. Hyperchromatic mesothelial cells may also be associated with infiltration by metastatic carcinoma,[126] and the presence of atypical reactive mesothelial cells in effusions does not exclude carcinoma.

Benign mesothelial cells may also mimic carcinoma or mesothelioma when small papillary aggregates are present. These are a feature of regeneration, and are seen in many forms of effusion, including those resulting from tuberculosis and infarction.[62 63 73] The aggregates are usually smaller than those of papillary carcinoma or mesothelioma. The latter, with which they are most likely to be confused, are three dimensional and form tightly packed "morulae" of cells with nuclei bulging from the surface,[168 169] whereas benign cell aggregates are usually in flat squamoid sheets.[170] Although cells with malignant characteristics can usually be identified in malignant mesothelioma, particularly in cells separated from the clumps, one of the difficulties in making a cytological diagnosis of this tumour is that the nuclei sometimes appear deceptively benign.[63 169]

Papillary clusters of mesothelial cells also occur in the benign proliferative mesothelial lesions that are occasionally associated with effusion[171] (see below). There is no doubt that the cytological appearance of mesothelioma overlaps with that of some of these benign processes as well as with adenocarcinoma. It is therefore unwise to give a certain cytological diagnosis of mesothelioma without close clinical correlation,[170] although a probable diagnosis can often be made and is an indication for definitive biopsy.

Although mesothelial cells are mesenchymal in origin they contain cytokeratins,[172] but do not usually express epithelial cells markers, such as carcinoembryonic antigen, human milk fat globule, or Ca 1.[82 173] Identification of these markers by immunocytochemical techniques has proved useful in identifying malignant cells not recognisable by morphology alone. None of the antisera used in these techniques are entirely specific, and agreement between immunocytochemical and morphological findings is necessary for avoiding false positive diagnoses.

Proliferation of surface mesothelium

Benign proliferative mesothelial lesions occur in the peritoneum,[174] pericardium,[175] hernial sacs,[176] and pleura.[177 178] A series of five cases has been reported recently, with effusions in one or more body cavities, including the pleura, in three.[171] They consist of fronds of mature connective tissue lined by benign mesothelium. There is no biphasic pattern, and they are histologically benign, although they can give rise to false positive cytological diagnoses of malignancy.[171 175] They may be manifestations of regeneration and fibrosis rather than true tumours.[176] Although true papillary structures with a loose connective tissue core are seldom seen in small biopsy specimens in the absence of mesothelioma,[126] they should not be regarded as mesotheliomatous in the absence of unequivocal invasion.

A combination of closely applied fibrous bands and mesothelial regeneration may appear similar to these benign nodular lesions, and may be difficult to distinguish from malignant mesothelioma, particularly in patients with a history of exposure to asbestos. In biopsy material the regenerating mesothelium is heaped up and multilayered on the serosal surface,[126] but it becomes single layered as it relines the fibrous bands. Entrapment of islands of surviving mesothelium beneath the fibrous connective tissue can be distinguished from true invasion by the benign appearance of the cells.[170] The key to appreciating the benign nature of the process again lies in recognising that fibrosis and the mesothelial regeneration are separate processes, whereas malignant mesothelioma shows simultaneous differentiation towards mesenchymal and epithelial structures.[179]

Conclusion

The pleura is a remarkable structure, adapted to form a lubricated surface that allows the lungs to expand and contract without resistance, and to resist the accumulation of fluid despite negative intrapleural pressure. Partly because of its extreme sensitivity to a wide variety of agents, Barrett has described the pleura as "an anatomical luxury and a pathological hazard."[45] Elephants and other members of the Proboscideae, which develop high intrathoracic negative pressures, lose their pleural spaces during fetal life and apparently show no respiratory disability. Many of the enigmas of the pleural reponse to injury result from the divergent functions of mesothelium, which shows partial differentiation towards epithelium though derived entirely from mesenchyme. A distinction must be drawn between the mesothelial response to injury and the process of fibrous repair that takes over when the mesothelium is irreversibly destroyed.

References

1 Willis RA. *The borderland of embryology and pathology*. London: Butterworth, 1958: ch 3.
2 Nagaishi C. *Functional anatomy and histology of the lung*. Baltimore: University Park Press: 1972.
3 Miller WS. *The lung*. 2nd ed. Springfield, Illinois: Charles C Thomas, 1947.
4 Whitaker D, Papadimitrou JM, Walters MN-I. The mesothelium and its reaction: a review. *CRC Crit Rev Toxicol* 1982;**10**:81–144.
5 Allen L. The peritoneal stomata. *Anat Rec* 1936;**67**:89–103.
6 Leak LV, Rahil K. Permeability of the diaphragmatic mesothelium: the ultrastructural basis for "stomata." *Am J Anat* 1978;**151**:557–94.
7 Wang N-S. The preformed stomas connecting the pleural cavity and the lymphatics in the parietal pleura. *Am Rev Respir Dis* 1975;**111**:12–20.
8 Kampmeier F. Concerning certain mesothelial thickenings and vascular plexuses of the mediastinal pleura, associated with histiocyte and fat-cell production, in the human newborn. *Anat Rec* 1928;**39**:201–13.
9 Cooray GH. Defensive mechanisms in the mediastinum, with special reference to the mechanics of pleural absorption. *J Pathol Bacteriol* 1949;**61**:551–67.
10 Courtice FC, Simmonds WJ. Physiological significance of lymph drainage of the serous cavities and lungs. *Physiol Rev* 1954;**34**:419–48.
11 Stewart PB. The rate of formation and lymphatic removal of fluid in pleural effusions. *J Clin Invest* 1963;**42**:258–62.
12 Von Hayek H. *The human lung*. (Translated Krahl VE). New York: Hafner, 1960.
13 Simionescu M, Simionescu N. Organisation of cell junctions in the peritoneal mesothelium. *J Cell Biol* 1977;**74**:98–110.
14 Wang N-S. The regional difference of pleural mesothelial cells in rabbits. *Am Rev Respir Dis* 1974;**110**:623–33.
15 Cotran RS, Karnovsky MJ. Ultrastructural studies on the permeability of the mesothelium to horseradish peroxidase. *J Cell Biol* 1968;**37**:123–37.
16 Starling EH, Tubby AH. On absorption from and secretion into the serious cavities. *J Physiol* 1894;**16**:140–55.
17 Andrews PM, Porter KR. The ultrastructural morphology and possible functional significance of mesothelial microvilli. *Anat Rec* 1973;**177**:409–26.
18 Hills BA, Butler BD, Barrow RE. Boundary lubrication imparted by pleural surfactants and their identification. *J Appl Physiol* 1982;**53**:463–9.
19 Hills BA. The pleural interface. *Thorax* 1985;**40**:1–8.
20 Castor CW, Naylor B. Characteristics of normal and malignant human mesothelial cells studied in vitro. *Lab Invest* 1972;**20**:437–43.
21 Harvey W, Amlot PL. Collagen production by human mesothelial cells in vitro. *J Pathol* 1983;**139**:337–47.
22 Allison AC. Experimental methods – cell and tissue culture: effects of asbestos particles on macrophages, mesothelial cells and fibroblasts. In: Bogovsky P, Gilson JC, Timbrell V, Wagner JC, eds. *Biological effects of asbestos*. Lyon: International Agency for Research on Cancer, 1973:89–93.
23 Antony VB, Repine JE, Sahn SA. Origin and kinetics of

macrophages in experimental BCG pleurisy [abstract]. *Am Rev Respir Dis* 1984;**129**, suppl: A8.
24 Domagala W, Koss LG. Configurations of surfaces of cells in effusions by scanning electron microscopy. In: Koss LG, Coleman DV, eds. *Advances in clinical cytology*.London: Butterworth, 1981:270–313.
25 Efrati P, Nir E. Morphological and cytochemical investigation of human mesothelial cells from pleural and peritoneal effusions. A light and electron microscopy study. *Israel J Med Sci* 1976;**12**:662–73.
26 Clausen PP, Hojgaard K, Thommesen N. The diagnostic value of cytochemical staining for non-specific esterase in the search for cancer cells in effusions. *Acta Pathol Microbiol Scand* (sect A) 1979;**87**:347–52.
27 Roujeau J, Nouhnejade P, Hoang Van C, Ferrand-Lougnon J. Différenciation cyto-enzymologique entre cellules macrophages et mésotheliales dans les épanchements des séreuses. *Arch Anat Cytol Pathol* 1979;**27**:217–20.
28 Herbert A, Gallagher PJ. Interpretation of pleural biopsy specimens and aspirates with the immunoperoxidase technique. *Thorax* 1982;**37**:822–7.
29 Thorsrud GK. The reaction of the pleural mesothelium to artificial pneumothorax in rabbits. *Acta Chir Scand* 1961;**121**:8–12.
30 Ryan GB, Grobety J, Majno G. Mesothelial injury and recovery. *Am J Pathol* 1973;**71**:93–112.
31 Ivanova VF, Puzyrev AA. Autoradiographic study of proliferation of the mesothelium of white mice in experiment [English abstract]. *Arkh Anat Gistol Embriol* 1977;**72**:10–7.
32 Baradi AF, Campbell WG. Exudative peritonitis induced in mice by bovine serum albumin. *Arch Pathol* 1974;**97**:2–12.
33 Schade DS, Williamson JR. The pathogenesis of peritoneal adhesions: an ultrastructural study. *Ann Surg* 1968;**167**:500–10.
34 Hertzler AE. *The peritoneum*. Vol 1. St Louis: CV Mosby, 1919: ch 5.
35 Williams DC. The peritoneum. A plea for a change in attitude towards this membrane. *Br J Surg* 1955; **42**:401–5.
36 Ellis H, Harrison W, Hugh TB. The healing of peritoneum under normal and pathological conditions. *Br J Surg* 1965;**52**:471–6.
37 Johnson FR, Whitting HW. Repair of parietal peritoneum. *Br J Surg* 1962;**49**:653–60.
38 Eskeland G. Regeneration of parietal peritoneum in rats. 1. A light microscopic study. *Acta Pathol Microbiol Scand* 1966;**68**:355–78.
39 Eskeland G, Kjaerheim A. Regeneration of parietal peritoneum in rats. 2. An electron microscopic study. *Acta Pathol Microbiol Scand* 1966;**68**:379–95.
40 Watters WB, Buck RC. Scanning electron microscopy of mesothelial regeneration in the rat. *Lab Invest* 1972;**26**:604–9.
41 Whitaker D, Papadimitrou JM. Mesothelial healing: morphological and kinetic investigations. *J Pathol* 1985;**145**:159–75.
42 Cameron GR, Hassan SM, De SN. Repair of Glisson's capsule after tangential wounds of the liver. *J Pathol Bact* 1957;**73**:1–10.
43 Raftery AT. Regeneration of parietal and visceral peritoneum. A light microscopical study. *Br J Surg* 1973;**60**:293–9.
44 Raftery AT. Regeneration of parietal and visceral peritoneum in the immature animal: a light and electron microscopical study. *Br J Surg* 1973;**60**:969–75.
45 Barrett NR. The pleura, with special reference to fibrothorax. *Thorax* 1970;**25**:515–24.
46 Ryan GB, Grobety J, Majno G. Postoperative peritoneal adhesions. A study of the mechanisms. *Am J Pathol* 1971;**65**:117–48.
47 Buckman RF, Woods M, Sargent L, Gervin AS. A unifying pathogenetic mechanism in the etiology of intraperitoneal adhesions. *J Surg Res* 1976;**20**:1–5.
48 Bridges JB, Johnson FR, Whitting HW. Peritoneal adhesion formation. *Acta Anat (Basel)* 1965;**61**:203–12.
49 Ellis H. The aetiology of post-operative abdominal adhesions. An experimental study. *Br J Surg* 1962;**50**:10–6.
50 Myhre-Jensen O, Larsen SB, Astrup T. Fibrinolytic activity in serosal and synovial membranes. *Arch Pathol* 1969;**88**:623–30.
51 Porter JM, Ball AP, Silver D. Mesothelial fibrinolysis. *J Thorac Cardiovasc Surg* 1971;**62**:725–30.
52 Whitaker D, Papadimitrou JM, Walters MN-I. The mesothelium: its fibrinolytic properties. *J Pathol* 1982;**136**:291–9.
53 Raftery AT. Regeneration of peritoneum: a fibrinolytic study. *J Anat* 1979;**129**:659–64.
54 Clauss RH, Yacoubian H, Barker HG. Dynamics of pleural effusions. *Surg Forum* 1956;**7**:201–4.
55 Black LF. Pleural effusion. In: Staub NC, Taylor AE, eds. *Edema*. New York: Raven Press, 1984: 695–717.
56 Lowell JR. *Pleural effusions: a comprehensive review*. Baltimore: University Park Press, 1977.
57 Light RW. *Pleural diseases*. Philadelphia: Lea and Febiger, 1983.
58 Wegmann JA, Forshee T. Malignant pleural effusions: pertinent issues. *Heart Lung* 1983;**12**:533–42.
59 Agostoni E, Taglietti A, Setnikar I. Absorption force of the capillaries of the visceral pleura in determination of the intrapleural pressure. *Am J Physiol* 1957; **191**:277–82.
60 Black LF. The pleural space and pleural fluid. *Mayo Clin Proc* 1972;**47**:493–506.
61 Spriggs AI, Boddington MM. *The cytology of effusions, pleural, pericardial and peritoneal, and of cerebrospinal fluid*. 2nd ed. London: William Heinemann, 1968.
62 Luse SA, Reagan JW. A histological study of effusions. 1: Effusions not associated with malignant tumors. *Cancer* 1954;**7**:1155–66.
63 Koss LG. *Diagnostic cytology and its histopathologic basis*. 3rd ed. Philadelphia: JB Lippincott, 1979: 878–910.
64 Johnston RF, Loo RV. Hepatic hydrothorax. Studies to determine the source of the fluid and report of thirteen cases. *Ann Intern Med* 1964;**61**:385–401.
65 Rubinstein D, McInnes IE, Dudley FJ. Hepatic hydrothorax in the absence of clinical ascites: diagnosis and management. *Gastroenterology* 1985;**88**:188–91.
66 Hartz RS, Bomalaski J, LoCicero J, III, Murphy RL. Pleural ascites without abdominal fluid: surgical considerations. *J Thorac Cardiovasc Surg* 1984;**87**:141–3.
67 Lieberman FL, Hidemura R, Peters RL, Reynolds TB. Pathogenesis and treatment of hydrothorax complicating cirrhosis with ascites. *Ann Intern Med* 1966;**64**:341–51.
68 To A, Boyo-Ekwueme HT, Posnansky MC, Coleman DV. Chromosomal abnormalities in ascitic fluid from

patients with alcoholic cirrhosis. *Br Med J* 1981;**282**:1659–60.
69 Watts KC, Boyo-Ekwueme HT, To A, Posnansky MC, Coleman DV. Chromosome studies on cells cultured from serous effusions. Use in routine cytologic practice. *Acta Cytol* 1983;**27**:38–44.
70 Forteza-Vila J, Mohr W, Ricker T, Beneke G. SEM investigations on mesothelial cells in an experimental peritonitis. *Virch Arch (Cell Pathol)* 1971;**8**:225–9.
71 Bynum LJ, Wilson JE, III. Radiological featuers of pleural effusion in pulmonary embolism. *Am Rev Respir Dis* 1978;**117**:829–34.
72 Bynum LJ, Wilson JE, III. Characteristics of pleural effusions associated with pulmonary embolism. *Arch Intern Med* 1976;**136**:159–66.
73 Winckler CF, Yam LT. Cytologic changes of pleural effusion in pulmonary embolism. *Arch Intern Med* 1976;**136**:1195–7.
74 Frist B, Kahan AV, Koss LG. Comparison of the diagnostic values of biopsies of the pleura and cytologic evaluation of pleural fluids. *Am J Clin Pathol* 1979;**72**:48–51.
75 Broghamer WL, Richardson ME, Faurest SE. Malignancy-associated serosanguinous pleural effusions. *Acta Cytol* 1984;**28**:46–50.
76 Brinkman GL. The significance of pleural effusion complicating otherwise operable bronchogenic carcinoma. *Chest* 1959;**36**:152–4.
77 Weick JK, Kiely JM, Harrison EG jun, Carr DT, Scanlon PW. Pleural effusion in lymphoma. *Cancer* 1973;**31**:848–53.
78 Stolberg HO, Patt NL, MacEwen KF, Warwick OH, Brown TC. Hodgkin's disease of the lung. Roentgenologic-pathologic correlation. *AJR* 1964; **92**:96–115.
79 Meyer PC, Metastatic carcinoma of the pleura. *Thorax* 1966;**21**:437–43.
80 Goldsmith HS, Bailey HD, Callahan EL Beattie EJ jun. Pulmonary lymphangitic metastases from breast carcinoma. *Arch Surg* 1967;**94**:483–8.
81 Dhillon DP, Shapiro SG. Malignant pleural effusions. *Br J Hosp Med* 1983;**29**:506–9.
82 Ghosh AK, Spriggs AI, Taylor-Papadimitrou J, Mason DM. Immunocytochemical staining of cells in pleural and peritoneal effusions with a panel of monoclonal antibodies. *J Clin Pathol* 1983;**36**:1154–64.
83 Light RW, Erozan YS, Ball WC jun. Cells in pleural fluid. Their value in differential diagnosis. *Arch Intern Med* 1973;**132**:854–60.
84 Kokkola K, Valta R. Aetiology and findings in eosinophilic pleural effusions. *Scand J Respir Dis* 1974;**89**, suppl:159–65.
85 Askin FB, McCann BG, Kuhn C. Reactive eosinophilic pleuritis: a lesion to be distinguished from pulmonary eosinophilic granuloma. *Arch Pathol Lab Med* 1977;**101**:187–91.
86 Cardozo EL, Harting MC. On the function of lymphocytes in malignant effusions. *Acta Cytol* 1972;**16**:307–13.
87 Domagala W, Emeson EE, Koss LG. Distribution of T-lymphocytes and B-lymphocytes in peripheral blood and effusions of patients with cancer. *J Natl Cancer Inst* 1978;**61**:295–300.
88 Kochman S, Bernard J, Lavaud F, Cazabat A, Dubois de Montreynaud JM. T-lymphocyte subsets in pleural fluids: discrimination according to traditional and monoclonal antibody-defined markers. *Eur J Respir Dis* 1984;**65**:586–91.
89 Beverley PCL, Callard RE. Distinctive functional characteristics of human "T" lymphocytes defined by E-rosetting or a monoclonal anti-T-cell antibody. *Eur J Immunol* 1981;**11**:329–34.
90 Krajewski AS, Dewar AE, Ramage EF. T and B lymphocyte markers in effusions of patients with non-Hodgkin's lymphoma. *J Clin Pathol* 1982;**35**:1216–9.
91 Paterson RC. The pleural reaction to inoculation with tubercle bacilli in vaccinated and normal guinea pigs. *Am Rev Tuberc* 1917;**1**:353–71.
92 Stead WE, Eichenholz A, Stauss H-K. Operative and pathologic findings in twenty-four patients with syndrome of idiopathic pleurisy with effusion presumably tuberculous. *Am Rev Tuberc* 1955;**71**:473–502.
93 Roper WH, Waring JJ. Primary serofibinous pleural effusion in military personnel. *Am Rev Tuberc* 1955;**71**:616–34.
94 Levine H, Szanto PB, Cugell DW. Tuberculous pleurisy. An acute illness. *Arch Intern Med* 1968;**122**:329–32.
95 Berger HW, Mejia E. Tuberclous pleurisy. *Chest* 1973;**63**:88–92.
96 Spriggs AI, Boddington MM. Absence of mesothelial cells from tuberculous pleural effusions. *Thorax* 1960;**15**:169–71.
97 Scerbo J, Keltz H, Stone DJ. A prospective study of closed pleural biopsies. *JAMA* 1971;**218**:377–80.
98 Yam LT. Diagnostic significance of lymphocytes in pleural effusions. *Ann Intern Med* 1967;**66**:972–82.
99 Mestitz P, Purves MJ, Pollard AC. Pleural biopsy in the diagnosis of pleural effusion. A report of 200 cases. *Lancet* 1958;ii:1349–53.
100 Saltykow S. Beitrag zur Histologie der Entzürdung der serösen Häute. *Beitr Pathol Anat* 1901;**29**:233–50.
101 Seal RME. The pathology of tuberculosis. *Br J Hosp Med* 1971;**5**:783–92.
102 Erwin GS. Pleural effusion arising from tuberculous tracheo-bronchial adenitis (primary effusions). *Tubercle* 1944;**25**:44–50.
103 Allen JC, Apicella MA. Experimental pleural effusion as a manifestation of delayed hypersensitivity to tuberculin PPD. *J Immunol* 1968;**101**:481–7.
104 Leckie WJH, Tothill P. Albumin turnover in pleural effusions. *Clin Sci* 1965;**29**:339–52.
105 Mambretti-Zumwalt J, Seidman JM, Higano N. Yellow nail syndrome: complete triad with pleural protein turnover studies. *South Med J* 1980;**73**:995–7.
106 MacFarlane JR, Holman CW. Chylothorax. *Am Rev Respir Dis* 1972;**105**:287–91.
107 Corrin B, Leibow AA, Friedman PJ. Pulmonary lymphangioleiomatosis. A review. *Am J Pathol* 1975;**79**:348–82.
108 Scully RE. Case records of the Massachusetts General Hospital, case 27–1982. *N Engl J Med* 1982;**307**:104–12.
109 Good JT jun, King TE, Antony VB, Sahn SA. Lupus pleuritis. Clinical features and pleural fluid characteristics with special reference to pleural fluid antinuclear antibodies. *Chest* 1983;**84**:714–8.
110 Brown SD, Brashear RE, Schnute RB. Pleural effusions in a young woman with myxedema. *Arch Intern Med* 1983;**143**:1458–60.
111 Gilbert L, Frankel H, Mankowitz BJ. Fibrinous uraemic pleuritis: a surgical entity. *Chest* 1975;**67**:53–6.
112 Dressler W. The post-myocardial infarction syndrome.

Arch Intern Med 1959;**203**:28–42.
113 Nicholls AJ, Friend JAR, Legge JS. Sarcoid pleural effusion: three cases and review of the literature. *Thorax* 1980;**35**:277–81.
114 Whitcomb ME, Schwarz MI. Pleural effusion complicating intensive mediastinal radiation therapy. *Am Rev Respir Dis* 1971;**103**:100–7.
115 Dewan NA, Kinney WW, O'Donohue WJ. Chronic massive pancreatic pleural effusion. *Chest* 1984;**85**:497–501.
116 Carter R, Brewer LA. Subphrenic abcess: a thoraco-abdominal-clinical complex. *Am J Surg* 1964;**108**: 165–74.
117 Edwards SR, Unger AM. Acute hydrothorax—a new complication of peritoneal dialysis. *JAMA* 1967;**199**:853–5.
118 Owen RL, Shapiro H. Pleural effusions rash, and anergy in icteric hepatitis. *N Engl J Med* 1974;**291**:963.
119 Meigs JV, Cass JW. Fibroma of the ovary with ascites and hydrothorax. *Am J Obstet Gynecol* 1937;**33**:249–67.
120 Mattson S-B. Monosymptomatic exudative pleurisy in persons exposed to asbestos dust. *Scand J Respir Dis* 1975;**56**:263–72.
121 Anonymous. Mysterious pleural effusions. *Lancet* 1982;i:1226.
122 British Thoracic and Tuberculosis Association (BTTA) and the Medical Research Council Pneumoconiosis Unit (MRCPU). A survey of pleural thickening: its relation to asbestos exposure and previous pleural disease. *Environ Res* 1972;**5**:142–51.
123 Ryan CJ, Rodgers FR, Unni KK, Hepper NGG. The outcome of patients with pleural effusions of indeterminate cause at thoracotomy. *Mayo Clin Proc* 1981;**56**:145–9.
124 Feagler JR, Sorensen GD, Rosenfeld MG, Osterland CK. Rheumatoid pleural effusion. *Arch Pathol* 1971;**92**:257–66.
125 Mark EJ. *Lung biopsy interpretation*. Baltimore: Williams and Wilkins, 1984:151–9.
126 Herbert A, Gallagher PJ. Pleural biopsy in the diagnosis of malignant mesothelioma. *Thorax* 1982;**37**:816–21.
127 Marshall RJ, Herbert A, Braye SG, Jones DB. Use of antibodies to carcinoembryonic antigen and human milk fat globule to distinguish carcinoma, mesothelioma, and reactive mesothelium. *J Clin Pathol* 1984;**37**:1215–21.
128 Sluis-Cremer GK, Webster I. Acute pleurisy in asbestos exposed persons. *Environ Res* 1972;**5**:380–92.
129 Hinson KFW, Otto H, Webster I, Rossiter CE. Criteria for the diagnosis and grading of asbestosis. In: Bogovski P, Gilson JC, Timbrell V, Wagner JC, eds. *Biological effects of asbestos*. Lyon: International Agency for Research on Cancer, 1973:54–7.
130 Parkes WR. *Occupational lung disorders*. 2nd ed. London: Butterworth, 1982:233–332.
131 Sterling GM, Herbert A. Lung en cuirasse: a restrictive pleurisy with asbestos exposure [abstract]. *Thorax* 1980;**35**:715.
132 Britton MG. Asbestos pleural disease. *Br J Dis Chest* 1982;**76**:1–10.
133 Eisentadt HB. Benign asbestos pleurisy. *JAMA* 1965;**192**:159–61.
134 Gaensler EA, Kaplan AI. Asbestos pleural effusion. *Ann Intern Med* 1971;**74**:178–91.
135 Elder JL. A study of 16 cases of pleurisy with effusions in ex-miners from Wittenoom Gorge. *Aust NZ Med J* 1972;ii:328–9.
136 Jones JSP, Sheers G. Pleural plaques. In: Bogovski P, Gilson JC, Timbrell V, Wagner JC, eds. *Biological effects of asbestos*. Lyon: International Agency for Research on Cancer, 1973:243–8.
137 Roberts GH. The pathology of parietal pleural plaques. *J Clin Pathol* 1971;**24**:348–53.
138 Hourihane D O'B, Lessof L, Richardson PC. Hyaline and calcified pleural plaques as an index of exposure to asbestos. A study of radiological and pathological features of 100 cases with a consideration of epidemiology. *Br Med J* 1966;i:1069–74.
139 Hillerdal G, Lindgren A. Pleural plaques: correlation of autopsy findings to radiographic findings and occupational history. *Eur J Respir Dis* 1980;**61**:315–9.
140 Meurmann L. Asbestos bodies and pleural plaques in a Finish series of autopsy cases. *Acta Path Microbiol Scand* 1966;suppl 181.
141 LeBouffant L, Martin JC, Durif S, Daniel H. Structure and composition of pleural plaques. In: Bogovski P, Gilson JC, Timbrell V, Wagner JC, eds. *Biological effects of asbestos*. Lyon: Internationaal Agency for Research on Cancer, 1973:249–57.
142 Francis D, Jussuf A, Mortensen T, Sikjaer B, Viskum K. Hyaline pleural plaques and asbestos bodies in 198 randomised autopsies. *Scand J Respir Dis* 1977;**58**:193–6.
143 Wain SL, Roggli VL, Foster WL. Parietal pleural plaques, asbestos bodies and neoplasia. A clinical, pathologic and roentgenologic correlation of 25 consecutive cases. *Chest* 1984;**86**:707–13.
144 Churg A. Fiber counting and analysis in the diagnosis of asbestos-related disease. *Hum Pathol* 1982;**13**:381–92.
145 Thompson JG. The pathogenesis of pleural plaques. In: Shapiro HA, ed. *Pneumoconiosis. Proceedings of the International Conference, Johannesburg 1969*. Cape Town: Oxford University Press, 1969:138–41.
146 Meurmann LO. Pleural fibro-calcific plaques and asbestos exposure. *Envir Res* 1968;**2**:30–46.
147 Sheldon CD, Herbert A, Gallagher PJ. Reactive mesothelial proliferation: a necropsy study. *Thorax* 1981;**36**:901–5.
148 Sahn SA, Antony VB. Pathogenesis of pleural plaques. Relationship of early cellular response and pathology. *Am Rev Respir Dis* 1984;**130**:884–7.
149 Morris DL, Greenberg SD, Lawrence EC. Immune responses in asbestos-exposed individuals. *Chest* 1985;**87**:278–80.
150 Stansfield D, Edge JR. Circulating rheumatoid factor and antinuclear antibodies in shipyard asbestos workers with pleural plaques. *Br J Dis Chest* 1974;**68**:166–70.
151 Payne CR, Jaques P, Kerr IH. Lung folding simulating peripheral pulmonary neoplasm (Blesovsky's syndrome). *Thorax* 1980;**35**:936–40.
152 Stark P. Round atelectasis: another pulmonary pseudotumor. *Am Rev Respir Dis* 1982;**125**:248–50.
153 Blesovsky A. The folded lung. *Br J Dis Chest* 1966;**60**:19–20.
154 Dernevik L, Gatzinsky P. Long term results of operation for shrinking pleuritis with atelectasis. *Thorax* 1985;**40**:448–52.
155 Mintzer RA, Cugell DW. The association of asbestos-induced pleural disease and rounded atelectasis. *Chest* 1982;**81**:457–60.
156 Dernevik L, Björkander J, Hanson LA, *et al*. Immu-

nological abnormalities in shrinking pleuritis with atelectasis. *Eur J Respir Dis* 1985;**66**:128–34.
157 Scully RE. Case records of the Massachusetts General Hospital, case 24–1983. *N Engl J Med* 1983;**308**:1466–72.
158 Schneider HJ, Felson B, Gonzalez LL. Round atelectasis. *AJR* 1980;**134**:225–32.
159 Dalton WT, Zolliker AS, McCaughey WTE, Jacques J, Kannerstein M. Localised primary tumours of the pleura. An analysis of 40 cases. *Cancer* 1979;**44**:1465–75.
160 Clagett OT, McDonald JR, Schmidt HW. Localized fibrous mesothelioma of the pleura. *J Thorac Surg* 1952;**24**:213–30.
161 Millard PR, Jerrome DW, Millward-Sadler GH. Spindle-cell tumours and hypoglycaemia. *J Clin Pathol* 1976;**29**:520–9.
162 Briselli M, Mark EJ, Dickersin GR. Solitary fibrous tumors of the pleura: eight new cases and review of 360 cases in the literature. *Cancer* 1981;**47**:2678–89.
163 Scharifker D, Kaneko M. Localised fibrous "Mesothelioma" of pleura (submesothelial fibroma). A clinicopathologic study of 18 cases. *Cancer* 1979;**43**:627–35.
164 Klemperer P, Rabin CB. Primary neoplasms of the pleura. A report of 5 cases. *Arch Pathol* 1931;**11**:385–412.
165 Kay S, Silverberg SG. Ultrastructural studies of a malignant fibrous mesothelioma of the pleura. *Arch Pathol* 1971;**92**:449–55.
166 Osamura RY. Ultrastructure of localised fibrous mesothelioma of the pleura. *Cancer* 1977;**39**:139–42.
167 Stout AP, Himadi GM. Solitary (localised) mesothelioma of the pleura. *Ann Surg* 1951;**133**:50–64.
168 Butler EB, Berry AV. Diffuse mesotheliomas. Diagnostic criteria using exfoliative cytology. In: Bogovski P, Gilson JC, Timbrell V, Wagner JC, eds. *Biological effects of asbestos*. Lyon: International Agency for Research in Cancer 1973:68–73.
169 Naylor B. The exfoliative cytology of diffuse malignant mesothelioma. *J Pathol Bacteriol* 1963;**86**:293–8.
170 Whitaker D, Shilkin KB. Diagnosis of pleural malignant mesothelioma in life—a practical approach. *J Pathol* 1984;**143**:147–75.
171 Hansen RM, Caya JG, Clowry LJ jun, Anderson T. Benign mesothelial proliferation with effusion. Clinicopathologic entity that may mimic malignancy. *Am J Med* 1984;**77**:887–92.
172 Kahn HJ, Hanna W, Yeger H, Baumal R. Immunohistochemical localisation of prekeratin filaments in benign and malignant cells in effusions. *Am J Pathol* 1982;**109**:206–14.
173 Singer S, Boddington MM, Hudson EA. Immunocytochemical reaction of Ca 1 and HMFG 2 monoclonal antibodies with cells from serous effusions. *J Clin Pathol* 1985;**38**:180–4.
174 Goepel JR. Benign papillary mesothelioma of peritoneum: a histological, histochemical and ultrastructural study of six cases. *Histopathology* 1981;**5**:21–30.
175 Becker SN, Pepin DW, Rosenthal DL. Mesothelial papilloma: a case of mistaken identity in a pericardial effusion. *Acta Cytol* 1976;**20**:266–8.
176 Rosai F, Dehner LP. Nodular mesothelial hyperplasia in hernial sacs. a benign reactive condition simulating a neoplastic process. *Cancer* 1975;**25**:165–75.
177 Yesner R, Hurwitz A. Localised pleural mesothelioma of epithelial type. *J Thorac Surg* 1953;**26**:325–9.
178 Foster EA, Akerman LV. Localised mesotheliomas of the pleura. *Am J Clin Pathol* 1960;**34**:349–64.
179 Kannerstein M, Churg J, McCaughey WTE. Asbestos and mesothelioma: a review. *Pathol Annu* 1978;**13** (part 1):81–129.