

Miliary tuberculosis with hypercalcaemia and raised vitamin D concentrations

R D ISAACS, G I NICHOLSON, I M HOLDAWAY

From the Department of Respiratory Medicine, Green Lane Hospital, and the Departments of Gastroenterology and Endocrinology, Auckland Hospital, Auckland, New Zealand

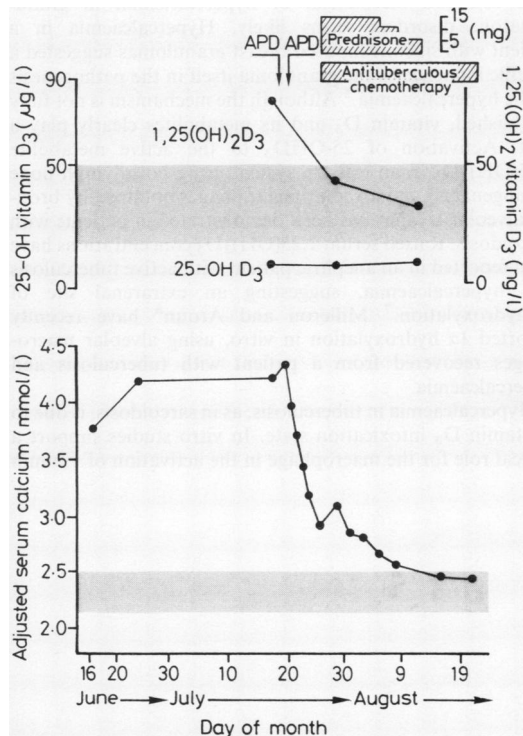
Hypercalcaemia is associated with granulomatous disorders, including sarcoidosis¹ and tuberculosis.²⁻⁴ The exact incidence of hypercalcaemia in tuberculosis is not known. We report a case of miliary tuberculosis and severe hypercalcaemia in which measurements of serum vitamin D₃ concentrations were made. The probable mechanism of the hypercalcaemia is discussed.

Case report

A 44 year old man, a Cook Islander and a non-smoker, presented with an eight month history of lethargy and malaise, a three month history of ascites, and a one month history of polyuria and polydipsia. Abdominal paracentesis had been performed at another hospital but the results of this were not available. Histological examination of a right cervical lymph node showed caseating granulomas typical of tuberculosis. Subsequent cultures of the lymph node, sputum, resting gastric juices, and early morning urine samples grew *Mycobacterium tuberculosis*, sensitive in vitro to isoniazid, rifampicin, and pyrazinamide.

Initial biochemical investigation of the blood revealed hyponatraemia, hypercalcaemia (figure), and no evidence of abnormal renal function. An adrenocorticotrophic hormone stimulation test yielded normal results, as did tests of thyroid function. The serum parathyroid hormone concentration was 20.6 pmol/l, measured in a mid molecule radioimmunoassay (normal 6.0-31.5 pmol/l). Alkaline phosphatase activity was normal and a technetium-99m bone scan showed nothing to suggest malignant disease. A chest radiograph showed miliary shadowing with no focal changes. A computed tomographic scan of the abdomen revealed mesenteric lymphadenopathy, thickened omentum, and the presence of ascites. The liver, spleen, adrenal glands, and kidneys were unremarkable. An intravenous urogram was normal. There was no evidence of lymphoreticular malignancy.

Vitamin D studies (figure) before lymph node biopsy showed depression of 25-hydroxy vitamin D₃ (25-OHD₃) concentrations with raised 1,25-dihydroxy vitamin D₃ (1,25(OH)₂D₃) concentrations. Before lymph node biopsy he received an infusion of the diphosphonate APD (3-amino-1-hydroxy propylidene-1,1-biphosphonate) 0.3 mg/kg on two consecutive days, which produced a prompt fall in serum calcium concentration. After the diagnosis of



Adjusted serum calcium and vitamin D concentrations and response to treatment. Calcium concentrations are adjusted to a mean albumin concentration of 40 g/l (normal ranges indicated by shaded areas).

miliary tuberculosis antituberculous treatment with isoniazid, rifampicin, and pyrazinamide was started. Prednisone was given in decreasing dosage (figure). The serum calcium concentration fell to normal and the improvement was maintained after withdrawal of the steroids. The fall in serum calcium with diphosphonate and steroids was accompanied by a fall in 1,25(OH)₂D₃ levels. One month later he was normocalcaemic and clinically well.

Discussion

This report describes a patient with culture proved miliary tuberculosis, who at the time of diagnosis was hypercalcaemic, and in whom investigations failed to detect any

Address for reprint requests: Professor I M Holdaway, Department of Endocrinology, Auckland Hospital, Auckland 1, New Zealand.

Accepted 15 July 1986

cause for the hypercalcaemia other than tuberculosis. The abnormalities in vitamin D₃ concentration are consistent with activation of the 1 α -hydroxylation pathway. Prompt falls in serum calcium concentration after therapeutic intervention, initially with diphosphonate and later with prednisone, were associated with falls in 1,25(OH)₂D₃ concentrations, and suggest a dominant role of vitamin D₃ in the pathogenesis of the hypercalcaemia. Failure to suppress parathyroid hormone in the face of hypercalcaemia, however, suggests that partial autonomy of parathyroid hormone production may have been a contributing factor in this patient.

A common mechanism of hypercalcaemia in granulomatous disorders seems likely. Hypercalcaemia in a patient with silicone induced breast granulomas suggested a specific influence of the granuloma itself in the pathogenesis of the hypercalcaemia.⁵ Although the mechanism is not fully established, vitamin D₃ and its metabolites clearly play a part. Activation of 25-OHD₃ to the active metabolite 1,25(OH)₂D₃ in an in vitro system using both lymph node homogenates⁶ and alveolar macrophages obtained by bronchoalveolar lavage¹ has been demonstrated in patients with sarcoidosis. Raised serum 1,25(OH)₂D₃ concentrations have been reported in an anephric patient with active tuberculosis and hypercalcaemia, suggesting an extrarenal site of 1 α -hydroxylation.⁷ Milleron and Aroun⁸ have recently reported 1 α hydroxylation in vitro, using alveolar macrophages recovered from a patient with tuberculosis and hypercalcaemia.

Hypercalcaemia in tuberculosis, as in sarcoidosis, is due to a vitamin D₃ intoxication state. In vitro studies support a critical role for the macrophage in the activation of vitamin

D by 1 α -hydroxylation. Corticosteroids reduce the concentration of 1,25(OH)₂D₃, presumably by inhibiting the hydroxylation step. The changes observed in this patient are consistent with this mechanism, although an additional influence from the diphosphonate APD is also possible.

We are grateful to Dr HH Rea for permission to report this patient.

References

- 1 Adams JS, Sharma OP, Mercedes AG, Singer FR. Metabolism of 25-hydroxyvitamin D₃ by cultured pulmonary alveolar macrophages in sarcoidosis. *J Clin Invest* 1983;72:1856-60.
- 2 Abbasi AA, Chemplavil JK, Farah S, Muller BF, Arnstein AR. Hypercalcemia in active pulmonary tuberculosis. *Ann Intern Med* 1979;90:324-8.
- 3 Shai F, Baker RK, Addrizzo JR, Wallach S. Hypercalcemia in mycobacterial infection. *J Clin Endocrinol Metab* 1972;34:251-6.
- 4 Sharma OP, Lamon J, Winsor D. Hypercalcemia and tuberculosis. *JAMA* 1972;222:582.
- 5 Kozeny GA, Barbato AL, Bansal VK, Vertuno LL, Hano JE. Hypercalcemia associated with silicone-induced granulomas. *N Engl J Med* 1984;311:1103-5.
- 6 Mason RS, Frankel T, Chan Y-L, Lissner D, Posen S. Vitamin D conversion by sarcoid lymph node homogenate. *Ann Intern Med* 1984;100:59-61.
- 7 Gkonos PJ, London R, Henler ED. Hypercalcemia and elevated 1,25-dihydroxyvitamin D levels in a patient with end-stage renal disease and active tuberculosis. *N Engl J Med* 1984;311:1683-5.
- 8 Milleron JCB, Aroun MGG. Serum concentrations of vitamin D metabolites in untreated tuberculosis. *Thorax* 1985;40:639-40.