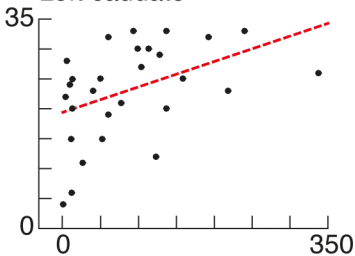
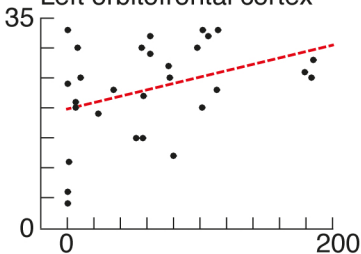


Left caudate



Left orbitofrontal cortex



Left superior frontal gyrus

