

# Pulmonary complications of intravenous drug misuse · 1

## Epidemiology and non-infective complications

Charles R K Hind

Complications resulting from intravenous drug misuse affect the lung more frequently than any other organ, regardless of whether the drug misuser is infected with the human immunodeficiency virus (HIV). The risk of pulmonary infections is increased by virtue of general self neglect, poor nutrition, and the non-sterile technique used both to prepare the fix and to self administer an intravenous injection. Drug misusers are also at risk from an ever widening range of pulmonary complications not directly related to infection (table 1). Understanding of the well defined non-infective problems is essential to allow them to be recognised and distinguished from the infectious complications, which often require emergency treatment. The non-infectious disorders may mimic more common pulmonary disease and may themselves lead to respiratory disability.

Most striking, however, is the high rate of HIV infection in intravenous drug misusers, and this is increasing disproportionately faster than among other high risk groups. As with anyone infected with HIV there is a high incidence of opportunist and non-opportunist pulmonary infections. In contrast, pulmonary complications not directly related to infection (for example, Kaposi's sarcoma) are much less common in HIV positive drug misusers than in other groups infected with HIV.

The aims in these two articles are to describe briefly the pattern of pulmonary complications seen in intravenous drug misusers, and to summarise the clinical and pathological

features that are characteristic of individual complications. This should facilitate diagnosis and management of the specific disorders. Part 1 will concentrate on the epidemiology of intravenous drug misuse and on the non-infective pulmonary complications seen in those drug misusers who are not infected with HIV.

### Demography of intravenous drug misuse

The prevalence of intravenous drug misusers is thought to be increasing worldwide. Because possessing controlled drugs is a criminal offence, however, and because only a proportion of drug users are in contact with the treatment services, the numbers of intravenous drug misusers in any community can only be estimated indirectly.<sup>1,2</sup> Such methods lead to an estimation of 500 000 intravenous drug users within the European Community. In the United States there are thought to be a similar number in New York alone.<sup>3</sup> The numbers of new addicts in the United Kingdom increased by 8% and of renotified addicts by 17% between 1988 and 1989, and there are now an estimated 75 000 regular (daily) heroin users and about the same number of users of non-notifiable drugs or occasional users of heroin.<sup>4</sup> Of these, about one third smoke rather than inject heroin, though the stability of this preference is not known. No information is available on the prevalence of intravenous drug misuse in some communities such as the Soviet Union.

Until 1980 the problem of intravenous drug misuse was predominantly concentrated in major cities such as New York, London and Milan and was endemic among men aged 25-39 from particular subcultures (for example the black or Hispanic populations in New York).<sup>5</sup> By the 1980s drug users in Western Europe and the United States were even younger, more likely to be women (one third of cases), and more likely to live in areas of high unemployment or social deprivation and throughout the country rather than concentrated in the major cities.<sup>6,7</sup> Intravenous drug misusers represent a significant burden on the economy of any nation. This is not only by virtue of the health care they require but also because of the amount of money each addict needs to finance his or her habit. The annual cost of providing a twice daily fix of heroin for one addict in Britain is about £36 000 (USA \$50 000), and this money is usually acquired by theft or prostitution or both.<sup>8</sup> As patients intravenous drug misusers are usually aggressive and manipulative, and tend not to comply

Table 1 Pulmonary complications of intravenous drug misuse

NON-HIV RELATED	
Non-infective	
Respiratory depression	
Acute pulmonary oedema following overdose	
Foreign particle embolisation	
	talc
	cotton
	starch
	mercury
	needles
	<i>Scopulariopsis brumptii</i>
Alteration in pulmonary function	
Emphysema	
Airways disease	
Secondary to central venous injection	
Pulmonary infections	
HIV RELATED	
Pulmonary infections	
	Non-opportunist
	Opportunist
Non-infective	
	Malignancy
	Interstitial pneumonitis

University of  
Liverpool, Royal  
Liverpool Hospital,  
and Cardiothoracic  
Centre, Broadgreen  
Hospital, Liverpool  
C R K Hind

Address for reprint requests:  
Dr C R K Hind, Broadgreen  
Hospital, Liverpool L14  
3LB.

Table 2 Substances used for intravenous drug misuse

NARCOTICS	
Heroin	
Methadone	
Pentazocine	
Codeine	
Propoxyphene	
Buprenorphine	
Dipipanone	
SEDATIVES AND TRANQUILLISERS	
Diazepam	
Temazepam	
Glutethimide	
Phenobarbital	
STIMULANTS	
Methylphenidate	
Cocaine	
Amphetamines	

with their medical treatment. They are consequently a difficult group to treat, and require constant vigilance to safeguard the property of all who come in contact with them.<sup>5,9</sup> Furthermore, only a proportion of intravenous drug users are in contact with the treatment services, though great efforts are made in certain countries to reach the rest.<sup>10,11</sup>

### Techniques of intravenous drug misuse

An understanding of the types of substances used in intravenous drug misuse and their method of preparation will help the clinician understand the pathogenesis of many of the pulmonary complications described below.

Until the early 1980s over 90% of intravenous drug misusers injected heroin, usually twice or three times a day. The list of other drugs associated with misuse continues to expand, and includes other intravenous preparations and the injection of substances intended for oral medication (table 2). More recent studies on patterns of drug use in Britain indicate that "new" drug misusers are more likely to be polydrug abusers, using combinations of drugs such as buprenorphine, dihydrocodeine, and temazepam, with or without heroin.<sup>7,12</sup> These changes in the pattern of drug misuse reflect in part the local availability of that drug in each city. At the

same time as using drugs intravenously, such individuals may inhale drugs (for example, by smoking or snorting them), a behaviour associated with a different variety of pulmonary complications.<sup>13</sup> Alcohol misuse is also common.<sup>5,7</sup>

Worldwide, however, heroin remains the most common drug to be used by intravenous drug misusers (in the UK 84% use heroin and 6% cocaine).<sup>4</sup> Because many of the complications relate to the methods used to prepare and then inject the drug, these processes will be briefly summarised.<sup>5</sup> The heroin usually arrives in a pure form in Western countries, having been acetylated from the parent compound morphine. Pure heroin is then progressively adulterated ("cut") by diluting it 20–100 fold in an unsterile fashion with soluble diluents ("fillers"—for example, quinine, lactose, maltose, mannitol, baking soda, starch, barbiturates, and chloroquine).<sup>14</sup> As a result the concentration of heroin sold to the user by the pusher is very variable (0–20%).

Having purchased the fix the user mixes the dry white powder in unsterile water (from a public lavatory, for instance) or in saliva. The mixture is heated briefly in a spoon or bottle cap held over a lighted flame, such as a match or a candle, and removed from the heat as soon as bubbles appear. Other forms of heroin (for example, "brown" heroin) are poorly soluble in water and require acidification—with lemon juice or vinegar, for example—before the heating process.

The heroin mixture is then drawn into a syringe through a ball of cotton wool to filter out the larger impurities. The intravenous self injection ("mainlining") is performed without skin cleansing, often in the presence of one or more users, who will then share the syringe and needle without any attempt at sterilisation.

### Non-infective pulmonary complications

Because of the lifestyle of most intravenous drug misusers, detailed data on the incidence and prevalence of the different pulmonary complications is difficult to obtain.<sup>5,15–21</sup> Some information is available from two inner city hospitals in the United States from before (1971–2) and after (1985–7) the onset of the AIDS epidemic (summarised in table 3).<sup>22,23</sup>

Table 3 Relative frequency of pulmonary complications associated with intravenous drug misuse in two inner city hospitals in the United States

	Los Angeles 1971–2	Georgetown 1985–7
Total admissions	264	51
Overdose and respiratory depression	No (%)	No (%)
Non-cardiac pulmonary oedema	137 (57)	—
Aspiration pneumonia	24 (10)	—
Atelectasis	31 (13)	—
Pneumonia	6 (2)	—
Community acquired	18 (7)	10 (20)
Septic pulmonary emboli	11 (5)	12 (24)
Lung abscess	12 (5)	1 (2)
Empyema	—	5 (10)
Tuberculosis	(0)	5 (10)
Adult respiratory distress syndrome	—	4 (8)
Pulmonary vascular granulomatosis	2 (<1)	2 (4)
Emphysema	—	2 (4)
Acquired immune deficiency syndrome	—	5 (10)

### ACUTE NON-CARDIAC PULMONARY OEDEMA AFTER OVERDOSE

Most intravenous heroin users will experience drug overdose, coma, and respiratory depression at least once. This complication is the most common cause of death among intravenous drug misusers, and kills an estimated 1% of addicts each year.<sup>5,9,13,15,22,23</sup> Acute non-cardiac pulmonary oedema is one of the critical complications of heroin overdose. It occurs in about 15% of addicts admitted to hospital after drug overdose, and may itself result in sudden death.

### Pathophysiology

Lack of awareness of the potency of each

individual heroin fix is the usual cause of drug overdose. Because of the inordinate adulteration of the pure heroin, the street samples vary considerably in potency. At least 3% heroin is required to provide the addict with a "kick" but over 20% will cause a lethal overdose. Addicts returning to intravenous use after a period of abstinence, during which their tolerance will have fallen, are especially prone to this complication, as are neophytes attempting to imitate their more drug tolerant colleagues.

The mechanism of the acute non-cardiac pulmonary oedema that sometimes quickly follows overdose is obscure, though various hypotheses have been suggested, including acute alveolitis associated with the non-narcotic constituents of the injected material.<sup>24-29</sup> The adulteration of street heroin and the methods used to prepare the "fix" provide many opportunities for infection with microorganisms and heroin addicts have a high incidence of circulating precipitins to *Aspergillus*, *Micropolyspora faeni*, and *Thermoactinomyces vulgaris*.<sup>30</sup>

Postmortem examination shows voluminous lungs with congestion, oedema, varying degrees of acute and chronic inflammation and intra-alveolar exudate or macrophage accumulation, depending on how quickly death occurred.<sup>22 31</sup> Similar findings have been reported after intravenous injections of other narcotic and non-narcotic agents.<sup>28 32 33</sup>

#### Clinical features

The presentation is usually dramatic.<sup>5 9 13 15 17 22 24 27 28</sup> The usual turpor following injection rapidly progresses to stupor with irregular slow (or fast) gasping respiration (air hunger), leading to coma and respiratory arrest. Death may occur so suddenly that the needle is still in the vein. The individuals that reach medical aid are usually stuporous or comatose, with cyanosis and pinpoint pupils. A white or pink froth is frequently found in the mouth or nose, and slow respiration, variable heart rate and blood pressure, fever (in 90%), and bilateral basal inspiratory crackles or wheezes or both (in half the patients) may be present. Occasional patients are hypothermic, having had ice or cold water applied to the trunk and testicles. In some cases pulmonary oedema does not appear until 24-48 hours after admission for overdose.<sup>34</sup>

#### Diagnosis

The diagnosis should be suspected in any addict, or young person without underlying heart disease, who presents with clinical and radiological features of acute pulmonary oedema. The chest radiograph usually shows the classical symmetrical perihilar shadowing, but the oedema may affect the whole or only part of one lung and then be easily confused with infection. In mild cases there may only be a coarse mottling of the lung fields.<sup>20 34</sup>

#### Management

Intravenous naloxone (0.8-2 mg repeated at intervals of two to three minutes to a maximum

of 10 mg) is the treatment of choice and usually is rapidly followed by an increase in the respiratory rate and pupil size. Treatment thereafter is symptomatic with oxygen as indicated. Some patients require assisted ventilation. The temperature and radiographic abnormalities usually return to normal within 48-72 hours, by which time most drug misusers will have discharged themselves from hospital care. The hospital mortality is 10-20%.<sup>23 27</sup>

Pulmonary function testing 2-12 days after recovery shows a reduction in forced vital capacity (FVC), total lung capacity (TLC), and carbon monoxide transfer factor (TLCO). In subsequent long term follow up lung volumes have increased but TLCO has remained low.<sup>35</sup>

#### OTHER SEQUELAE OF OVERDOSE

Overdose is often associated with vomiting and aspiration of gastric contents into the lungs, and this may lead to the adult respiratory distress syndrome (ARDS).<sup>23</sup> Milk is often found in the aspirated material, having been given by other heroin users in the mistaken belief that it is a useful aid to resuscitation. Segmental, lobar, or lung collapse may also follow overdose as a result of retained secretions or aspiration.<sup>20</sup>

#### FOREIGN PARTICLE EMBOLISATION

Although the alterations in pulmonary function seen in intravenous drug misusers suggest that foreign particle emboli are common (see below) appreciable respiratory symptoms are unusual and occur in under 1% of drug misusers.<sup>5 9 13 15 20 22 23</sup>

#### Pulmonary vascular granulomatosis

This rare complication is seen in the small percentage (under 5%) of intravenous drug misusers who inject aqueous suspensions of medications intended solely for oral use (table 4).<sup>36-46</sup> The foreign body granulomas are a reaction to the embolisation of insoluble materials used as fillers and binders in the tablets. This complication is rarely seen from the use of heroin alone, though there are a few reports of pulmonary granulomatosis induced by cotton (from the home made cotton wool plugs used to filter the "fix" before self injection) and starch (used to adulterate the street heroin).<sup>47 48</sup>

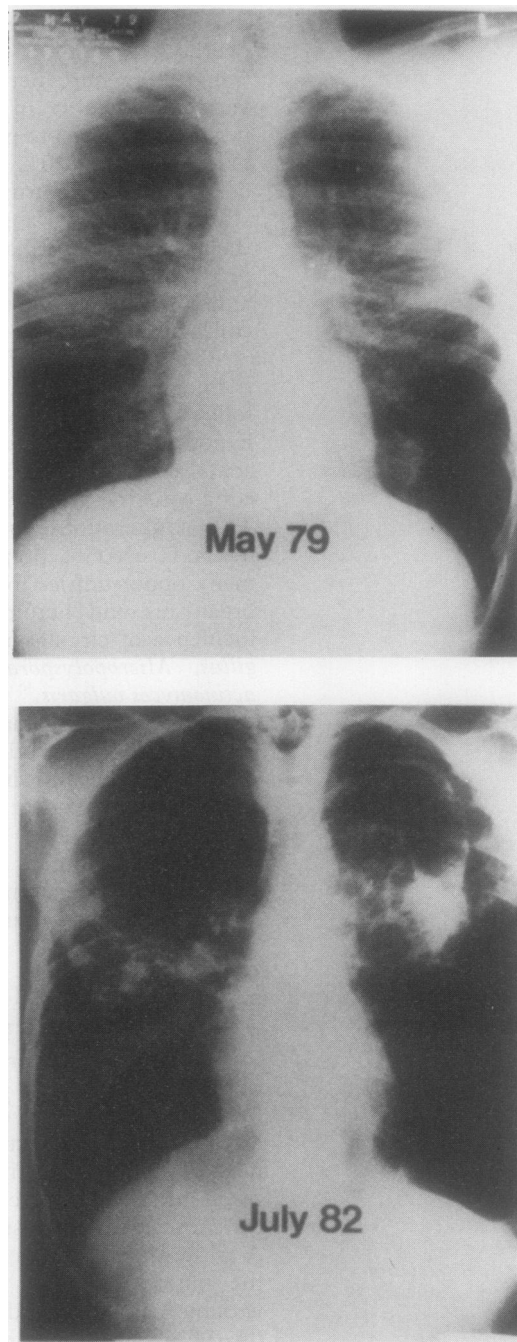
Table 4 Self induced pulmonary granulomatosis in intravenous drug misusers: tablets injected intravenously

Amphetamines
Codeine, dihydrocodeine
Glutethimide
Hydromorphone
Meperidine
Methadone
Methylphenidate hydrochloride
Morphine sulphate
Pentazocine
Phencyclidine
Phenmetrazine
Phenyltoloxamine
Propoxyphene
Propylhexedrine
Secobarbital
Tripeleminamine

*Talc induced "mainline" pulmonary granulomatosis* In most reported cases the granulomatous reaction is secondary to talc (magnesium trisilicate),<sup>36-40 42-46</sup> a filler added to tablets during the manufacturing process to prevent them sticking to the punches and dies (table 4). In some cases (for example, with pentazocine) talc accounts for three quarters of the tablet's weight. Clinical features arise only after heavy and prolonged use of intravenous injections (for example, 10 000-100 000 tablets, or the equivalent of 10-40 tablets a day for 1-10 years). Popular combinations are of pentazocine and tripeleminamine or methylphenidate. Cases have also been reported in addicts with a history of injecting alpha sympathomimetic agents obtained from nasal inhalers, (such as mephenteramine and propylhexedrine).<sup>41</sup>

**Pathophysiology:** The pathological features are of diffuse intravascular and perivascular non-casating granulomas. Polarised microscopy shows birefringent particles within the granuloma with a larger mean particle size (over 5  $\mu\text{m}$ ) than is seen in inhalational talcosis. There is variable occlusion of the pulmonary vessels by thrombosis or fibrosis, and in severe cases hypertrophy and angiomatoid malformation of the pulmonary arteries.<sup>40 41 49 50</sup> These pathological changes are a consequence of the pulmonary endothelial injury induced by the intravenous talc particles trapped within the arterioles and capillaries. This leads to thrombosis and focal acute inflammation with destruction of the arterial walls and subsequent organisation and revascularisation. With time there is transvascular migration of particles and the formation of perivascular and interstitial granulomas, causing interstitial fibrosis and pulmonary hypertension. These changes have been reproduced in animal models.<sup>51</sup> Perivascular deposition of talc in other organs, such as the liver and spleen, may also be seen.

**Clinical features:** The main symptom is of progressively increasing breathlessness with exertion, occasionally associated with a slightly productive cough.<sup>36 37 39-45 48 49</sup> Occasional cases have had symptoms suggesting pulmonary infarction,<sup>44</sup> and others have noted dyspnoea and wheezing associated with the intravenous injection.<sup>42</sup> Most of the reported cases have occurred in male smokers. Most had scars and thrombosed veins on their forearms, indicating prolonged intravenous misuse. Fundoscopy in 60% showed glistening white dots (talc particles) in the macula region.<sup>43</sup> The chest radiograph shows diffuse reticular-nodular infiltrates (less than 1 mm diameter), which are more prominent at the lung bases (35-50%), with or without loss of lung volume (fig 1). Very rarely changes of pulmonary hypertension are superimposed. Other reported changes include bilateral apical or midzone reticular infiltrates, with or without lymphadenopathy, and volume loss with coalescence of opacities in the upper lobes simulating progressive massive fibrosis.<sup>43 52</sup> In many cases (50-65%), however, the chest radiograph is normal. Pulmonary



**Figure 1** Talc induced "mainline" pulmonary granulomatosis. (a) A diffuse micronodular pattern is seen in both lungs with increased translucency at the periphery of the lung bases. (b) Three years later the mid lung fields show large irregular opacities resembling progressive massive fibrosis. Bullae and a pneumothorax are seen in the left lung with increased lucency at the right base. From Paré et al<sup>51</sup>; reproduced by courtesy of the "American Review of Respiratory Disease."

function tests may show low gas transfer (77-100%), usually with an obstructive defect (62%) but occasionally with a restrictive (15%) or mixed ventilatory defect (23%).<sup>53 54</sup> In one study serum angiotensin converting enzyme activity was raised in three of six patients and there was diffuse uptake of gallium-67 throughout the lung in all six.<sup>55</sup> As might be predicted, the degree of breathlessness and the severity of the chest radiographic and pulmonary function abnormalities relate to the quantity of drug misused.

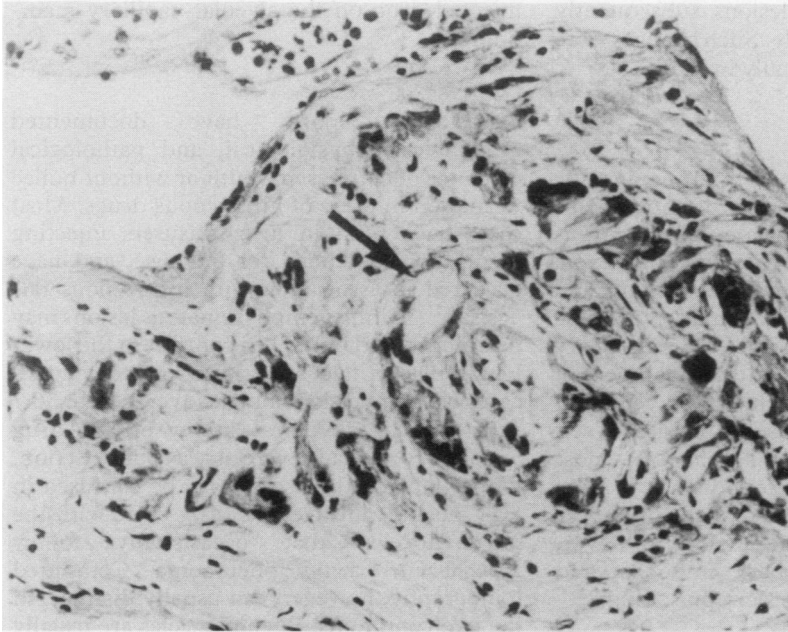


Figure 2 Talc induced "mainline" pulmonary granulomatosis: lung parenchyma showing fibrosis and an aggregate of foreign body giant cells containing plate like talc crystals (arrow). (Haematoxylin and eosin.) From Paré et al<sup>57</sup>; by courtesy of the "American Review of Respiratory Disease."

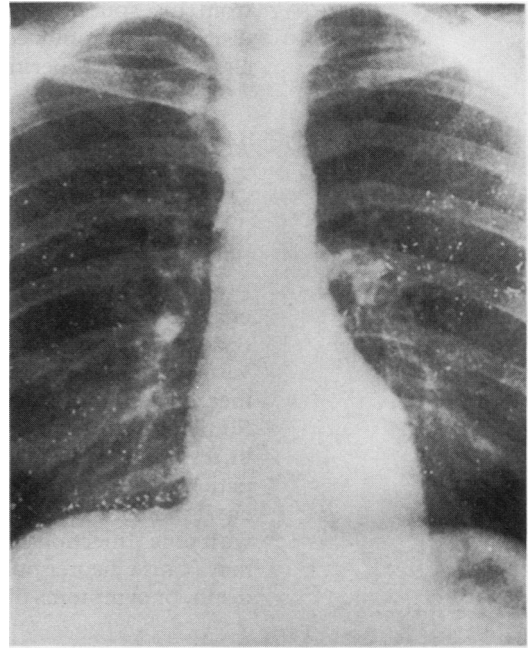


Figure 3 Mercury emboli in the lung. From Clague et al<sup>68</sup>; by courtesy of the "British Medical Journal."

**Diagnosis:** The diagnosis can usually be made by transbronchial or open lung biopsy, which shows multiple foreign body granulomas (figure 2) containing birefringent crystals. Bronchoalveolar lavage may show birefringent intracellular or free particles consistent with talc (66%), even in cases with a normal chest radiograph.<sup>56</sup> Characteristic appearances have also been reported in biopsy specimens of subcutaneous nodules in the region of sclerosed superficial forearm veins, and in paratracheal nodes obtained by mediastinoscopy.<sup>53</sup>

**Prognosis:** In untreated cases severe pulmonary hypertension may develop.<sup>57</sup> Pulmonary angiography and ventilation-perfusion lung scanning show filling defects occasionally, though postmortem microangiography clearly shows poor filling.<sup>41 58</sup> Cor pulmonale and death may follow. Sudden, apparently unexplained deaths have also been reported in the absence of previous signs of cor pulmonale, and may be a consequence of the vasodilatory properties of some of the injected drugs.<sup>40 41</sup> Treatment with prednisolone in a few cases has improved symptoms and signs and reduced pulmonary hypertension.<sup>44</sup>

Patients may deny their intravenous habit. The diagnosis should therefore always be considered in any man presenting with apparently primary pulmonary hypertension.<sup>40 41 43 49 50</sup> Other conditions that may be mimicked include sarcoidosis, pulmonary vasculitis, embolic pulmonary schistosomiasis and *Pneumocystis carinii* pneumonia secondary to HIV infection.<sup>59-62</sup> Those who repeatedly use intramuscular pentazocine may also develop a skin syndrome resembling scleroderma, and this may further confuse interpretation of the pulmonary abnormalities.<sup>63</sup>

In one series all six patients developed severe respiratory disability during long term follow

up despite discontinuing their drug misuse, and three died of respiratory failure and cor pulmonale.<sup>57</sup> Their chest radiographs showed progressive upper lobe conglomeration of the pinpoint nodules with volume loss to give an appearance resembling progressive massive fibrosis (fig 1). The lower lobes showed changes suggesting bullous emphysema, in two cases complicated by pneumothorax. Pulmonary function in all cases showed substantial airways obstruction with hyperinflation and air trapping. Postmortem examination showed emphysema in addition to the granulomatous inflammation and fibrosis surrounding the talc particles.

**Other forms of self induced pulmonary granulomatosis** Other materials that have been identified within these granulomatous lesions include cotton fibres (morphine and heroin addicts),<sup>47 64</sup> corn starch (heroin, pentazocine, secobarbital)<sup>48</sup> and cellulose (pentazocine).<sup>65</sup> Starch causes a mild, transient reaction. The pathophysiological and clinical features and the complications seen with injected cotton or cellulose are similar to those of talc induced "mainline" pulmonary granulomatosis. These different substances are identified in lung biopsy specimens by their individual histochemical staining characteristics and birefringent appearances. All the changes can be produced in experimental models.<sup>66</sup>

**Scopulariopsis brumptii:** A case of pulmonary granulomatosis secondary to fungal spores of the soil saprophyte *Scopulariopsis brumptii* has also been reported.<sup>74</sup> An intravenous opium addict with no respiratory symptoms had two small pulmonary nodules on a routine chest radiograph. The diagnosis was made by open lung biopsy. Precipitating antibodies to the fungal antigen were in the patient's serum, and the fungus was grown

from his sputum. The lesions subsequently disappeared spontaneously. Such changes were also produced experimentally in mice.

#### *Mercury emboli*

There are several reports of multiple metallic mercury emboli in the lungs of intravenous drug misusers.<sup>67-70</sup> Self injection of mercury is thought by some to improve athletic and sexual prowess. The chest radiograph is striking, and characteristically shows small metallic opacities in the distribution of the pulmonary vascular bed (fig 3), often with a small pool of mercury in the apex of the right ventricle. Similar opacities may be seen at the sites of self injection in the peripheral veins. In most patients the changes are found on a routine chest radiograph, and they gradually disappear with time. Injection of large amounts, however, may cause acute pulmonary embolism and death, or symptoms of mercury poisoning.

#### *Needle emboli*

Cases where needles have embolised to the lung have been reported, especially in drug misusers using central venous sites for injections.<sup>71-73</sup> These emboli cause few deaths and are best left alone. Such patients usually have subcutaneous needle densities visible on radiographs at the site of venous self injection.

#### ALTERATION IN PULMONARY FUNCTION

Several reports highlight impairment of pulmonary function in current or past users of intravenous drugs who had no clinical evidence of chest disease.<sup>53 75 76</sup> The largest series consists of 512 consecutive heroin addicts with a mean duration of intravenous use of six and a half years.<sup>76</sup> In this series a low transfer factor for carbon monoxide (less than 75%) was found in 214 (42%) subjects. In 190 this was the only abnormality of pulmonary function; the addicts denied respiratory symptoms and the chest radiograph was normal. A few had airways obstruction (35 cases, 6%) or restrictive lung disease (40 cases, 7%), with or without a low TLCO. There was no correlation between duration of intravenous drug use and the TLCO. Exercise testing in 14 addicts in this series with a low TLCO showed only mild abnormalities in gas exchange. Follow up studies after six months in four addicts showed no improvement in TLCO.

Increased lung recoil pressure and decreased lung compliance have also been described.<sup>75</sup> Regional lung function studies using radioactive markers have shown diffuse non-segmental defects and delayed clearance of inhaled xenon-133 in symptomless intravenous drug misusers. The ventilation abnormalities resolved with cessation of heroin use whereas the perfusion defects persisted.<sup>77</sup>

The explanation for all these various changes is presumed to be multifactorial and includes previous episodes of subclinical pneumonia and non-cardiac pulmonary oedema following overdose, and foreign body granulomas. There is no evidence for a direct toxic effect of the

injected drug on the alveolar-capillary membrane.<sup>75</sup>

#### EMPHYSEMA

Occasional reports have documented radiological, physiological, and pathological evidence of emphysema with or without bullae formation in users of intravenous drugs. Most cases have been in drug misusers injecting medications intended for oral use, and have occurred in association with intravenous talcosis.<sup>54 57 78</sup> Similar emphysematous lesions may be induced in rabbits.<sup>79</sup> In contrast to the lower lobe bullae in talcosis, one series included 10 cases with upper lobe bullae (average age 36.7 years) in a radiological survey of 387 drug misusers.<sup>80</sup> All had severe airways obstruction. Upper lobe cystic disease may be confused in HIV positive intravenous drug users with the pneumatoceles that occasionally follow *Pneumocystis carinii* pneumonia. Computed tomography, however, can usually distinguish the two conditions. Pneumatoceles are usually dispersed throughout the lung parenchyma, whereas emphysematous bullae in intravenous drug users are located peripherally with sparing of the central portions of the upper lobes.<sup>81</sup>

#### AIRWAYS DISEASE

Several studies have failed to show an increased incidence of asthma in intravenous drug users, though in one series one quarter of those with asthma had an attack within hours of using intravenous heroin.<sup>82</sup> Both heroin and morphine release histamine, and inhalation of these compounds may provoke acute severe asthma, which may be fatal.<sup>83</sup>

Symptomatic bronchiectasis has also been described in intravenous heroin addicts with a past history of pulmonary oedema following overdose and diffuse or predominantly lower lobe bronchiectasis may be seen on bronchographs. The mechanism of bronchial injury is uncertain, but may be a sequelae of aspiration pneumonia or relate to the high prevalence of fungal precipitins in the sera of intravenous heroin users.<sup>30</sup> Allergic bronchopulmonary aspergillosis has been described in smokers of marijuana contaminated with fungi.<sup>13</sup>

#### COMPLICATIONS AT THE SITE OF INTRAVENOUS INJECTION

Long term intravenous drug misusers gradually obliterate their peripheral veins by an infectious or sclerotic process. Once they have exhausted their superficial veins they may resort to performing central venous injections, via either the supraclavicular (internal jugular vein—"pocket shot") or the subclavicular route (subclavian vein). These injections are undertaken either by the user or by "lay specialists." Complications have included unilateral and bilateral haemothoraces, with or without tension pneumothorax or pyopneumothorax.<sup>84-87</sup> Individuals may present with acute respiratory distress and the picture may easily be confused with that of acute non-cardiac pulmonary oedema following overdose. There is usually evidence of a puncture site with or without a superficial abscess below the



injection site. There are also occasional reports of hoarseness after supraclavicular injection as a result of damage to the vagus or recurrent laryngeal nerves.<sup>85</sup>

Pneumomediastinum has also been described in an intravenous heroin user, thought to be secondary to the prolonged Valsalva manoeuvre used as part of his ritual during the "fix".<sup>88</sup> The air resolved spontaneously.

- 1 Chasnoff IJ, Landress HJ, Barrett ME. The prevalence of illicit-drug or alcohol use during pregnancy and discrepancies in mandatory reporting in Pinellas County, Florida. *N Engl J Med* 1990;332:1202-6.
- 2 Hartnell R, Mitcheson M, Lewis R, Bryer S. Estimating the prevalence of opioid dependence. *Lancet* 1985;i:203-5.
- 3 Des Jarlais DC, Friedman R, Novick DM, et al. HIV-1 infection among intravenous drug users in Manhattan, New York City, from 1977 through 1987. *JAMA* 1989; 261:1008-12.
- 4 Home Office. *Statistics of the misuse of drugs: addicts notified to the Home Office, United Kingdom, 1989*. Croydon, Surrey: Government Statistical Department, 1990. (Statistical Bulletin No 7/90).
- 5 Cherubin CE. The medical sequelae of narcotic addiction. *Ann Intern Med* 1967;67:23-33.
- 6 Brettell RP, Bisset K, Burns S, et al. Human immunodeficiency virus and drug misuse: the Edinburgh experience. *Br Med J* 1987;295:421-4.
- 7 Skidmore CA, Robertson JR, Robertson AA, Elton RA. After the epidemic: follow-up study of HIV seroprevalence and changing patterns of drug use. *Br Med J* 1990;300:219-23.
- 8 Hart GJ, Sonnex C, Petherick A, Johnson AM, Feinmann C, Adler MW. Risk behaviours for HIV infection among injecting drug users attending a drug dependency clinic. *Br Med J* 1989;298:1081-3.
- 9 Sapira JD. The narcotic addict as a medical patient. *Am J Med* 1968;45:555-88.
- 10 Fleming PM. Providing services for drug misusers: what lessons from North America? *Br Med J* 1988;296: 1589-90.
- 11 Richards T. Drug addicts and the GP. *Br Med J* 1988; 296:1082.
- 12 Swadi H, Wells B, Power R. Misuse of dihydrocodeine tartrate (DF118) among opiate addicts. *Br Med J* 1990; 300:1313.
- 13 Glassroth J, Adams GD, Schnoll S. The impact of substance abuse on the respiratory system. *Chest* 1987;91:596-602.
- 14 O'Gorman P, Patel S, Notcutt S, Wicking J. Adulteration of "street" heroin with chloroquine. *Lancet* 1987;i:746.
- 15 Helpert M, Rho YM. Deaths from narcotism in New York City. *NYJ Med* 1966;66:2391-408.
- 16 Louria DB, Hensle T, Rose J. The major complications of heroin addiction. *Ann Intern Med* 1967;67:1-22.
- 17 Johnston EH, Goldbaum LE, Wilton RL. Sudden death in addicts. *Med Ann DC* 1969;33:375-81.
- 18 Jaffe RB, Koschmann EB. Intravenous drug abuse: pulmonary, cardiac and vascular complications. *AJR Rad Ther Nucl Med* 1970;109:107-20.
- 19 Siegel H. Human pulmonary pathology associated with narcotic and other addictive drugs. *Hum Pathol* 1972; 3:55-66.
- 20 Stern WZ, Subbarao K. Pulmonary complications of drug addiction. *Sem Roentgenol* 1983;18:183-97.
- 21 Brody SL, Slovis CM, Wrenn KD. Cocaine-related medical problems: consecutive series of 233 patients. *Am J Med* 1990;88:325-31.
- 22 Gottlieb LS, Boylen TC. Pulmonary complications of drug abuse. *West J Med* 1974;120:8-16.
- 23 O'Donnell AE, Pappas LS. Pulmonary complications of intravenous drug abuse: experience at an inner-city hospital. *Chest* 1988;94:251-3.
- 24 Steinberg AD, Karliner JS. The clinical spectrum of heroin pulmonary oedema. *Arch Intern Med* 1968;122:122-7.
- 25 Luisada A. Paroxysmal pulmonary oedema and the acute cardiac lung. *Am J Cardiol* 1967;20:69-76.
- 26 Lupovich P, Pilewski R, Sapira JD, et al. Cardiotoxicity of quinine as adulterant in drugs. *JAMA* 1970;212:1216-8.
- 27 Duberstein JL, Kaufman DM. A clinical study of an epidemic of heroin intoxication and heroin-induced pulmonary oedema. *Am J Med* 1971;51:704-14.
- 28 Frand UI, Shin CS, Williams MH. Methadone-induced pulmonary oedema. *Ann Intern Med* 1972;76:975-9.
- 29 Katz S, Aberman A, Frand UI, et al. Heroin pulmonary oedema—evidence for increased capillary permeability. *Am Rev Respir Dis* 1972;106:472-4.
- 30 Smith WR, Wells ID, Glauser FL, Novey HS. High incidence of precipitins in sera of heroin addicts. *JAMA* 1975;232:1337-8.
- 31 Byers JM, Soin JS, Fisher RS, Hutchins GR. Acute pulmonary alveolitis in narcotics abuse. *Arch Pathol* 1975;99:273-7.
- 32 Lerner AM, Oerther FJ. Characteristics and sequelae of paregoric abuse. *Ann Intern Med* 1966;65:1019-30.
- 33 Kirsch CM, Yenokida GG, Jensen WA, Wendland R, Suh H, Bourgault M. Non-cardiogenic pulmonary oedema due to the intravenous administration of clove oil. *Thorax* 1990;45:235-6.
- 34 Morrison WJ, Wetherill S, Zyroff J. The acute pulmonary oedema of heroin intoxication. *Radiology* 1970;97:347-52.
- 35 Karliner JS, Steinberg AD, Williams MH. Lung function after pulmonary edema associated with heroin overdose. *Arch Intern Med* 1969;124:350-5.
- 36 Krainer L, Berman E, Wishnick SD. Parenteral talcum granulomatosis: a complication of narcotic addiction. *Lab Invest* 1962;11:671-4.
- 37 Hopkins GB, Taylor DG. Pulmonary talc granulomatosis. *Am Rev Respir Dis* 1970;101:101-8.
- 38 Groth DH, MacKay GR, Crable JV, Cochran TH. Intravenous injection of talc in a narcotics addict. *Arch Pathol* 1972;94:171-8.
- 39 Marschke G, Haber L, Feinberg M. Pulmonary talc embolisation. *Chest* 1975;68:824-6.
- 40 Arnett EN, Battle WE, Russo JV, Roberts WC. Intravenous injection of talc-containing drugs intended for oral use: a cause of pulmonary granulomatosis and pulmonary hypertension. *Am J Med* 1976;60:711-8.
- 41 Robertson CH, Reynolds RC, Wilson JE. Pulmonary hypertension and foreign body granulomas in intravenous drug abusers: documentation by cardiac catheterisation and lung biopsy. *Am J Med* 1976;61:657-64.
- 42 Butch AJ, Yokel RA, Sigell LT, et al. Misuse and pulmonary complications of injecting pentazocine and triphenylamine tablets. *Clin Toxicol* 1979;14:301-6.
- 43 Pare JAP, Fraser RG, Hogg JC, Howlett JG, Murphy SB. Pulmonary "main-line" granulomatosis: talcosis of intravenous methadone abuse. *Medicine (Baltimore)* 1979; 58:229-39.
- 44 Houck RJ, Bailey GL, Daroca PJ, Brazda F, Johnson FB, Klein RC. Pentazocine abuse. *Chest* 1980;77:227-9.
- 45 Waller BF, Brownlee WJ, Roberts WC. Self-induced pulmonary granulomatosis. *Chest* 1980;78:90-4.
- 46 Bloor RN, Smallbridge NJF. Intravenous use of slow release morphine sulphate tablets. *Br Med J* 1990;300:640-1.
- 47 Von Glahn WC, Hall JW. The reaction produced in the pulmonary arteries by emboli of cotton fibres. *Am J Pathol* 1949;25:575-9.
- 48 Johnston WH, Waisman J. Pulmonary corn-starch granulomas in a drug user: light and electron microscopic study of a case. *Arch Pathol* 1971;92:196-202.
- 49 Wendt VE, Puro HE, Shapiro J, Matthews W, Wolf PL. Angiothrombotic pulmonary hypertension in addicts: "blue velvet" addiction. *JAMA* 1964;188:755-7.
- 50 Tomashefski JF, Hirsch CS. The pulmonary vascular lesions of intravenous drug abuse. *Hum Pathol* 1980; 11:133-45.
- 51 Puro HE, Wolf PL, Skirgaudes J, Vasquez J. Experimental production of human "blue velvet" and "red devil" lesions. *JAMA* 1966;197:1100-4.
- 52 Crouch E, Churg A. Progressive massive fibrosis of the lung secondary to intravenous injection of talc: a pathologic and mineralogic analysis. *Am J Clin Pathol* 1983;80:520-6.
- 53 Douglas FG, Kafilmont KJ, Patt NL. Foreign particle embolism in drug addicts: respiratory pathophysiology. *Ann Intern Med* 1971;75:865-72.
- 54 Vevaina JR, Civantos F, Viamonte M, Avery WG. Emphysema associated with talcum granulomatosis in a drug addict. *South Med J* 1974;67:113-6.
- 55 Brown DG, Aquirre A, Weaver A. 67-gallium scanning in talc-induced pulmonary granulomatosis. *Chest* 1980;77: 561-5.
- 56 Newell GC, Reginato AJ, Auerbach D, O'Connor CR, Nelson P. Pulmonary granulomatosis secondary to pentazocine abuse mimicking connective tissue diseases. *Am J Med* 1988;85:890-2.
- 57 Pare JP, Cote G, Fraser RS. Long-term follow-up of drug abusers with intravenous talcosis. *Am Rev Respir Dis* 1989;139:233-41.
- 58 Berke RA, Wilson AF, Spiritus EM. Lung scans in asymptomatic heroin addicts. *Am Rev Respir Dis* 1973;108: 994-6.
- 59 Tansuwan C, Richardson WD, Lira J. Angiotensin one converting enzyme in granulomatous reaction of the lung [abstract]. *Am Rev Respir Dis* 1981;123 (suppl):40.
- 60 Farber HW, Fairman RP, Glauser FL. Talc granulomatosis: laboratory findings similar to sarcoidosis. *Am Rev Respir Dis* 1982;125:258-61.
- 61 O'Connor RN, Brunham RC, Bowden DH. Pulmonary talc granulomatosis mimicking pneumocystis carinii pneumonia. *Can Med Assoc J* 1988;138:53-4.
- 62 Ben-Haim SA, Ben-Ami H, Edoute Y, Goldstein N, Barzilai D. Talcosis presenting as pulmonary infiltrates in an HIV-positive heroin addict. *Chest* 1988;94:656-8.
- 63 Rodnan GP. When is scleroderma not scleroderma? *Bull Rheum Dis* 1981;31:7-10.
- 64 Spain DM. Patterns of pulmonary fibrosis as related to pulmonary function. *Ann Intern Med* 1950;33:1150-5.

- 65 Tomaszefski JF, Hirsch CS, Jolly PN. Microcrystalline cellulose pulmonary embolism and granulomatosis. *Arch Pathol Lab Med* 1981;105:89-93.
- 66 Purkiss R. Effects and distribution of intravenously administered cellulose particles in mice. *J Pharm Pharmacol* 1975;27:290-2.
- 67 Cassar-Pullicino VN, Taylor DN, Fitz-Patrick JD. Multiple metallic mercury emboli. *Br J Radiol* 1985;58:470-4.
- 68 Clague JR, Gray HH, Kay PH. Self injection with mercury. *Br Med J* 1989;299:1567.
- 69 Murch CR. Quicksilver heart. *Br Med J* 1989;299:1056.
- 70 Shaffer BA, Schmidt-Nowara WW. Multiple small opacities of metallic density in the lung. *Chest* 1989;96:1179-81.
- 71 Shapiro S. Passage of a hollow needle into the venous blood stream to the heart, through the cardiac wall, and into the thorax. *Am Heart J* 1941;22:835-8.
- 72 Lewis TD, Henry DA. Needle embolus: a unique complication of intravenous drug abuse. *Ann Emerg Med* 1984;14:906-8.
- 73 Angeolos MG, Sheets CA, Zych PR. Needle emboli to lung following intravenous drug abuse. *J Emerg Med* 1986;4:391-6.
- 74 Griebble HG, Rippon JW, Maliwan N, Daun V. Scopulariopsis and hypersensitivity pneumonitis in an addict. *Ann Intern Med* 1975;83:326-9.
- 75 Camargo G, Colp C. Pulmonary function studies in ex-heroin users. *Chest* 1975;67:331-4.
- 76 Overland ES, Nolan AJ, Hopewell PC. Alteration of pulmonary function in intravenous drug misusers. *Am J Med* 1980;68:231-7.
- 77 Soin JS, McKusick KA, Wagner HN. regional lung-function abnormalities in narcotic addicts. *JAMA* 1973;224:1717-20.
- 78 Sherman CB, Hudson LD, Pierson DJ. Severe precocious emphysema in intravenous methylphenidate abusers. *Chest* 1987;92:1085-7.
- 79 Strawbridge HTG. Chronic pulmonary emphysema (an experimental study). III. Experimental pulmonary emphysema. *Am J Pathol* 1960;37:391-407.
- 80 Goldstein DS, Karpel JP, Appell D, Williams M. Bullous pulmonary damage in users of intravenous drugs. *Chest* 1986;89:266-9.
- 81 Gurney JW, Bates FT. Pulmonary cystic disease: comparison of *Pneumocystis carinii* pneumatoceles and bullous emphysema due to intravenous drug abuse. *Radiology* 1989;173:27-31.
- 82 Ghodse AH, Myles JS. Asthma in opiate addicts. *J Psychosom Res* 1987;31:41-4.
- 83 Hughes S, Calverley PMA. Heroin inhalation and asthma. *Br Med J* 1988;297:1511-2.
- 84 Mattox KL. Pneumomediastinum in heroin and marijuana users. *J Emerg Med* 1976;5:26-8.
- 85 Lewis JW, Groux N, Elliott JP, Jara FM, Obeid FN, Magilligan DJ. Complications of attempted central venous injections performed by drug abusers. *Chest* 1980;74:613-7.
- 86 Cohen HL, Cohen SW. Spontaneous bilateral pneumothoraces in drug addicts. *Chest* 1986;86:645-7.
- 87 Zorc TG, O'Donnell AE, Holt RW, Pappas LS, Slakey J. Bilateral pyopneumothorax secondary to intravenous drug misuse. *Chest* 1988;93:645-7.
- 88 Bell C, Boark J, Loeffler JR. Pneumothorax in drug abusers: a complication of internal jugular venous injections. *Ann Emerg Med* 1983;12:167-70.