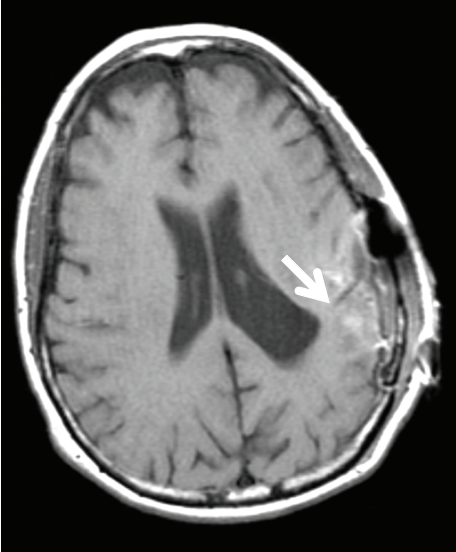
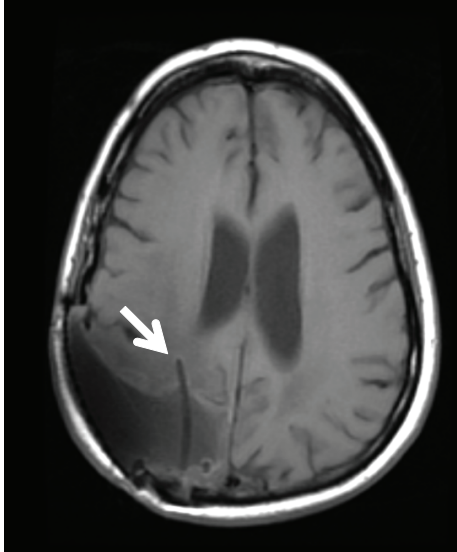


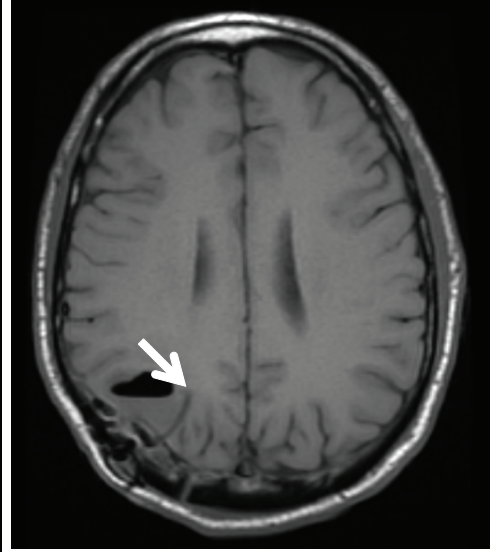
UPN 028



UPN 031



UPN 033



**Fig. S1. Catheter position with respect to resection site.** Non-contrast T1-weighted MRI demonstrating the placement of the reservoir/catheter system after tumor resection. The distal end of the catheter was partially embedded into the tumor resection wall in order to allow for cell delivery both into the cavity and into the peritumoral brain tissue (white arrow).