

Radiologic evidence that hypothalamic gliosis is associated with obesity and insulin resistance in humans

Ellen A. Schur¹, Susan J. Melhorn¹, Seok-Kyun Oh², J. Matthew Lacy³, Kathryn E. Berkseth⁴, Stephan J. Guyenet⁴, Joshua A. Sonnen³, Vidhi Tyagi¹, Mary Rosalynn B. De Leon¹, Mary F. Webb⁵, Zenobia T. Gonsalves¹, Corinne L. Fligner³, Michael W. Schwartz⁴, Kenneth R. Maravilla²

¹Department of Medicine, Division of General Internal Medicine, University of Washington; Seattle, WA; ²Department of Radiology, University of Washington; Seattle, WA; ³Department of Pathology, University of Washington; Seattle, WA; ⁴Department of Medicine, Division of Metabolism, Endocrinology and Nutrition, University of Washington; Seattle, WA; ⁵Department of Epidemiology, University of Washington; Seattle, WA.

Contact Info: Ellen Schur, MD, MS, Harborview Medical Center, 325 Ninth Ave, Box 359780, Seattle, WA 98104 Phone: 206-744-1830 Fax: 206-744-9917 Email: ellschur@u.washington.edu

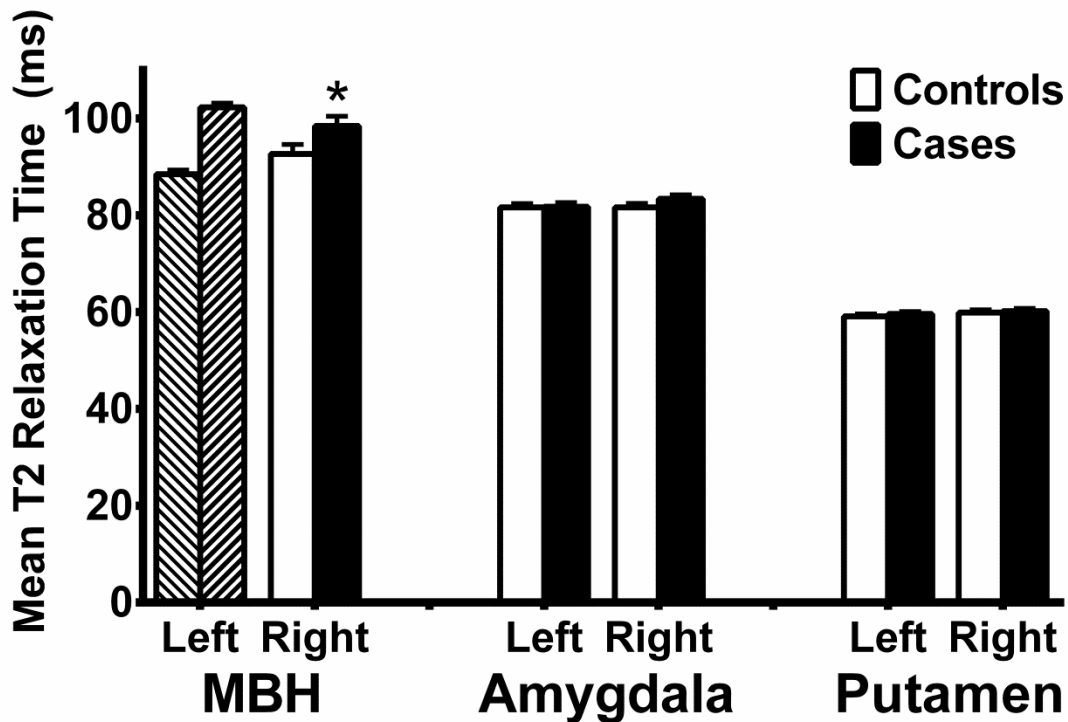


Figure S1. Mean T2 relaxation times in regions of interest. Cases were identified as the tertile with the highest mean T2 relaxation time in the left mediobasal hypothalamus (MBH) (hash marks). T2 relaxation time was higher among cases in the right MBH, but did not differ between cases and controls in reference regions. Data are least square means \pm SEM; P-values determined from linear regression. Data are adjusted for sex and age. N=23 (Controls), 22 (Cases). *P<0.05.