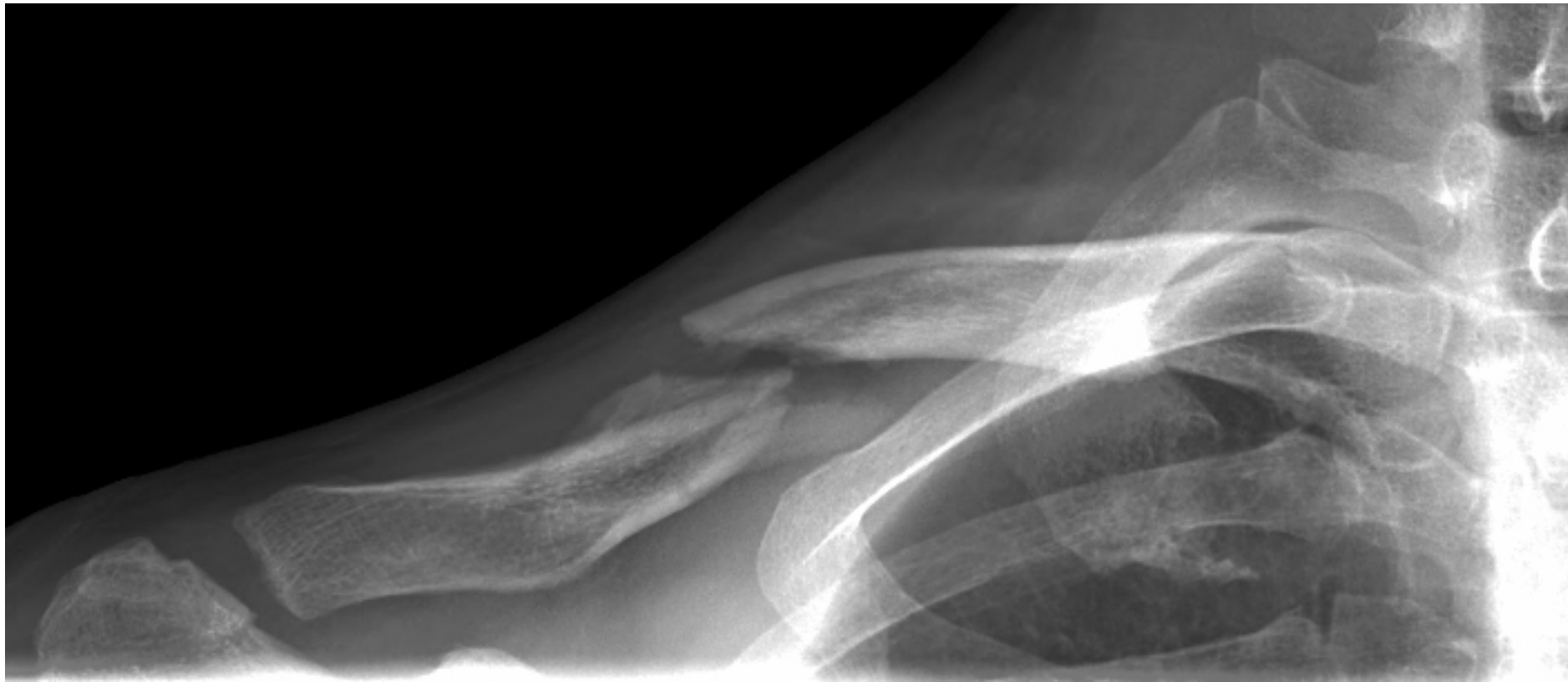

Do surgeons' work styles predict treatment?

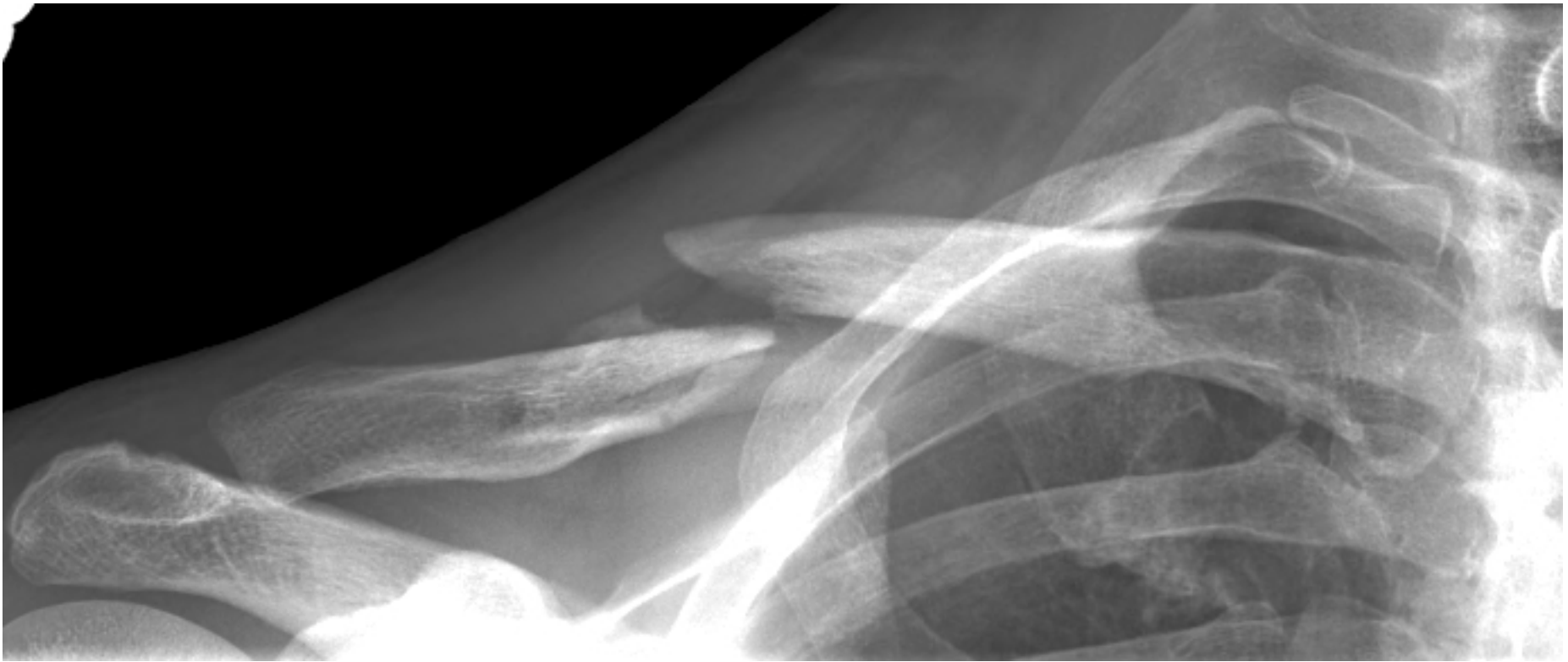Orthopaedic Hand and Upper Extremity Service

Massachusetts General Hospital - Harvard Medical School

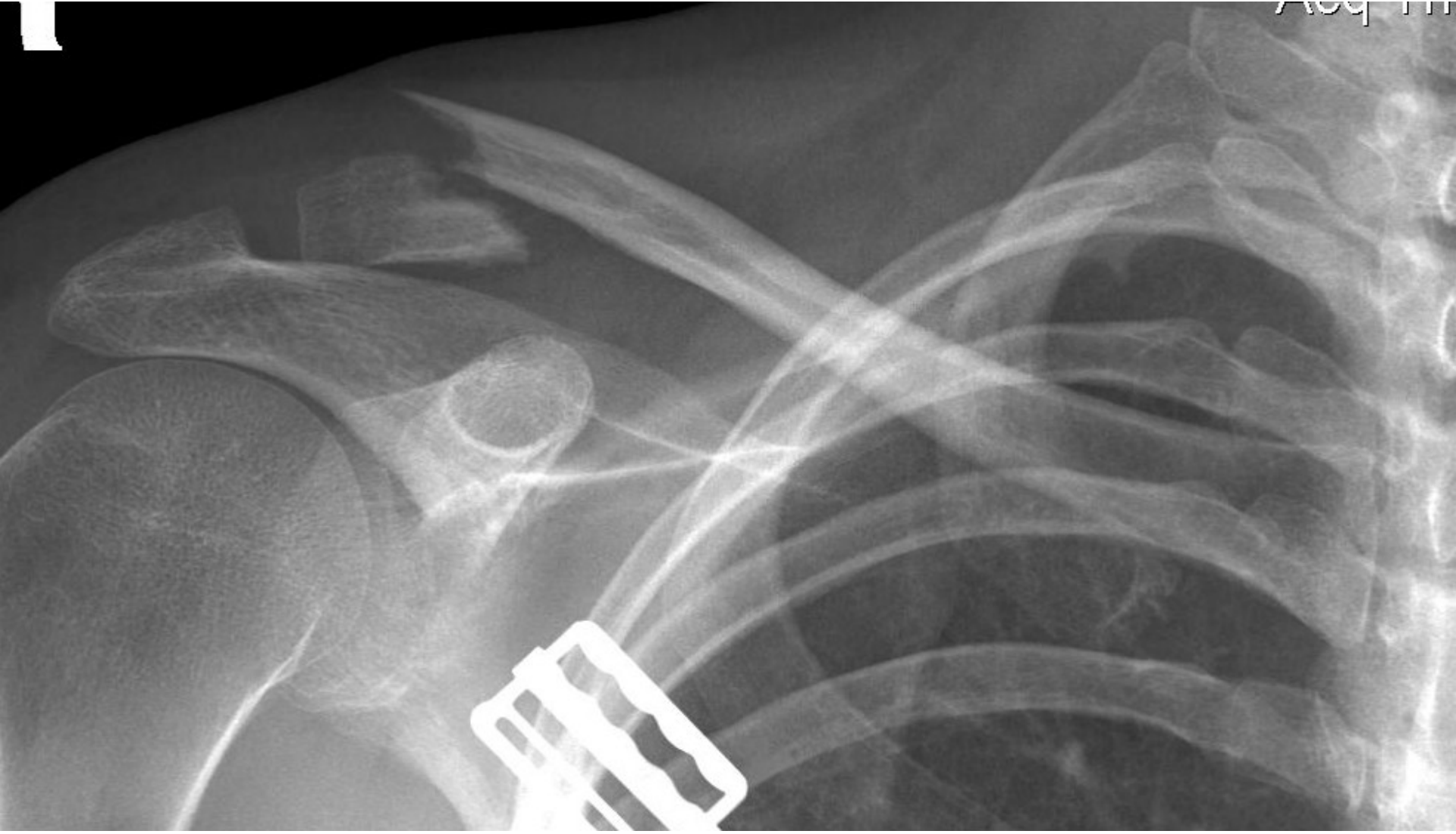
1. Displaced clavicle shaft fracture 1



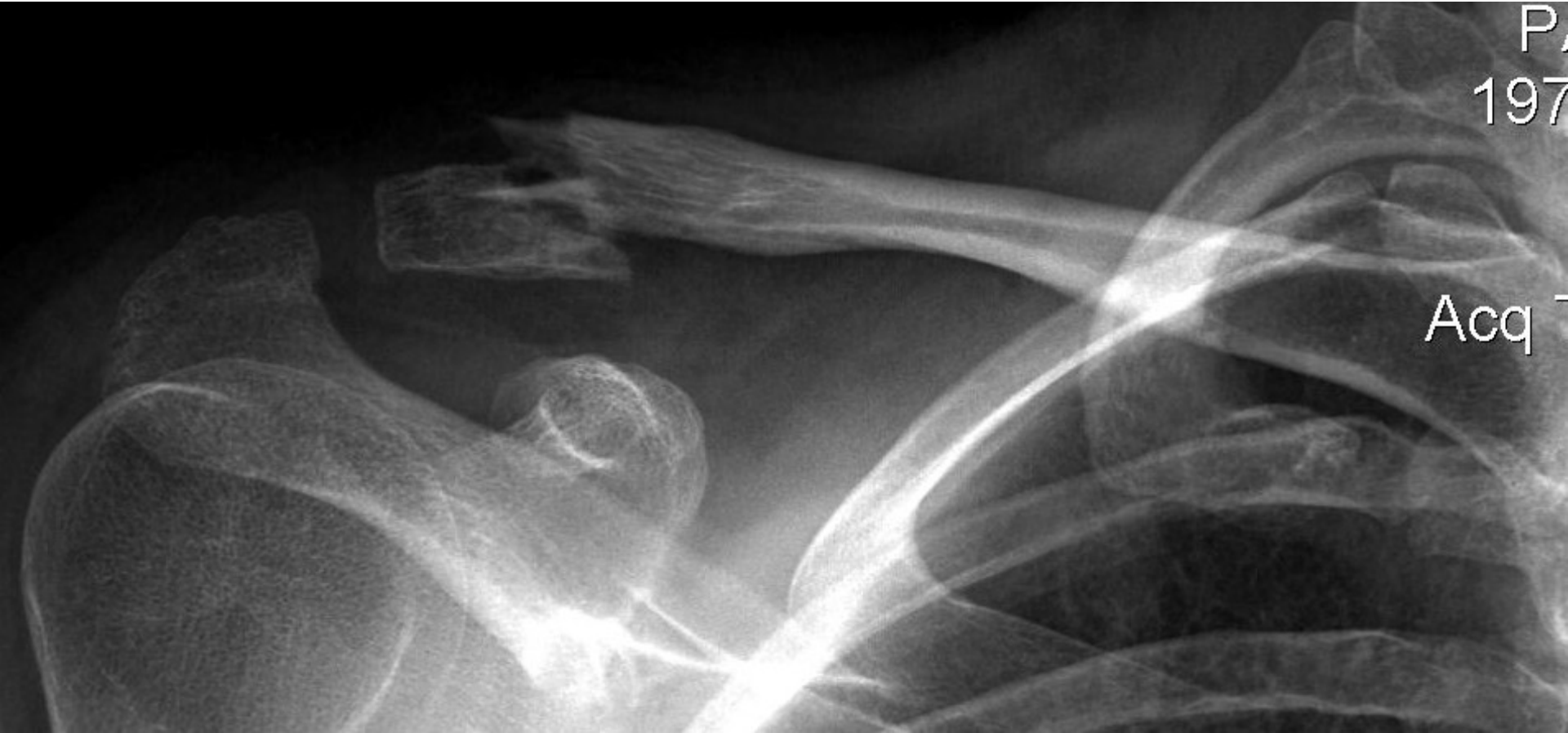1. Displaced clavicle shaft fracture 2



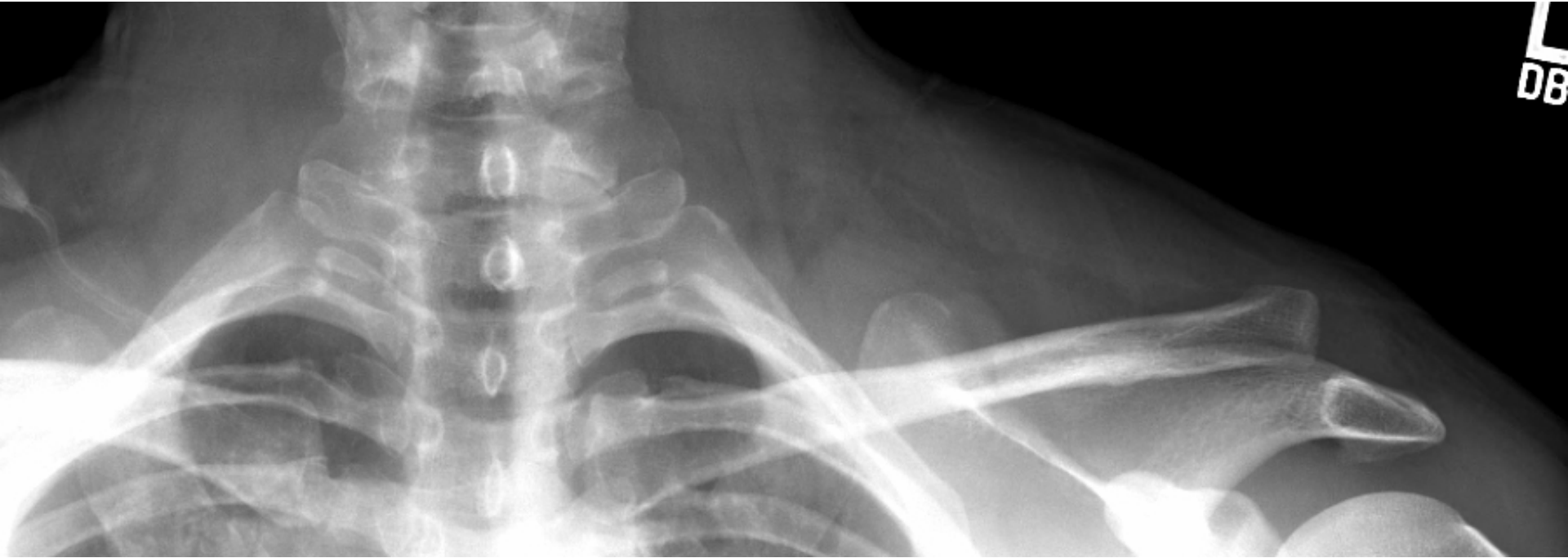2. Displaced lateral clavicle fracture 1



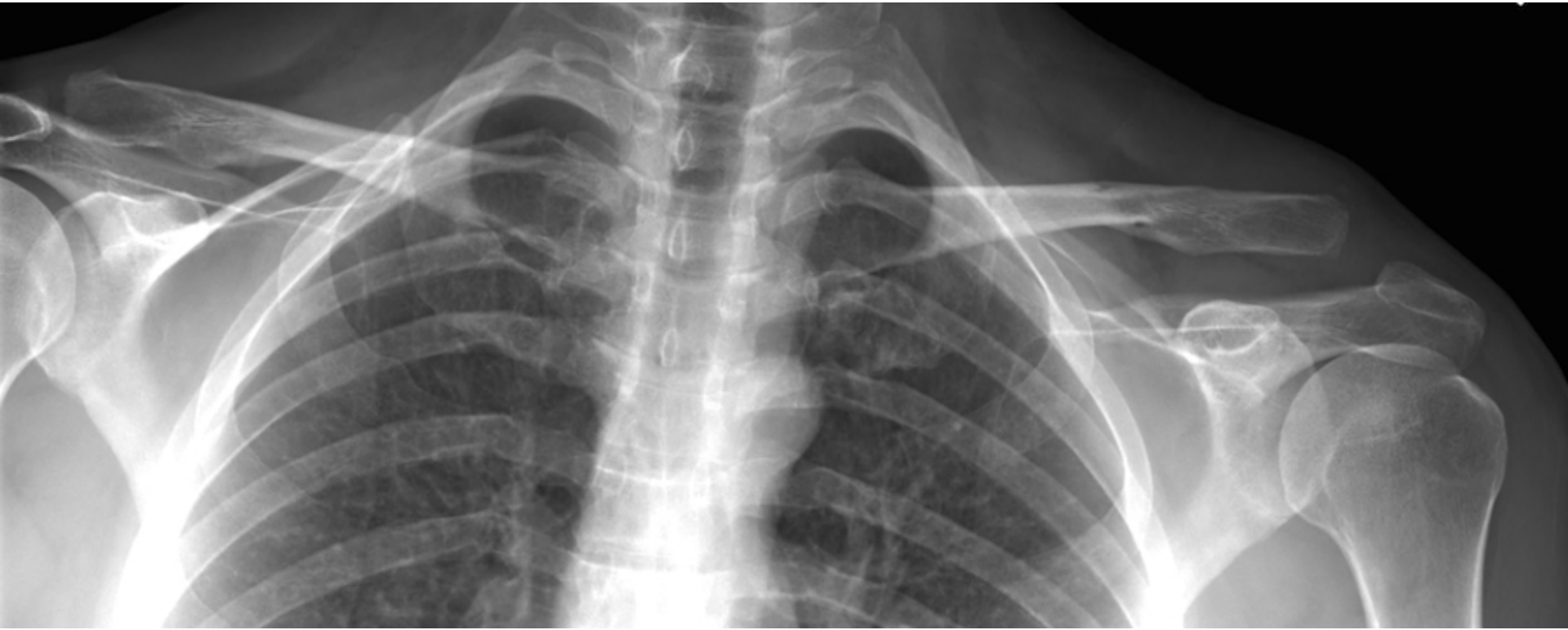2. Displaced lateral clavicle fracture 2



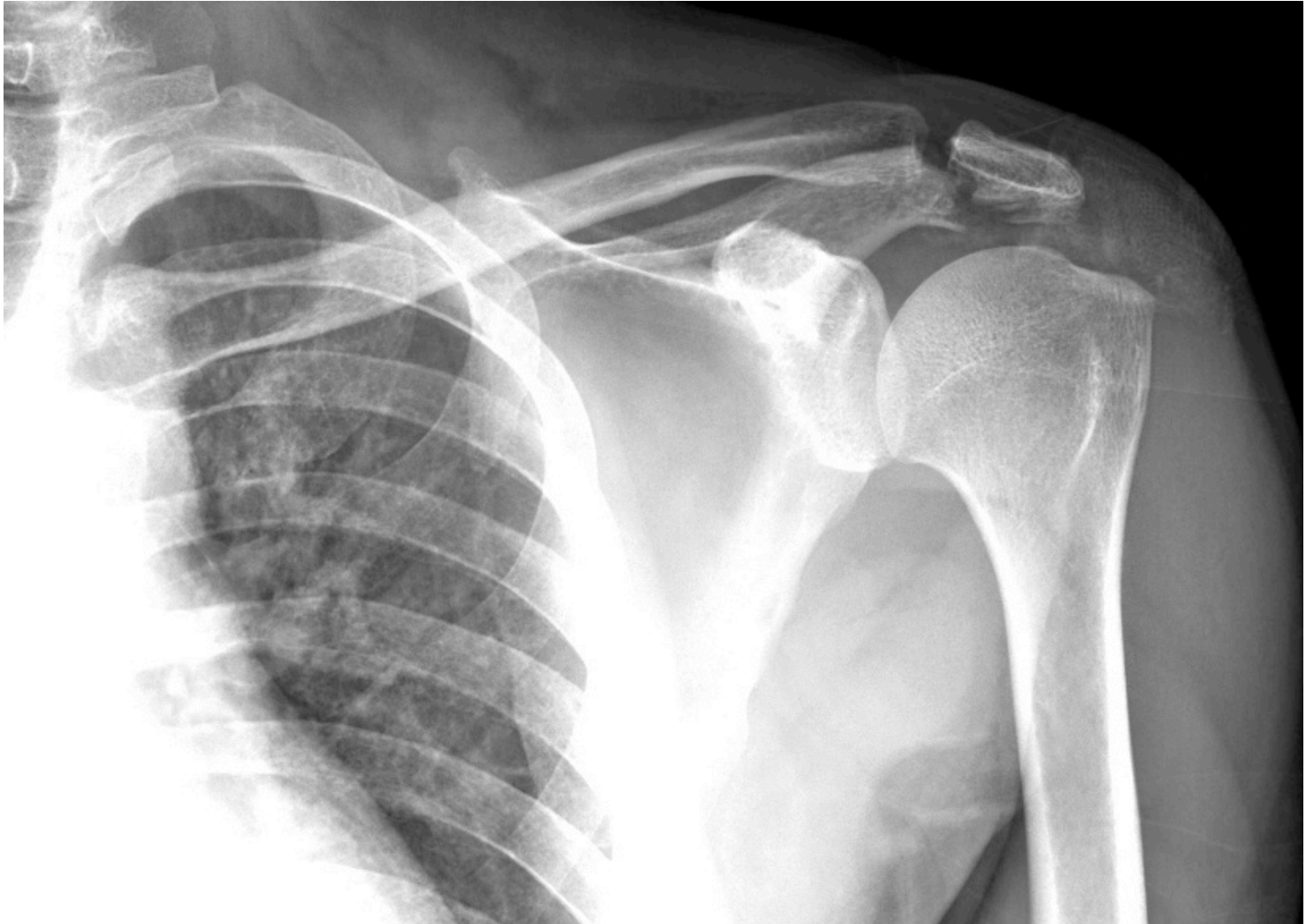3. Displaced acromioclavicular joint dislocation 1



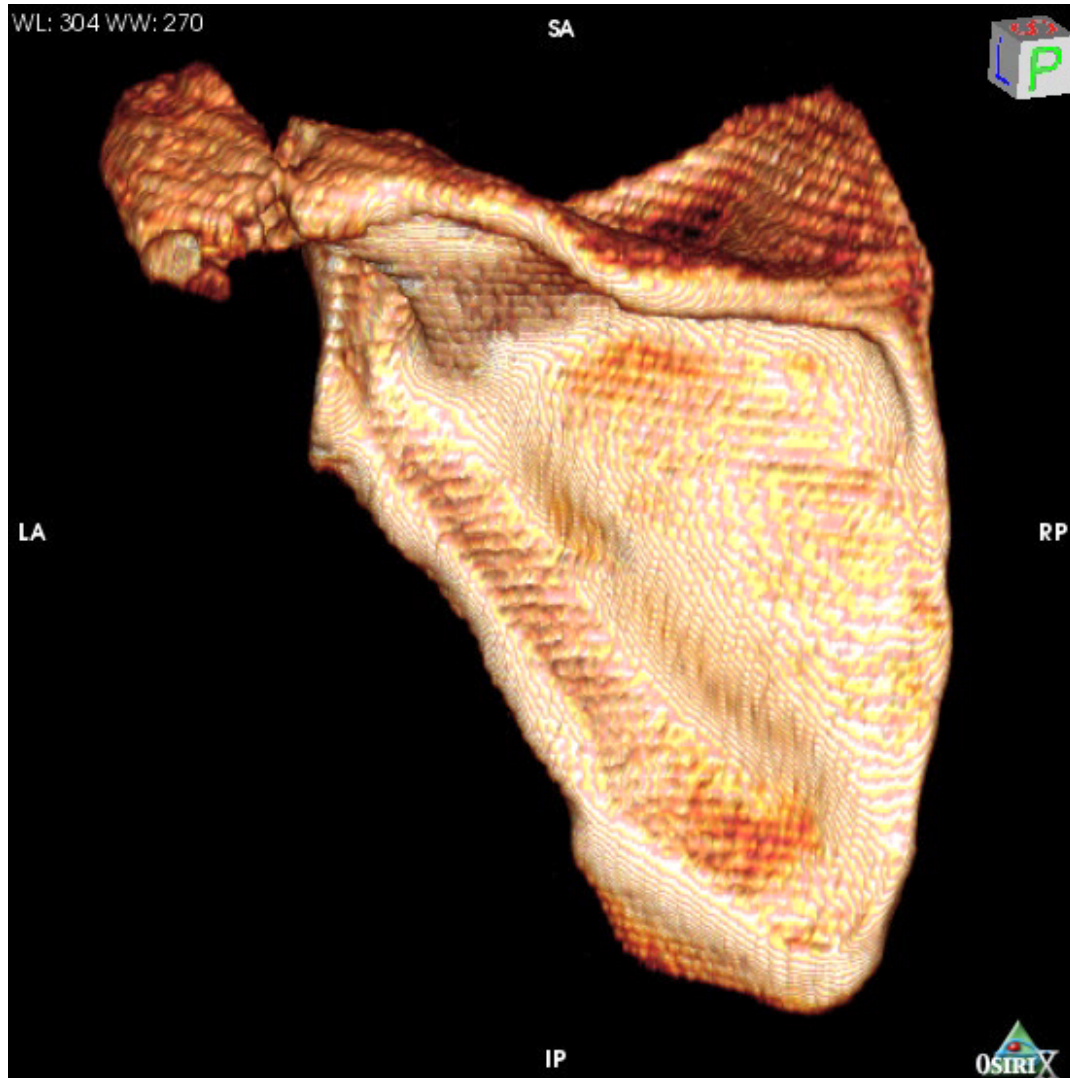
3. Displaced acromioclavicular joint dislocation 1



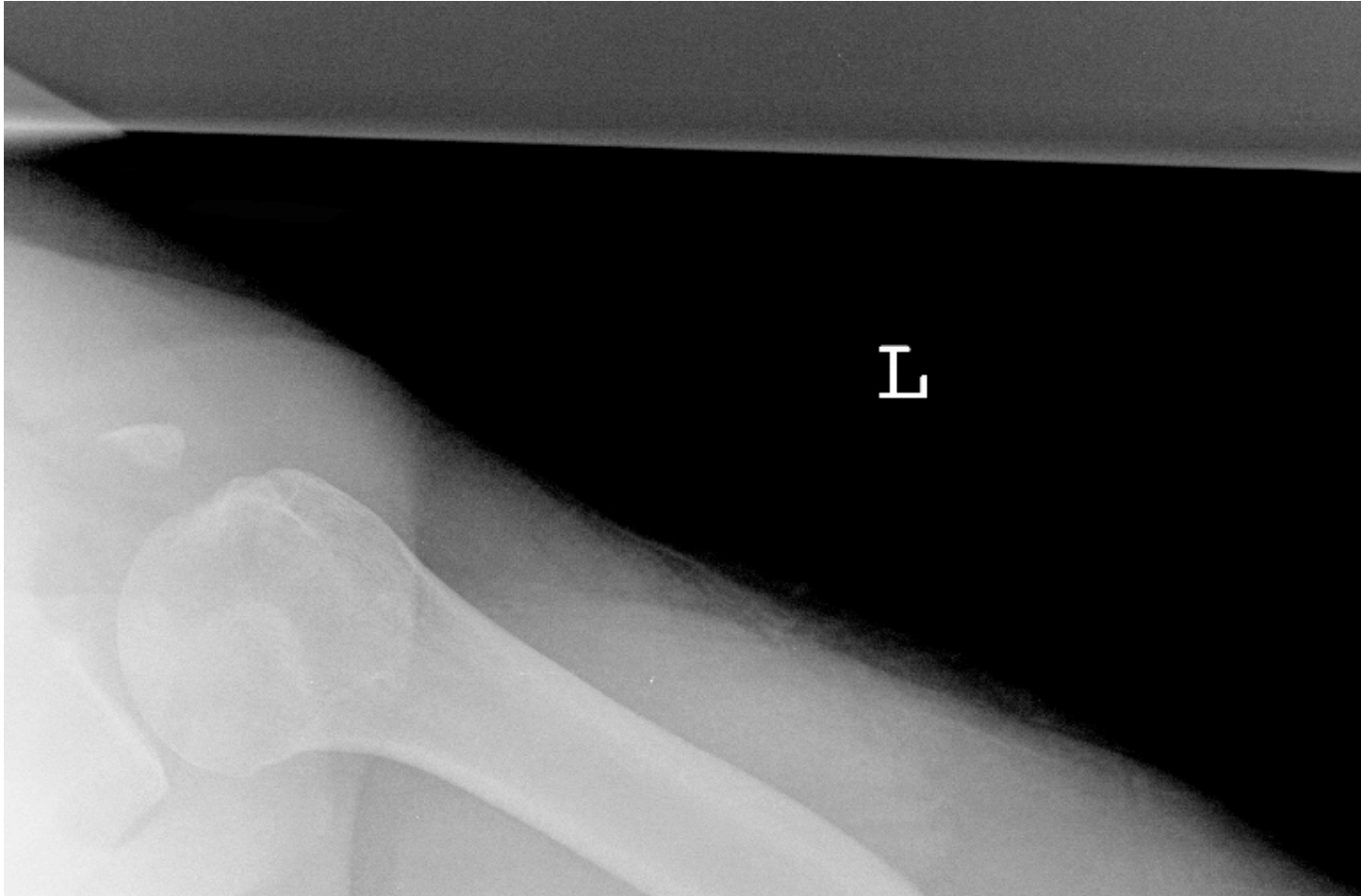4. Acromion fracture 1



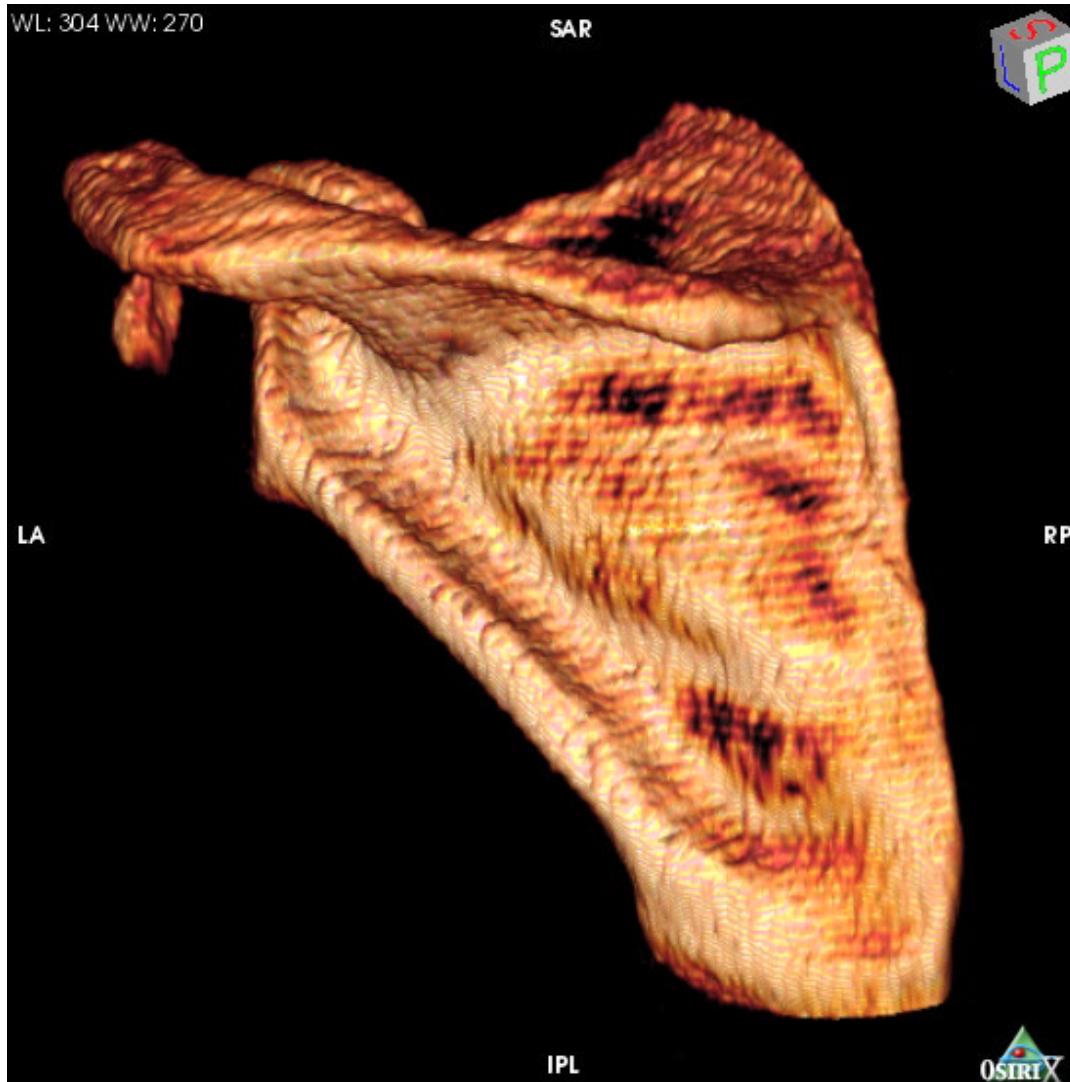
4. Acromion fracture 2



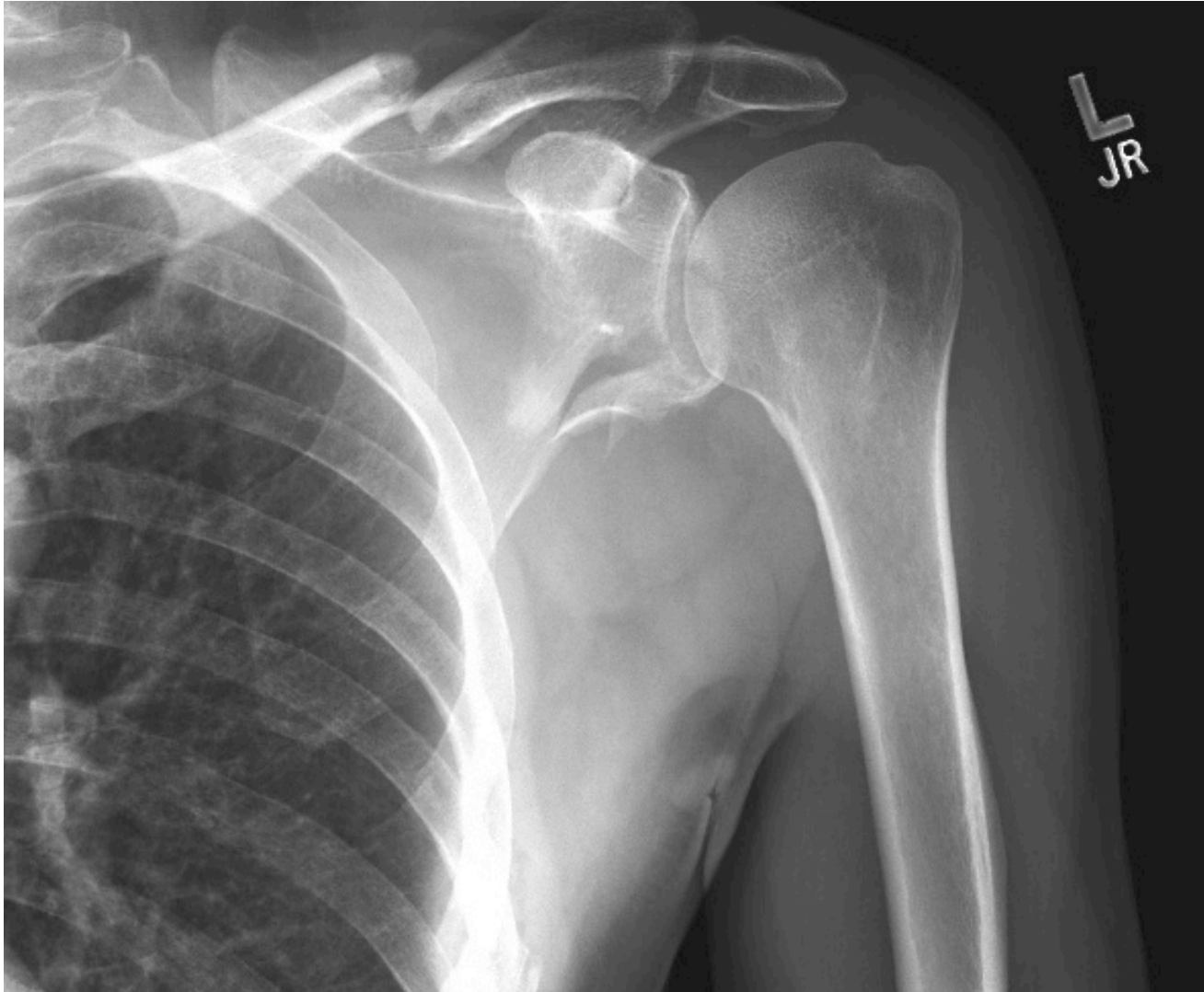5. Coracoid fracture 1



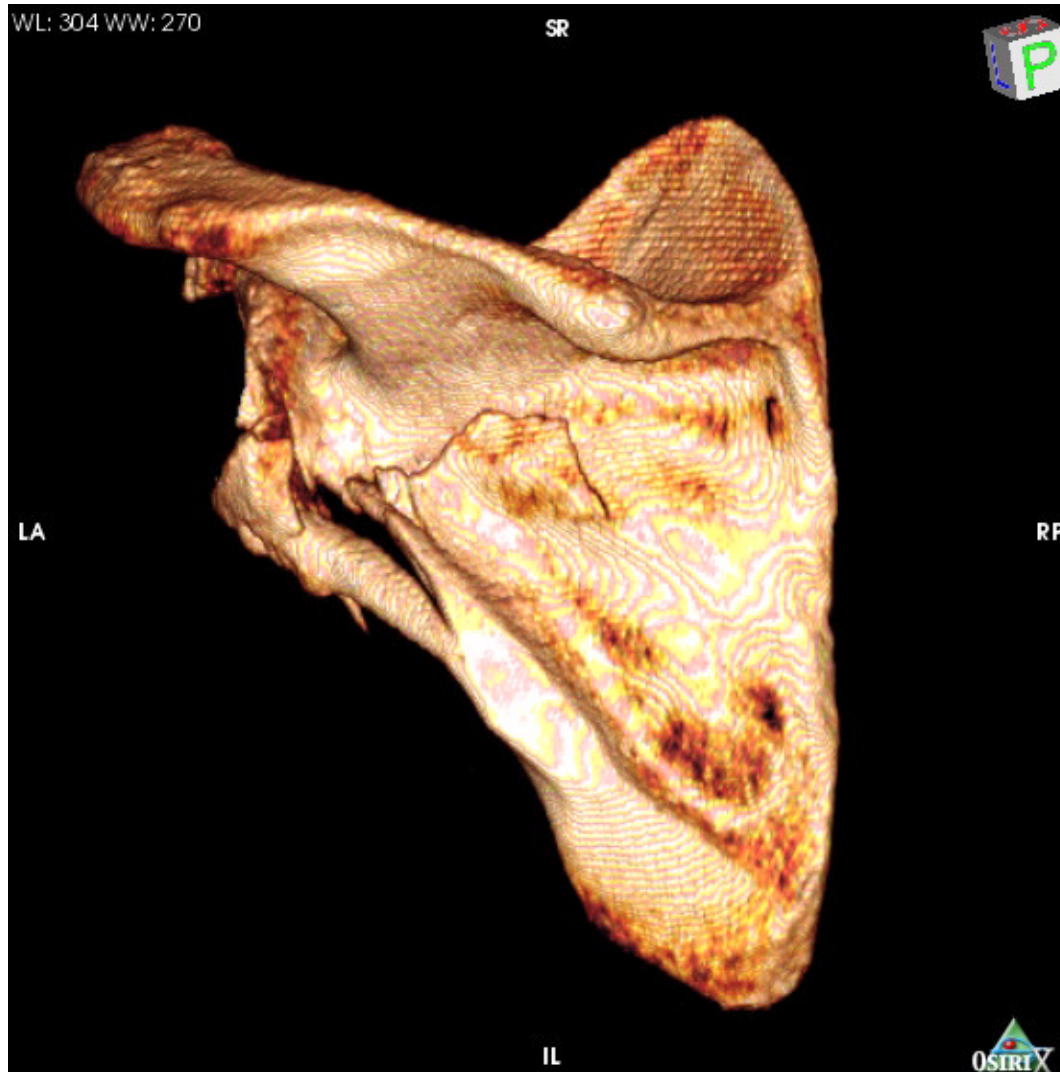5. Coracoid fracture 2



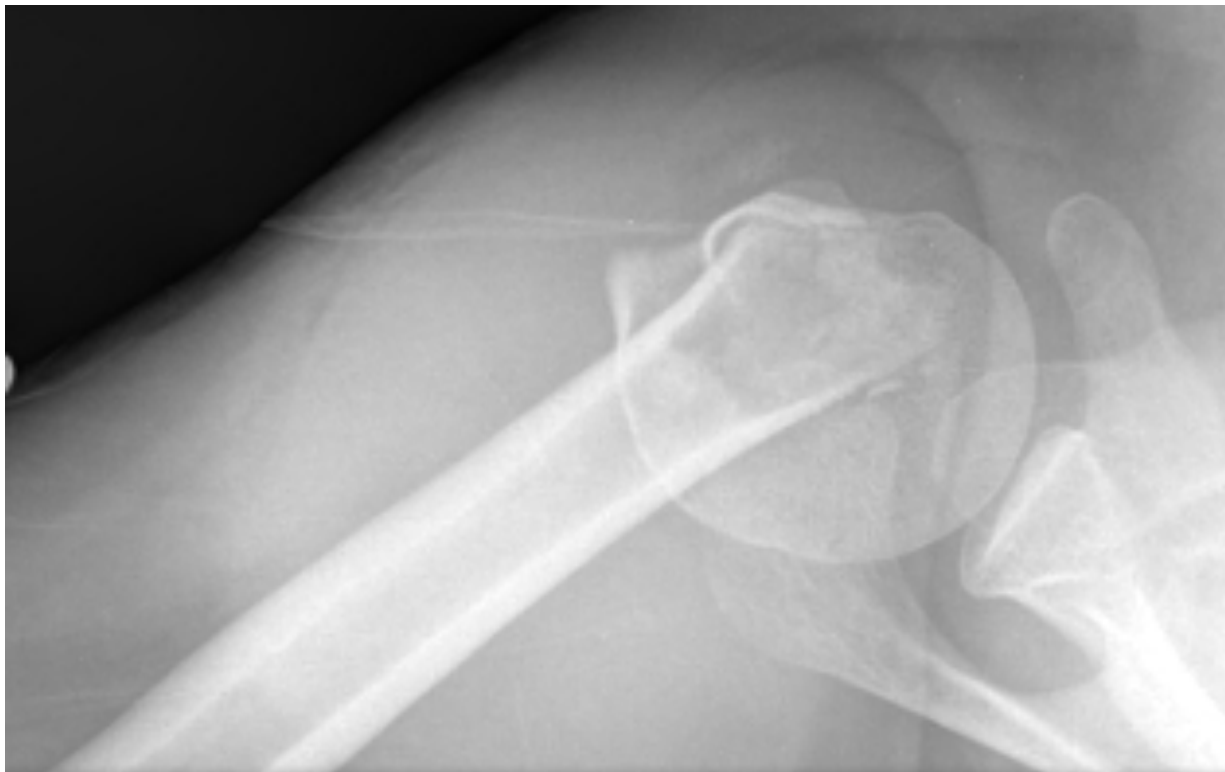6. Glenoid fracture 1



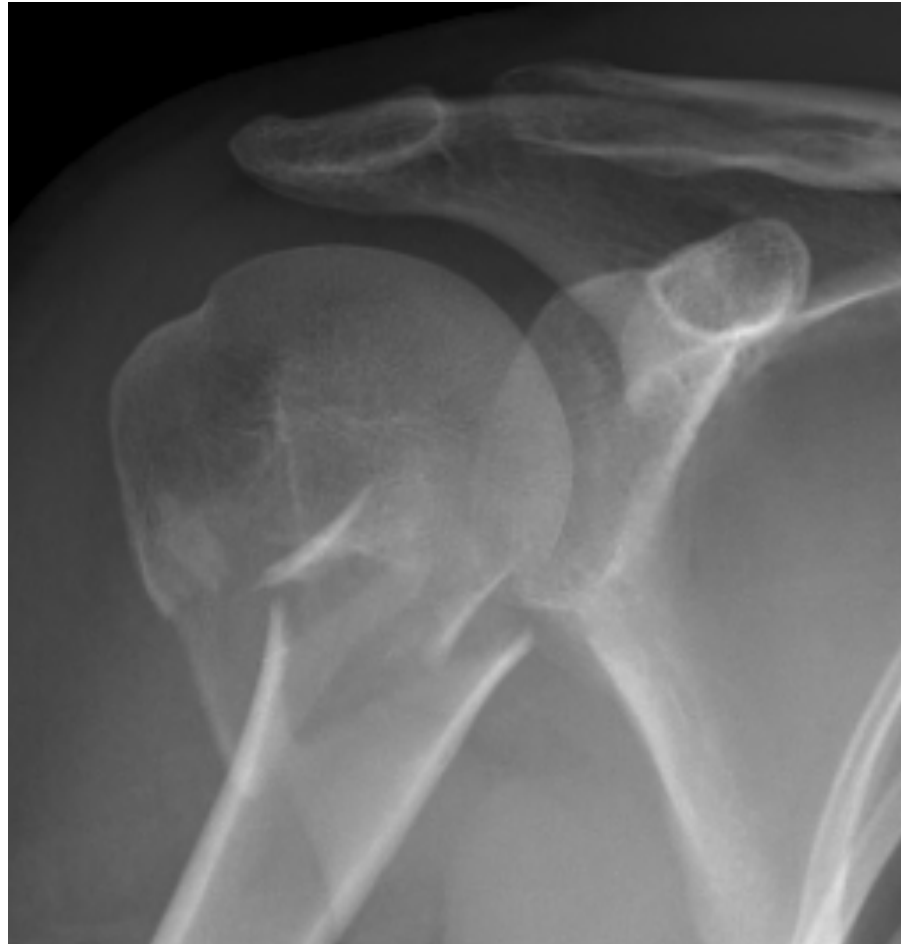6. Glenoid fracture 2



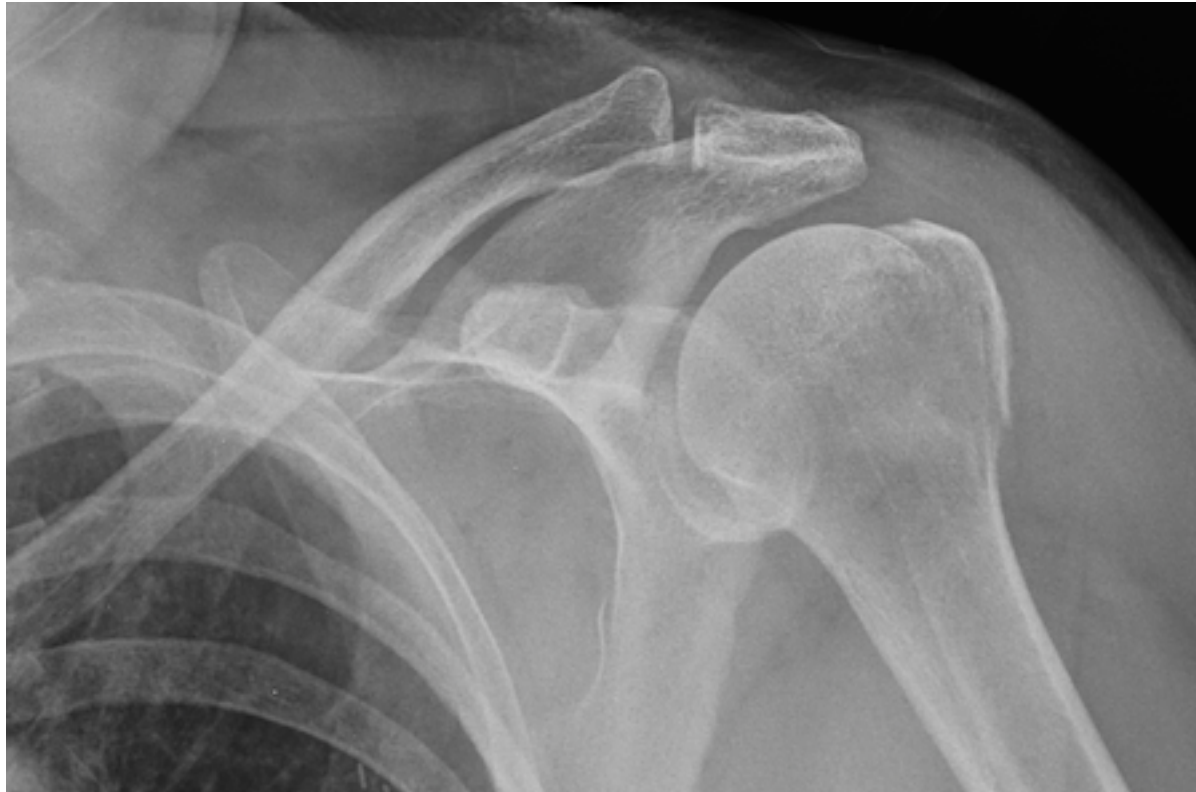7. Proximal humerus surgical neck fracture 1



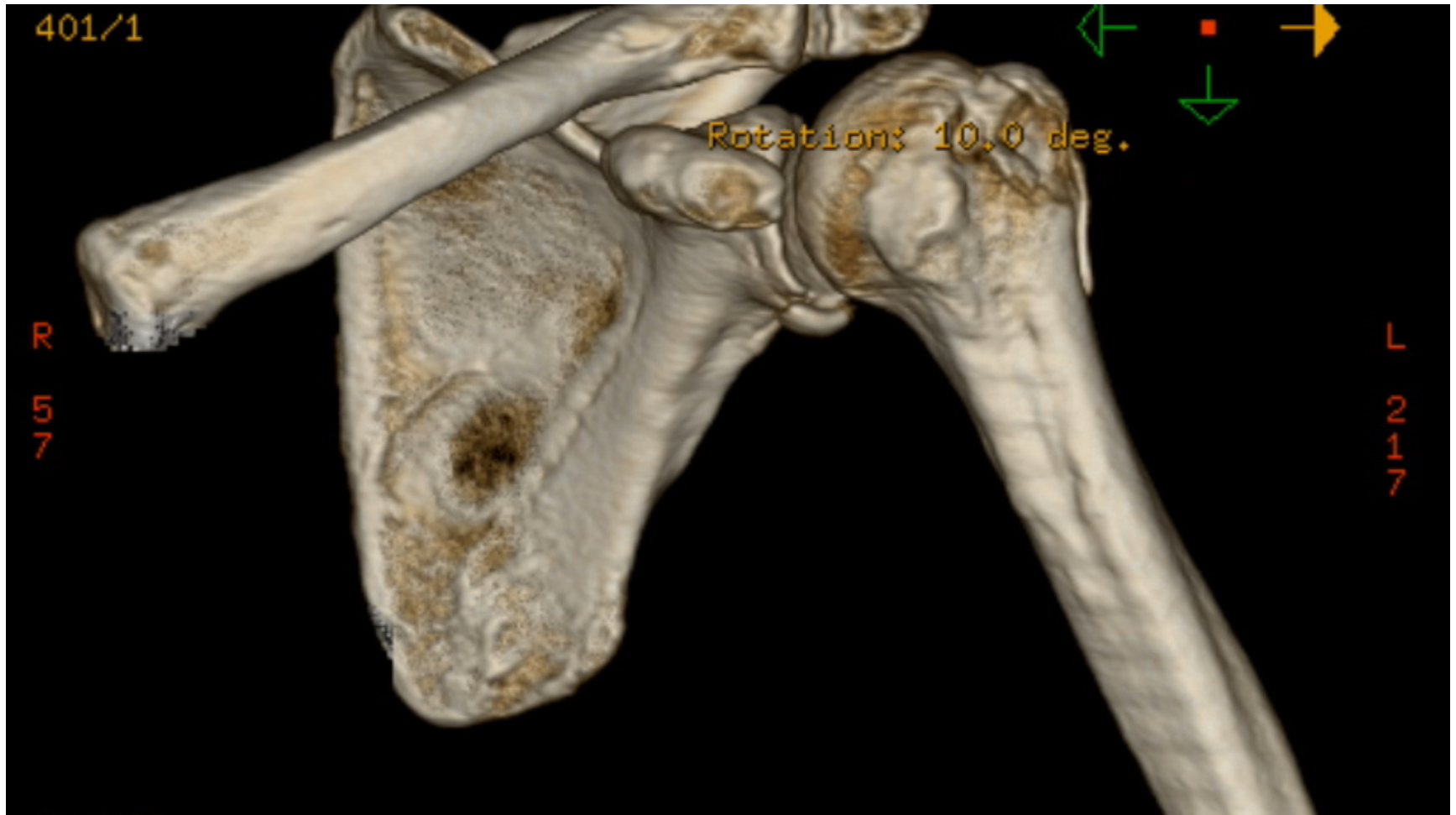
7. Proximal humerus surgical neck fracture 2



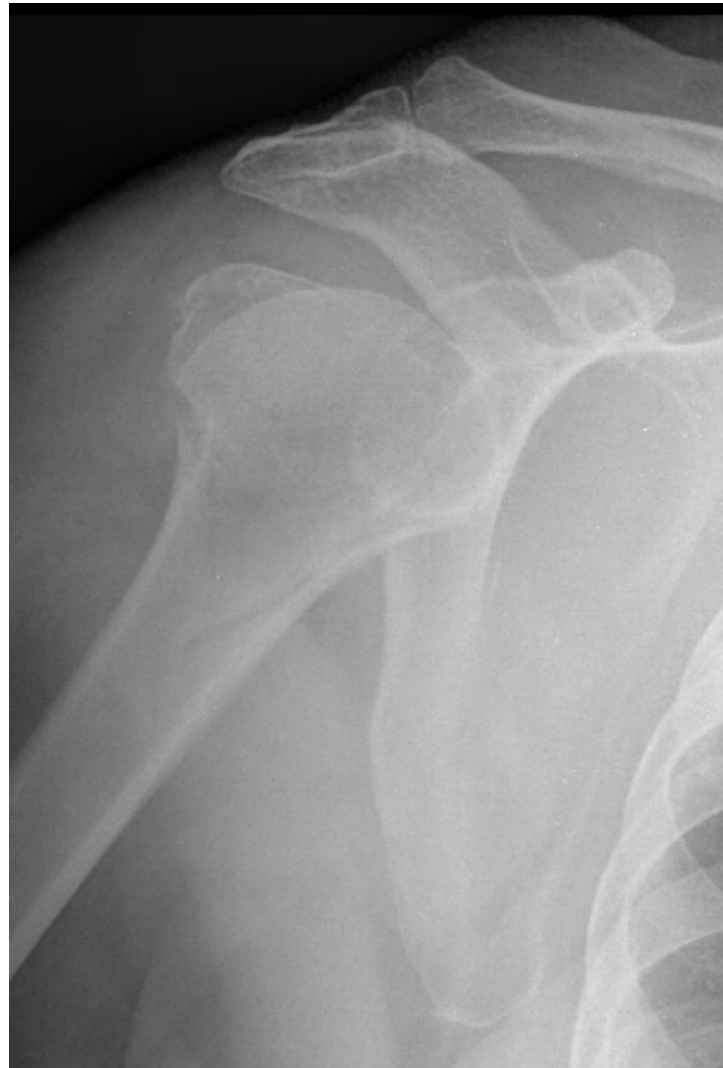8. Proximal humerus greater tuberosity fracture 1



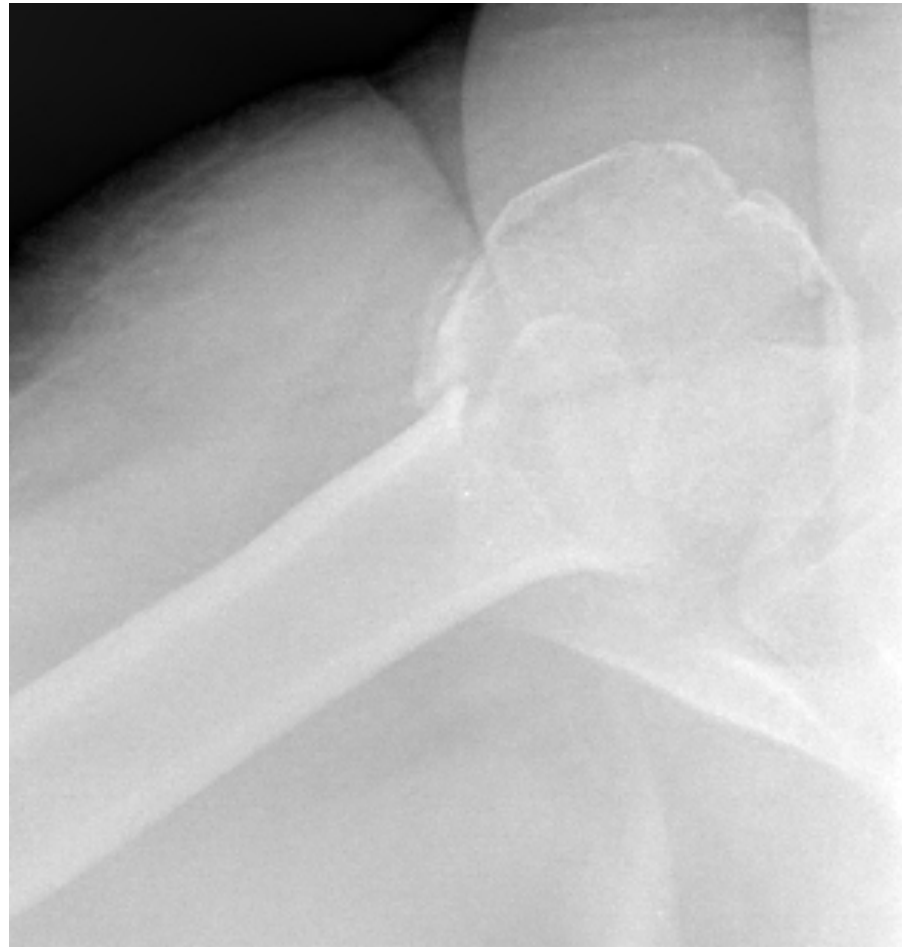8. Proximal humerus greater tuberosity fracture 2



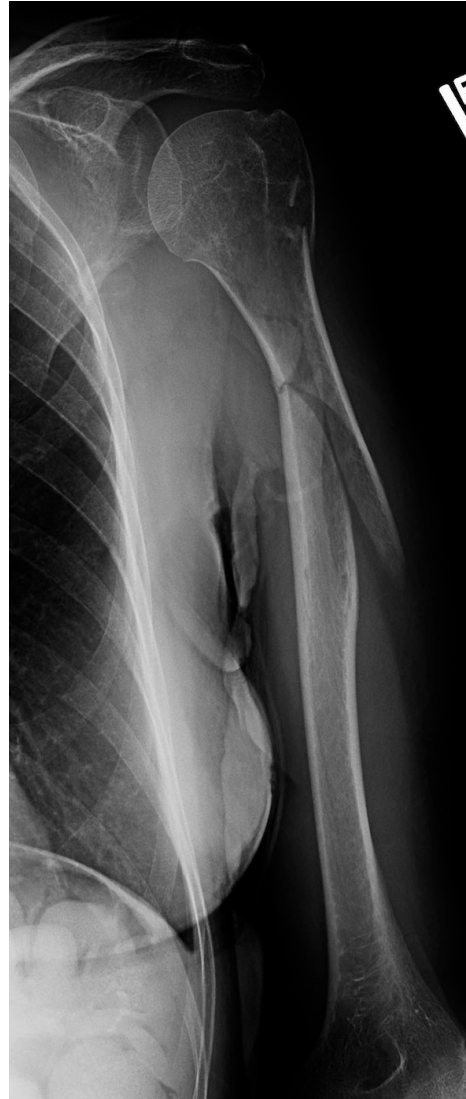9. Proximal humerus valgus impacted fracture 1



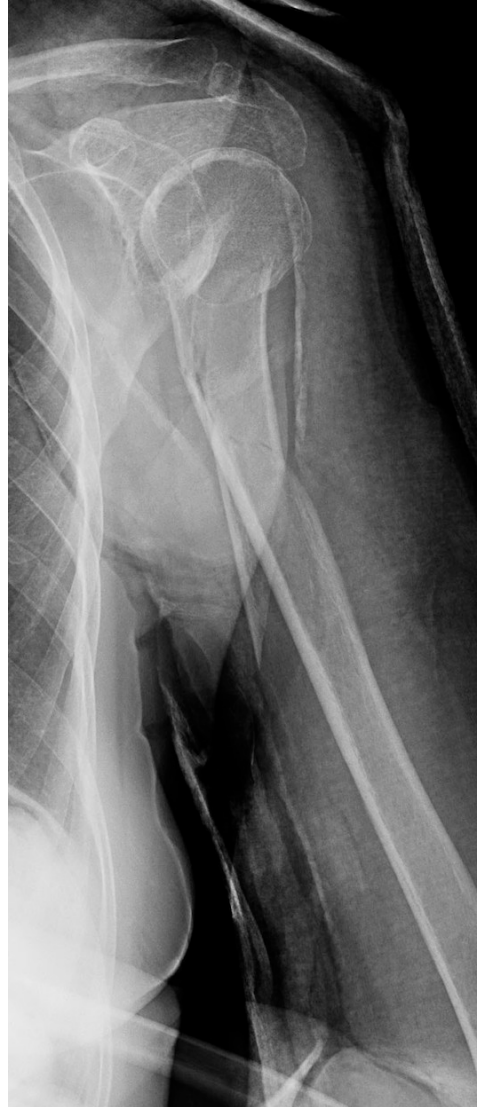9. Proximal humerus valgus impacted fracture 2



10. Proximal diaphyseal humerus fracture 1



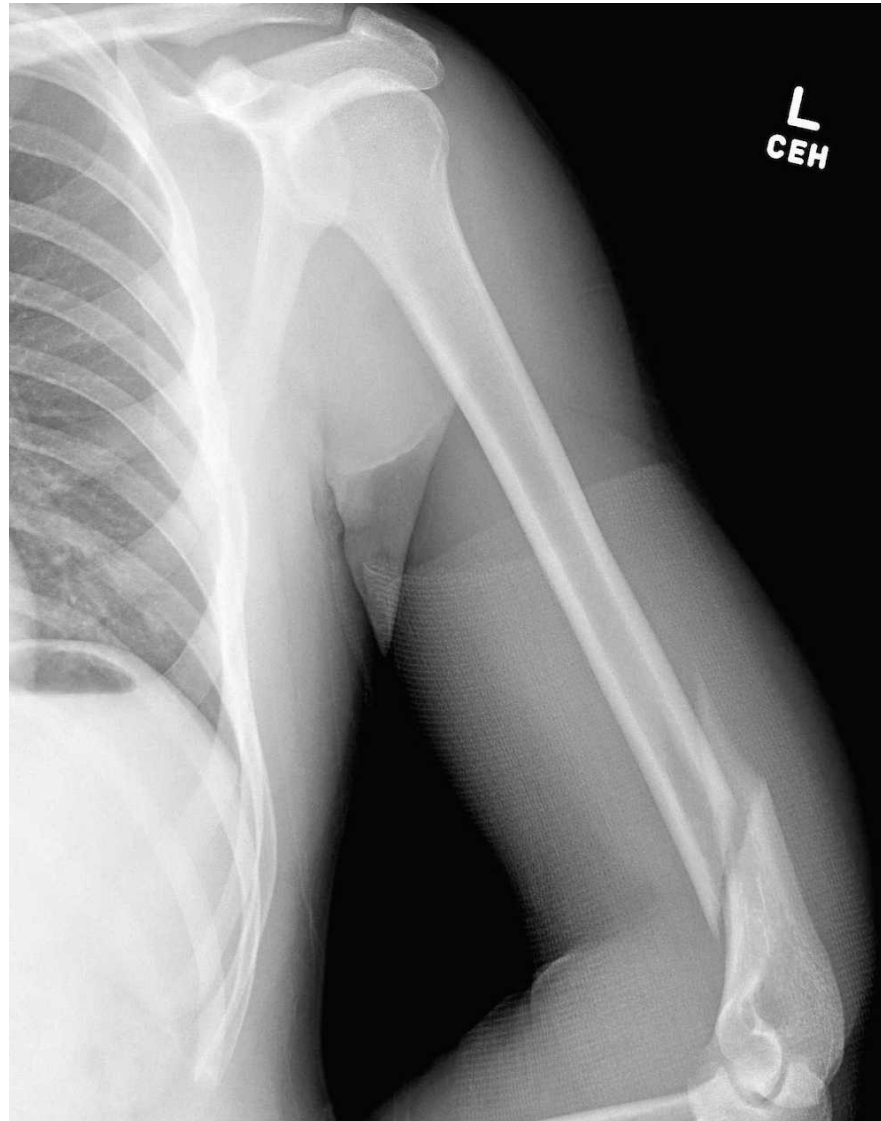10. Proximal diaphyseal humerus fracture 2



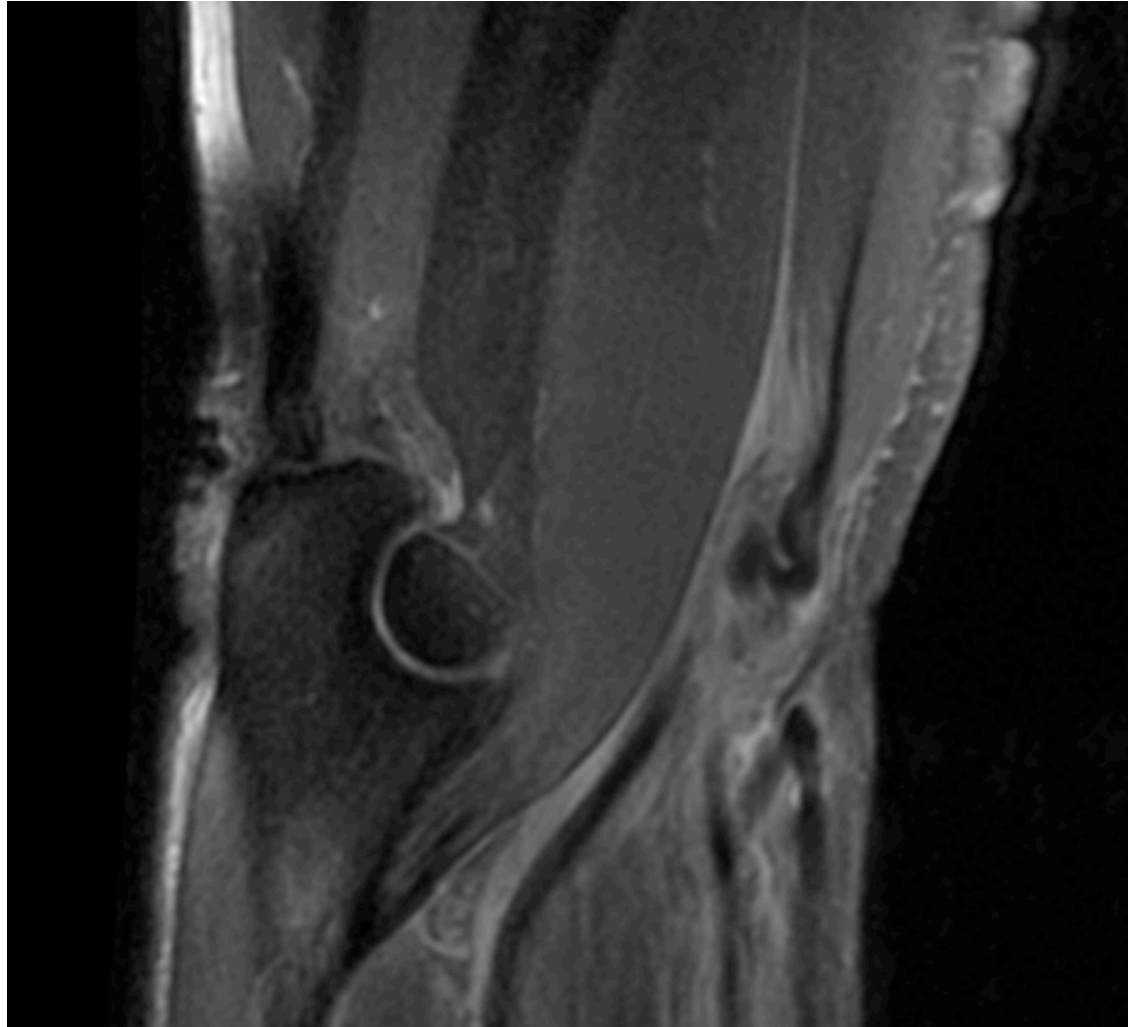
11. Proximal biceps rupture



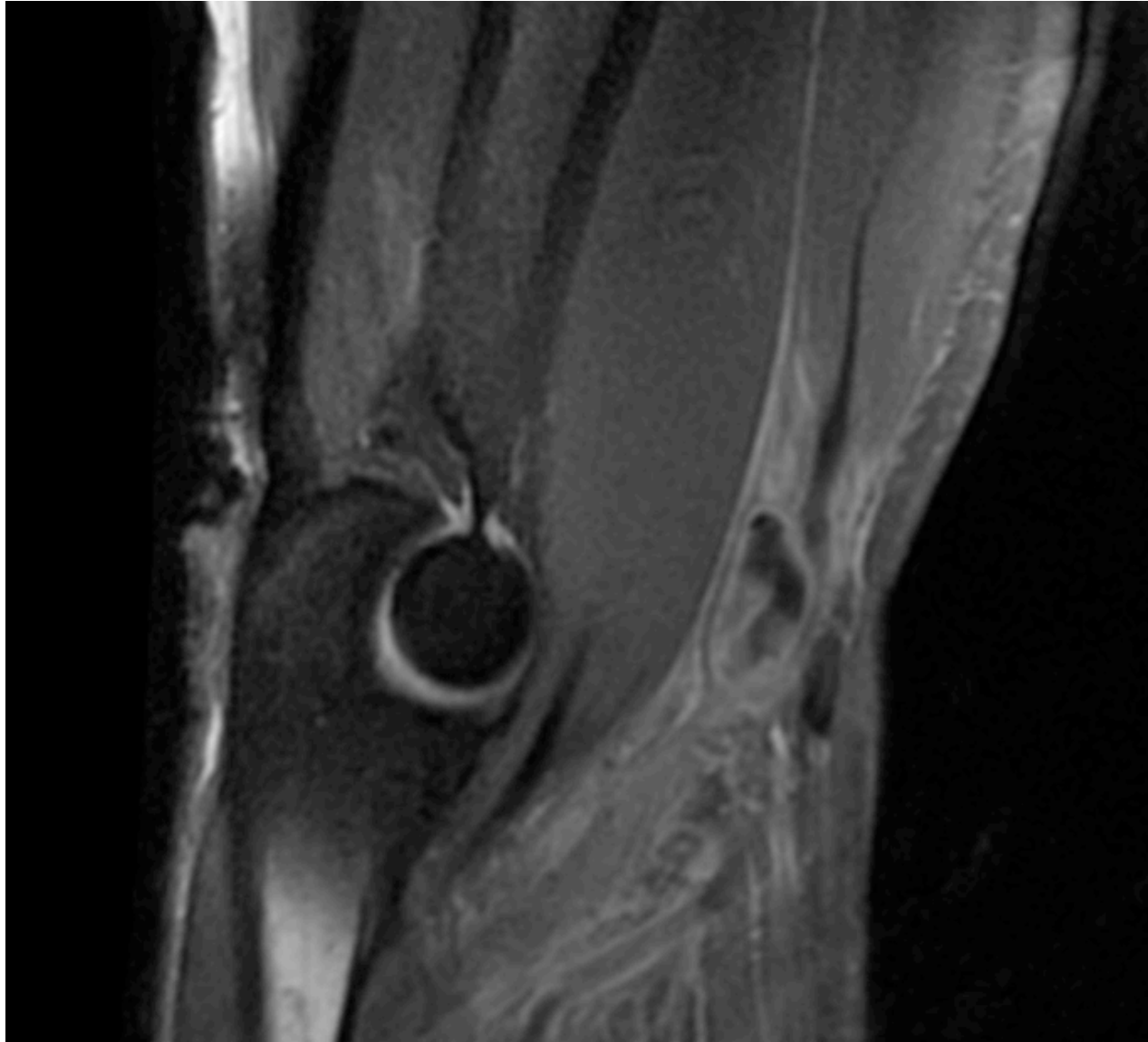
12. Distal diaphyseal humerus fracture



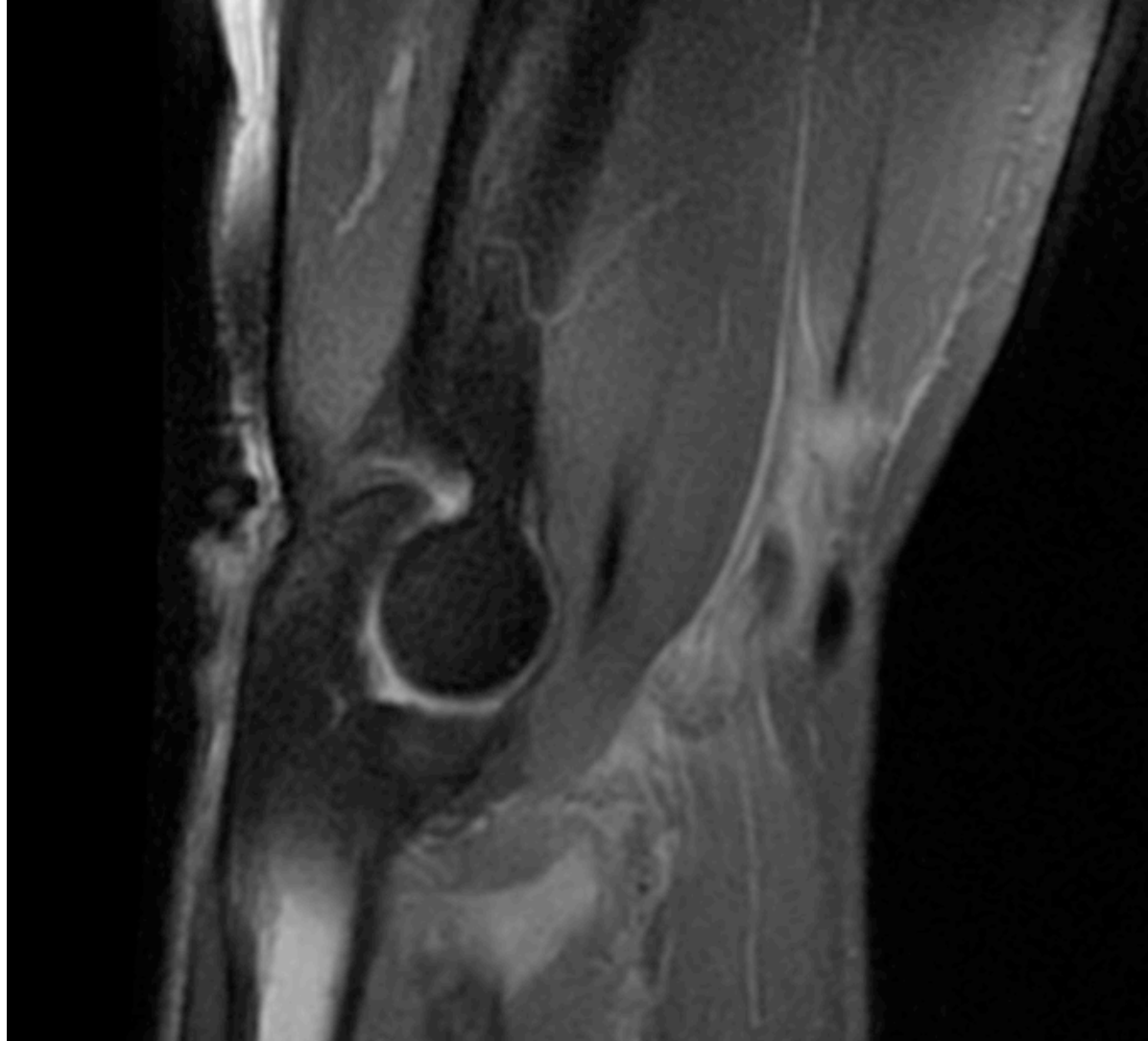
13. Distal Biceps rupture 1



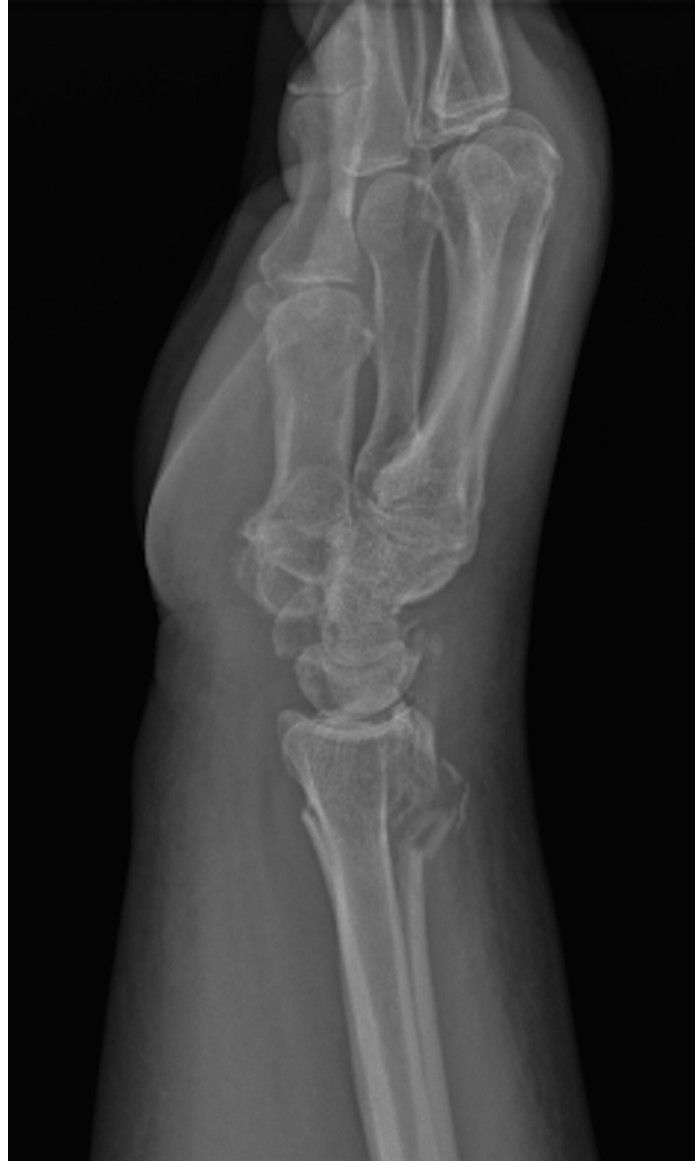13. Distal Biceps rupture 2



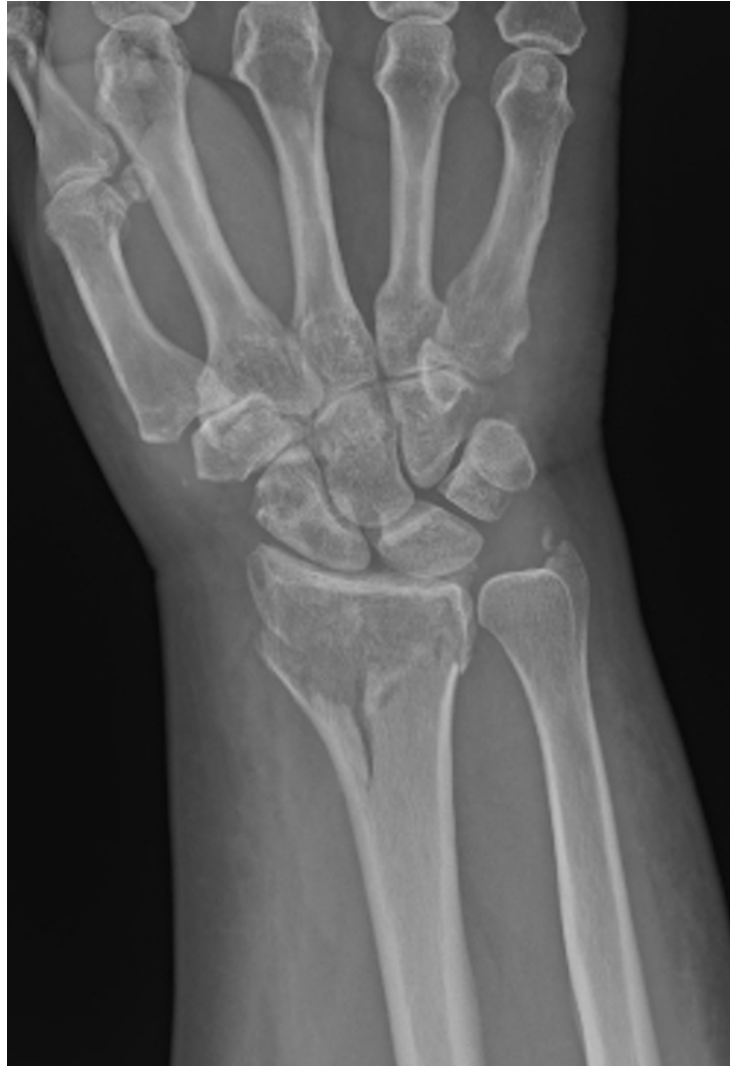13. Distal Biceps rupture 3



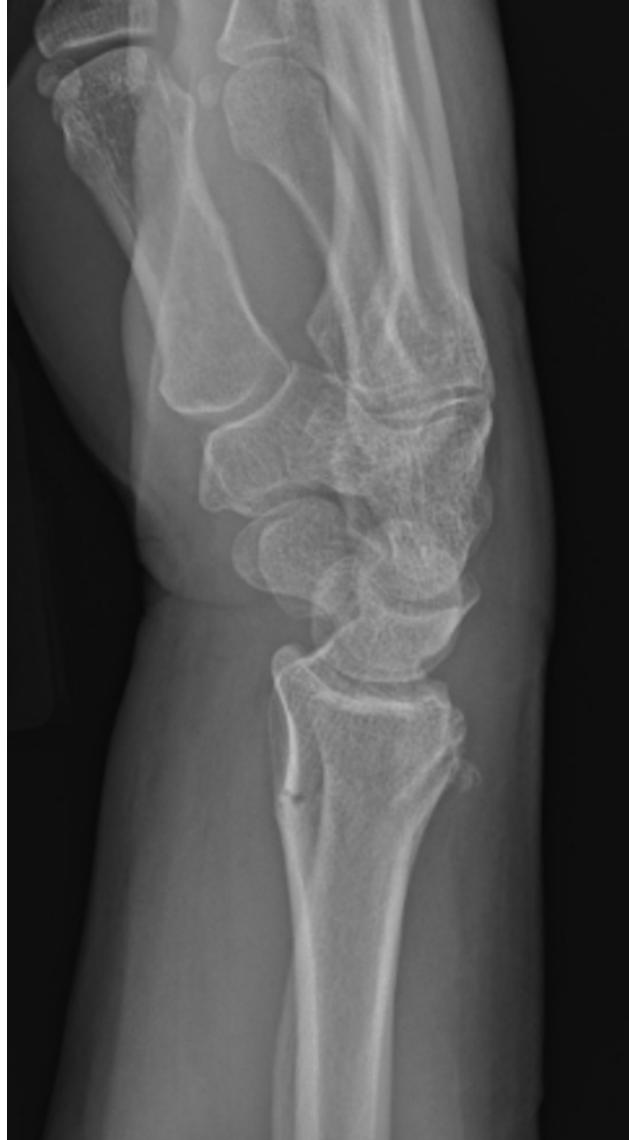14. Distal radius fracture 1



14. Distal radius fracture 2



15. Distal radius fracture 1



15. Distal radius fracture 2

