

Irish setter dogs affected with rod/cone dysplasia contain a nonsense mutation in the rod cGMP phosphodiesterase β -subunit gene

MICHAEL L. SUBER*[†], STEVEN J. PITTLER^{‡§}, NING QIN[¶], GAIL C. WRIGHT[‡], VIEN HOLCOMBE[†], REHWA H. LEE^{||}, CHERYL M. CRAFT^{**}, RICHARD N. LOLLEY^{||}, WOLFGANG BAEHR^{†¶††}, AND RICHARD L. HURWITZ^{†‡‡}

*College of Optometry, University of Houston, Houston, TX 77204; Departments of [‡]Ophthalmology, [¶]Biochemistry, [†]Pediatrics, and ^{‡‡}Cell Biology, Baylor College of Medicine, Houston, TX 77030; ^{||}Department of Anatomy and Cell Biology, University of California School of Medicine, Los Angeles, CA 90024, and Developmental Neurology Laboratories, Veterans Administration Medical Center, Sepulveda, CA 91343; and ^{**}Department of Psychiatry, University of Texas Southwest Medical Center, and Veterans Administration Medical Center, Dallas, TX 75235

Communicated by Richard L. Sidman, February 1, 1993 (received for review November 16, 1992)

ABSTRACT Irish setter dogs affected with a rod/cone dysplasia (locus designation, *rcdl*) display markedly elevated levels of retinal cGMP during postnatal development. The photoreceptor degeneration commences \approx 25 days after birth and culminates at about 1 year when the population of rods and cones is depleted. A histone-sensitive retinal cGMP phosphodiesterase (PDE; EC 3.1.4.35) activity, a marker for photoreceptor PDEs, was shown previously to be present in retinal homogenates of immature, affected Irish setters. Here we report that, as judged by HPLC separation, this activity originates exclusively from cone photoreceptors, whereas rod PDE activity is absent. An immunoreactive product the size of the PDE α subunit, but none the size of the β subunit, can be detected on immunoblots of retinal extracts of affected dogs, suggesting a null mutation in the PDE β -subunit gene. Using PCR amplification of Irish setter retinal cDNA, we determined the complete coding sequence of the PDE β subunit in heterozygous and affected animals. The affected PDE β -subunit mRNA contained a nonsense amber mutation at codon 807 (a G \rightarrow A transition converting TGG to TAG), which was confirmed to be present in putative exon 21 of the affected β -subunit gene. The premature stop codon truncates the β subunit by 49 residues, thus removing the C-terminal domain that is required for posttranslational processing and membrane association. These results suggest that the *rcdl* gene encodes the rod photoreceptor PDE β subunit and that a nonsense mutation in this gene is responsible for the production of a nonfunctional rod PDE and the photoreceptor degeneration in the *rcdl/rcdl* Irish setter dogs.

The Irish setter rod/cone dysplasia leading to a rapidly progressing loss of photoreceptors (1) is inherited as an autosomal recessive trait (genetic locus, *rcdl*). The early onset of the photoreceptor degeneration has been well defined by morphological and biochemical studies (2–4). Clinically, the disorder is grouped within a family of related canine retinal degenerations which are termed progressive retinal atrophies (5). In affected dogs, retina and photoreceptor development appears normal until 13 days of age (4), but subsequent development of rod photoreceptor cells is arrested. Rod photoreceptor degeneration is evident by 1 month of age; nearly all of the rod photoreceptors have degenerated by 5 months, and cone photoreceptor degeneration is completed by about 1 year (for review, see refs. 6 and 7).

The earliest known biochemical manifestation of the *rcdl* phenotype is a rapid accumulation of cGMP to levels that are

about 10-fold above those of age-matched controls (2–4, 8). These features are reminiscent of the phenotype seen in the *rd* mouse in which a nonsense mutation in exon 7 of the cGMP phosphodiesterase (PDE) β -subunit gene prevents the formation of a functional enzyme (9) leading to elevated cGMP levels and a rapid rod photoreceptor degeneration. Earlier studies of retinas from normal and affected Irish setters showed that the α and γ mRNAs of affected dog PDE were of normal size and abundance (10), whereas the β -subunit mRNA level appeared to be reduced (11, 12). This finding, similar to that in the *rd* mouse, suggests a defect in the dog PDE β -subunit gene. Since a previous study showed the presence of a histone sensitive cGMP PDE activity in affected, immature Irish setter retinas (13), we reinvestigated its origin by an HPLC method which is capable of separating rod and cone PDEs (14). In this paper we identify the residual PDE activity in affected Irish setter retinas as comigrating with cone PDE, whereas rod PDE activity is completely absent. We further provide evidence that a functional β subunit is not produced in affected retinas and that a nonsense mutation near the C-terminal end of the β -subunit gene leads to truncation and destabilization of the gene product, resulting in a nonfunctional rod PDE.^{§§}

METHODS

HPLC Analysis of Irish Setter Retinal Homogenates. Retinas of affected (*rcdl/rcdl*) and heterozygous Irish setters were obtained frozen from Federal Medical Resources (Honeybrook, PA). Retinas were homogenized in 10 mM Tris-HCl/1 mM EDTA/1 mM dithiothreitol/200 μ M phenylmethanesulfonyl fluoride, pH 7.5, in a Dounce homogenizer with a type B pestle. The homogenate was centrifuged at 15,000 \times g (Fisher microcentrifuge) for 10 min, and the supernatant was centrifuged twice at 100,000 \times g (Beckman Airfuge) for 10 min. The supernatant was then applied to a Mono Q (Pharmacia) HPLC column and eluted with the homogenizing buffer by using a 50–500 mM NaCl gradient at a flow rate of 0.5 ml/min. Fractions were collected every 30 sec. Aliquots of each indicated fraction were assayed for cGMP hydrolysis in the presence and absence of histone H3 (2 mg/ml; Sigma), with 10 μ M [³H]cGMP as substrate (14).

Western Blot Analysis. SDS/PAGE of retinal homogenates was performed in gels containing 15% acrylamide and 0.08%

Abbreviations: PDE, phosphodiesterase; RP, retinitis pigmentosa.
[§]Present address: Department of Biochemistry and Molecular Biology, University of South Alabama College of Medicine, Medical Sciences Building, Room 2158, Mobile, AL 36688-0002.

^{††}To whom reprint requests should be addressed.

^{§§}The sequence reported in this paper has been deposited in the GenBank data base (accession no. L13262).

The publication costs of this article were defrayed in part by page charge payment. This article must therefore be hereby marked "advertisement" in accordance with 18 U.S.C. §1734 solely to indicate this fact.

N,N'-methylenebisacrylamide (15), and proteins were transferred to nitrocellulose (16). The blot was incubated with polyclonal antibody MOE (1:1000 dilution) at 4°C overnight (17) and processed with the ECL Western blot detection system (Amersham). Horseradish peroxidase-conjugated goat anti-rabbit antibody (1:10⁵ dilution; Promega) was used as secondary antibody.

Isolation of mRNA and DNA. Poly(A)⁺ mRNA from retinas of seven heterozygous and seven affected Irish setters was isolated (9) by using a FastTrack kit (Invitrogen, San Diego). The RNA was precipitated twice with 1 M LiCl and 7 volumes of ethanol prior to reverse transcription. Genomic DNA was isolated from the livers of normal (+/+), heterozygous (+/-), and homozygous (-/-) Irish setters according to Hogan *et al.* (18). The liver and retina samples were from dogs separated by several generations. After electrophoresis in 1% agarose gel, amplified DNA was isolated by using GeneClean glass beads (Bio 101, La Jolla, CA).

PCR Amplification. Two micrograms of retinal poly(A)⁺ RNA was used as a template to synthesize cDNA in a volume of 25 μ l by reverse transcription (Promega kit), as described (9). Priming of the cDNA was performed with primer pairs as described in the text, and an anchoring primer as previously described (19). To determine sequence at the 5' end including the ATG initiation codon, the RACE (rapid amplification of cDNA ends) protocol of Frohman and Martin (20) as modified by Harvey and Darlison (21) was used. Poly(A)⁺ mRNA (2 μ g) was utilized as a template for reverse transcription primed with random hexamers. The resulting cDNA product was poly(A)-tailed at the 3' end by using dATP and terminal deoxynucleotidyltransferase (Promega), and amplification was carried out with a PDE specific primer (IS-4) and a modified oligo(dT) primer [T₁₆-mcs (19)]. One microliter of a 1:500 dilution was used for a second round of amplification with an internal PDE β subunit primer, IS-5, and the universal primer mcs23 (19). The predominant product, H1 (see Fig. 2), was gel purified and sequenced directly with the IS-5 primer. Genomic fragments comprising exon 21 and parts of exon 22 were amplified under standard PCR conditions including 10% (vol/vol) dimethyl sulfoxide, IS-2/IS-1 as primers, and +/+, +/-, and -/- genomic DNA as a template.

Oligonucleotide Primers and Direct Sequencing. The sequences and positions of primers which were used to amplify and sequence ISD PDE β subunit cDNA are shown in Fig. 3. The universal 3'-end primer mcs23 has been described (19). Direct sequencing was carried out with a Sequenase kit (United States Biochemical) according to the double-strand protocol (9). For short extensions (e.g., Fig. 4), reactions were carried out in the presence of Mn²⁺.

RESULTS

Affected Irish Setter Retinas Lack Rod Photoreceptor PDE Activity. Our earlier results showed that retinas of affected Irish setters contain a PDE activity that may be activated by histones, can be immunoprecipitated by a monoclonal antibody (ROS1) specific to rod and cone PDE, sediments with a sedimentation coefficient identical to that of normal PDE, but is significantly reduced in the amount of total activity (13). To unambiguously identify the nature and origin of the PDE in affected retinas, we subjected extracts from normal and affected retinas to HPLC capable of separating rod and cone PDEs (14). The animals were 34 days old when the retinas were obtained, an age when most of the rod photoreceptor cells are still present. Fig. 1A Lower shows the distribution of rod and cone PDEs in the normal (heterozygous) retina, indicating that about 90% of the total PDE activity originates from rods (fractions 48–55), and about 10% from cones (fractions 37–43). As shown in Fig. 1A Upper, the

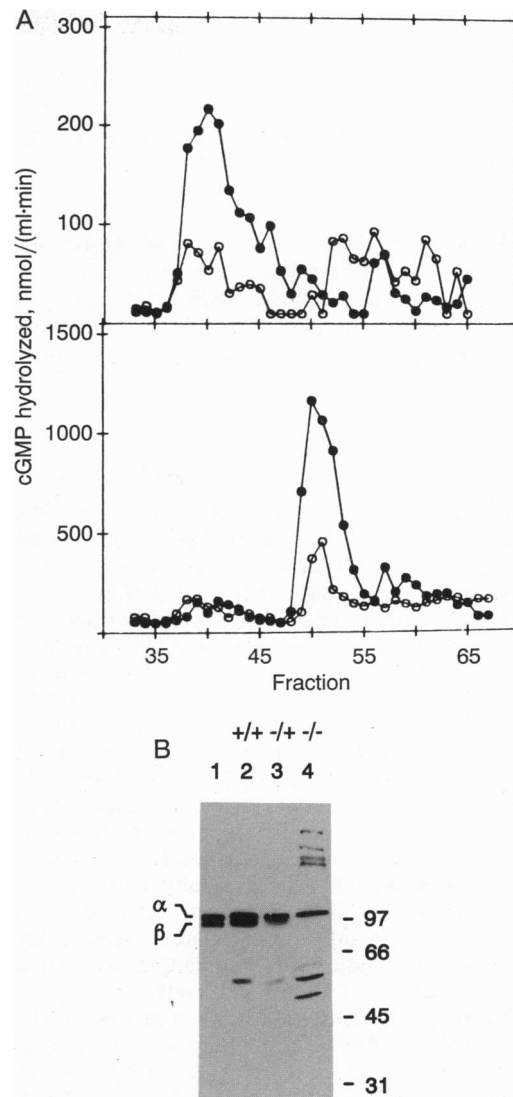


FIG. 1. (A) HPLC analysis of PDE from affected (homozygous *rcd1/rcd1*) (Upper) and normal (heterozygous) (Lower) Irish setter retinas. PDE activity was measured as basal activity (○) and after activation with histones (●). Fractions from each profile are aligned. Note the 5-fold difference in the scale of activity. (B) Western blot of retinal extracts of normal (lane 2), heterozygous (lane 3), and affected (lane 4) Irish setter retina extracts. Lane 1 contains a bovine retina homogenate for comparison. The two large subunits of rod PDE are marked with α and β . Sizes of polypeptide standards are indicated in kilodaltons at right.

affected Irish setter retina does not contain a histone-sensitive rod PDE. Virtually all of the measurable PDE activity in the affected retina is coeluted with cone PDE, consistent with the fact that in the initial phase of the degeneration, cones are unaffected.

Affected Retinas Do Not Contain Detectable Levels of Intact Rod PDE β Subunit. To identify the subunit distribution of normal and affected rod PDE, we subjected retinal extracts to SDS/PAGE followed by blotting and immunodetection of the subunits with a polyclonal, rod PDE-specific antibody (MOE; ref. 17). As shown in Fig. 1B, normal ISD retinas (lane 2) contain the two major subunits, α and β , characteristic of mammalian rod photoreceptor PDE. In the heterozygous sample, the amount of the PDE β subunit appears reduced to substoichiometric levels (lane 3). In the affected 34-day-old retinas, however, a polypeptide the size of the α subunit is present and the β subunit is absent (lane 4). Instead, polypeptides of lower (degradation of the β subunit?)

and higher (aggregation of α subunit in the absence of an intact β subunit?) apparent molecular mass are seen. These results suggest that a mutation in the β -subunit gene prevents the stable expression of an intact β subunit. Lack of a PDE β subunit and absence of a measurable rod PDE activity in the affected Irish setter retina is consistent with earlier results (9) suggesting that a stable β subunit is necessary for formation of a functional PDE holoenzyme.

Irish Setter PDE β -Subunit cDNA and Amino Acid Sequence. We amplified first-strand cDNA of a pool of seven retinas of heterozygous animals with a total of six primer pairs (Fig. 2). Sets of primers within the coding region were derived from a pool of primers used for amplification of the mouse PDE β subunit (9) or were synthesized according to sequences conserved in mammalian PDE β -subunit sequences. The complete 3' untranslated region was amplified by using a sequence-specific primer and a universal 3' end primer (19). A short (presumably incomplete) 5' untranslated region was determined by the RACE PCR method (20) in which the first-strand cDNA was first polyadenylated at the 3' end and then amplified. Thus, a nearly complete cDNA sequence for the normal Irish setter PDE β subunit, including the polyadenylation signal, a short poly(A) tract, the translation start codon ATG, and 16 nucleotides upstream of the ATG initiation codon could be assembled by direct sequencing of the resulting six amplified fragments (H1–H6; Fig. 2). The length of the sequenced cDNA [excluding the poly(A) tail] was 2746 nucleotides, in excellent agreement with the single 2.8-kb species found on Northern blots (12). The composite cDNA sequence (Fig. 3) predicts that the β subunit consists of 856 residues, exactly as found in other mammalian PDE β subunits. The amino acid sequence similarity to other mammalian PDE β subunits (Fig. 3) is very high (over 90%), and all features characteristic of photoreceptor PDEs [cGMP and γ -subunit binding sites, CAAX box signaling posttranslational geranylgeranylation (23), and homologous domain (24, 25)] are well conserved.

Identification of a Nonsense Mutation at Codon 807 of the Affected β -Subunit cDNA. To identify possible mutations in the affected retinas, four fragments (A1–A4; Fig. 2) covering the complete coding region of the β subunit of affected Irish setters were generated and sequenced. Comparison of the normal and mutated cDNA sequences revealed four nucleotide substitutions. Three substitutions did not change the amino acid sequence (T \rightarrow C at 267, G \rightarrow A at 606, T \rightarrow C at 609). The other substitution, a G \rightarrow A transversion in codon 807, led to generation of a nonsense codon (TGG \rightarrow TAG) 49 codons upstream of the normal translation termination codon (Fig. 3). The consequence of premature termination of translation in the affected β subunit appears to be an unstable

polypeptide, since it does not accumulate to a detectable level (Fig. 1B). Since the cDNA analysis was performed with amplified DNA derived from a pool of seven affected retinas, the β -subunit mRNAs of each Irish setter should carry the amber nonsense mutation. These results suggest that the genomes of the affected dogs carry the same allele.

Presence of the Mutant Allele in Genomic DNA of Affected Irish Setters. To confirm the presence of the nonsense mutation in the β -subunit gene (putative exon 21), genomic DNA from normal, heterozygous, and affected dogs was used as template for PCR amplification. The DNA samples originate from Irish setters separated by several generations from those used for RNA analysis. From each sample, a 1-kb fragment containing exon 21 and parts of exon 22 was amplified. The length of the fragment indicated that intron u, separating exons 21 and 22, is approximately the same size as in the mouse (9) and human (26) β -subunit gene. Direct sequencing with antisense primer W203, located 27 bp downstream of the nonsense mutation, shows the presence of a TGG codon in +/+ DNA and a TAG stop codon in -/- DNA. The heterozygous fragment possessing a normal and a mutant allele contains both the TGG and TAG codons (bracketed in Fig. 4). These results show that normal, heterozygous, and homozygous Irish setter genomes carry the expected alleles.

DISCUSSION

We previously reported in affected retinas the presence of a histone-sensitive PDE that was immunoreactive with an antibody (ROS1) prepared against rod cGMP PDE (13). We now show (Fig. 1A) that the identified PDE activity is that of cone photoreceptors, consistent with the ability of ROS1 to also recognize cone PDE (14), whereas the rod PDE is inactive or absent. Immunoblot analysis of affected retinal homogenates (Fig. 1B) does not demonstrate a PDE β subunit in homozygous *rcdl* retinas, strongly suggesting a null mutation in the β -subunit gene. This mutation was identified as a nonsense amber mutation at codon 807, providing a premature translational stop signal, which predicts truncation of the β subunit (Figs. 3 and 4). Assuming that the rod PDE β -subunit gene of Irish setter has an exon/intron arrangement that is identical to that of human and mouse, the nonsense codon would be located in exon 21 (of a total of 22). Since the total number of β -subunit codons is 856, the affected β subunit is truncated by 49 amino acid residues. SDS/PAGE (Fig. 1B) suggests that the truncated protein is labile, since it does not accumulate. The only domain known to be important in the last 49 residues is the C-terminal CAAX box sequence (23), which is a signal for posttranslational isopre-

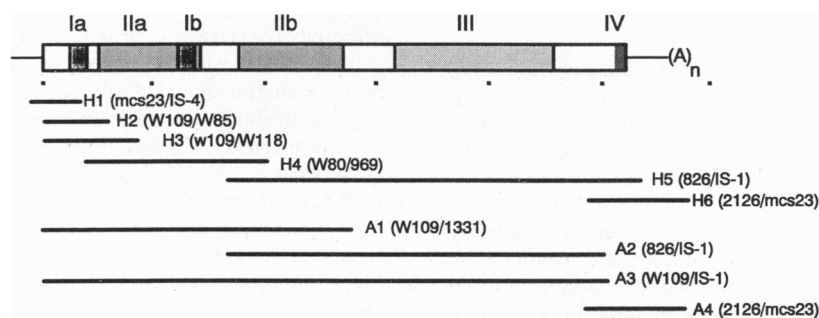


FIG. 2. Map of fragments amplified from heterozygous (H series) and affected (A series) cDNA. Bar represents the coding sequence of the PDE β subunit. The dark shaded areas Ia and Ib and the light shaded areas IIa and IIb constitute part of the putative binding sites for the γ subunit and cGMP, respectively. Area III depicts a domain that is conserved in other PDEs from yeast to human. The C-terminal domain IV contains a CAAX box sequence signaling posttranslational prenylation (17, 22), where C is cysteine, AA represents two aliphatic amino acid residues, and X is any amino acid. The tiny filled squares below the bar are positioned 500 nucleotides apart. The major amplified products used for direct sequencing are shown by bold lines. Fragments amplified from cDNA templates produced from heterozygous animals are labeled H1–H6, and those amplified from cDNA of affected dogs are A1–A4. Primers used for amplification are given in parentheses.




FIG. 3. cDNA sequence of the Irish setter PDE β subunit. The first base of the translation initiator ATG (boxed) is +1. The derived amino acid sequence is given in single-letter symbols. Lines above the DNA sequence denote the positions of primers used for amplification or DNA sequencing. Triangles pointing upstream or downstream indicate antisense or sense direction, respectively. The putative positions of introns t and u (9) 5' and 3' of exon 21 are marked (\blacktriangledown). Nucleotide substitutions in the affected β -subunit sequence are indicated above the DNA sequence. Codon 807 [TGG, tryptophan (W)], which is mutated to a stop codon (TAG) in the affected sequence, is shaded. The polyadenylation signal AATAAA in the 3' untranslated region is underlined. The CAAX sequence CCIL at the carboxyl terminus of the β subunit is also boxed. The extent of the homologous domain is indicated by a shaded bar below the amino acid sequence.

nylation of cysteine, proteolytic removal of the last three residues, AAX, and carboxyl methylation. The last residue, X, predetermines the nature of the prenyl residue to be linked to cysteine as a thioether. A leucine residue, as found in the Irish setter PDE β subunit (as well as mouse, human, and bovine), signals attachment of geranylgeranyl, a C₂₀ isoprenoid, which has been shown to serve as an anchor for rod outer-segment membrane association (17, 27, 28). The truncation of the Irish setter PDE β subunit thus would eliminate posttranslational geranylgeranylation and prevent membrane association of the β subunit (17) and possibly of the PDE holoenzyme (28). A defect in the enzyme responsible for geranylgeranylation of membrane associated small GTP-binding proteins (Rab) has been suggested to cause choroideremia (29), a disease of the large and heterogeneous retinitis pigmentosa (RP) group, indicating the biological relevance of this type of posttranslational prenylation.

The *rcdl* disorder is the second animal model identified with a defect in the PDE β -subunit gene. Pittler and Baehr (9) showed that in the *rd* mouse, a nonsense mutation at codon 347 eliminates more than half of the normal polypeptide, leading to an unstable truncated PDE β subunit and little or no measurable rod photoreceptor cGMP activity. Since

α and γ subunits are produced in both animal models, an association of α and β subunits appears to be essential for assembly of a functional PDE. In the *rd* mouse, the resulting accumulation of cGMP is evident as the photoreceptor degeneration ensues rapidly, with all rod photoreceptors having disappeared by about 20 days after birth. The rapid onset of photoreceptor cell degeneration in the *rd* mouse is juxtaposed with a slower rate of photoreceptor degeneration in *rcdl* Irish setters, where the degeneration begins at about 1 month and ensues over an additional 3 months. During the course of the pathology, the level of cGMP rises several-fold higher in the *rcdl* retina than it does during the brief period of degeneration in the *rd* mouse. Thus, the phenotype of the *rd* mouse and *rcdl* disorders appear different both in terms of the level of cGMP accumulation and in the time course of the degenerative process. However, the defective genes of the *rd* mouse and *rcdl* disorders are similar in that they both contain premature stop codons, which truncate the rod PDE β subunit. In both disorders, the mRNA levels are significantly reduced, and the truncated gene products are unstable, consistent with the effect of numerous premature stop codons in other systems (9). Further study of both animal models will be very useful in determining how elevated levels of cGMP

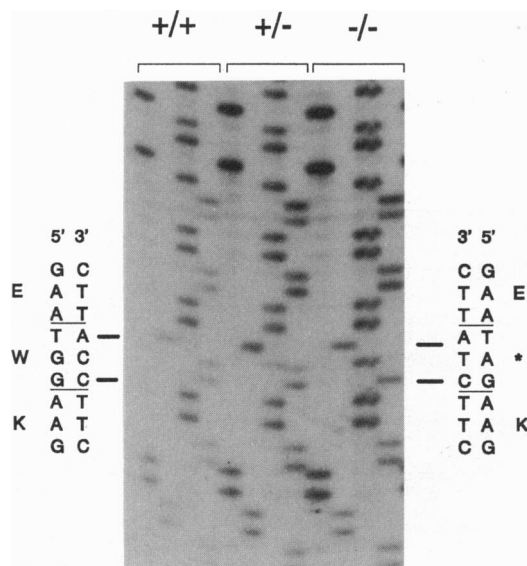


FIG. 4. DNA sequence of a 27-nucleotide window of putative exon 21 of the Irish setter PDE β -subunit gene. Genomic DNA of normal (+/+), heterozygous (+/-), and affected (-/-) dogs was amplified with primers IS-1 and IS-2 and sequenced with antisense primer W203. The locations of the normal (TGG, tryptophan) and mutated (TAG, stop) codons are bracketed. The lane order is G, A, T, C.

initiate the process of degeneration and how rod photoreceptor cell death triggers the degeneration of what appear to be healthy cones.

Animals with inherited photoreceptor degeneration and blindness have been identified and bred for their potential usefulness in understanding the types and causes of RP, the most common group of inherited, blinding diseases in humans (30). The hypothesis that specializations of rod and cone photoreceptors make them vulnerable to inherited and acquired disease has been widely proclaimed, and evidence to support this contention is now available. The photoreceptor specialization that is most relevant to this discussion is that of the phototransduction cascade, which links rhodopsin via transducin to PDE activation and subsequent channel closure. In autosomal dominant RP, over 40 separate mutations have been identified in the opsin gene (31–33) and at least 3 in a putative structural protein, rds/peripherin (34, 35), that appears to be essential for the formation of rod outer segments. The mutations in the opsin gene may account for 25% or more of the different forms of autosomal dominant RP. Another mutation in the rhodopsin gene appears to segregate as an autosomal recessive characteristic (36). No human or animal disorders of inherited retinal degeneration have been directly or indirectly linked to genes encoding the three subunits of transducin, the cation channel, or any of the known regulatory proteins [e.g., rhodopsin kinase, rhodopsin phosphatase (2A), S-antigen, phosducin, recoverin, guanylate cyclase, pyrophosphatase]. Because of the overall frequency of the various types of RP, it is important to identify mutations that cause autosomal recessive RP, the most prevalent form of RP. A human donor eye with RP of autosomal dominant inheritance has been evaluated that reportedly showed elevated levels of cGMP and low levels of cGMP PDE (37), suggesting that some forms of RP may be caused by errors in the processing of cGMP PDE or in individual components of the PDE complex. Genetic defects in the PDE β subunit family may unfold with a diversity that

is comparable to that now being revealed for the rhodopsin mutations in autosomal dominant RP.

M.L.S. and S.J.P. contributed equally to this paper. This research was funded by grants from the National Eye Institute (EY08123, EY00395, and EY06656), the National Retinitis Pigmentosa Foundation, the Gund Foundation, the RP Foundation Fighting Blindness (Baltimore), the Knights Templar Eye Foundation (Indianapolis), the Retina Research Foundation (Houston), the Ella G. McFadden Foundation, a National Institute of Neurological Disorders and Stroke grant (1R29N528126), and a Merit Review from the Veterans Affairs Research Service. W.B. is the recipient of a Jules and Doris Stein Research to Prevent Blindness Professorship.

1. Parry, H. B. (1953) *Br. J. Ophthalmol.* **37**, 487–502.
2. Liu, Y. P., Krishna, G., Aguirre, G. & Chader, G. J. (1979) *Nature (London)* **280**, 62–64.
3. Aguirre, G., Farber, D. B., Lolley, R. N., Fletcher, R. T. & Chader, G. J. (1978) *Science* **201**, 1133–1134.
4. Aguirre, G., Farber, D., Lolley, R., O'Brien, P. O., Alligood, J., Fletcher, R. T. & Chader, G. (1982) *Exp. Eye Res.* **35**, 625–642.
5. Aguirre, G. (1978) *Exp. Eye Res.* **26**, 233–253.
6. Schmidt, S. Y. (1985) in *Handbook of Neurochemistry*, ed. Lejthe, A. (Plenum, New York), pp. 461–507.
7. Voaden, M. J. (1990) *Progr. Retinal Res.* **10**, 293–331.
8. Chader, G. J., Fletcher, R. T., Sanyal, S. & Aguirre, G. D. (1985) *Curr. Eye Res.* **4**, 811–819.
9. Pittler, S. J. & Baehr, W. (1991) *Proc. Natl. Acad. Sci. USA* **88**, 8322–8326.
10. Pittler, S. J., Lee, R. H., Lolley, R. N., Hurwitz, R. L. & Baehr, W. (1990) *Invest. Ophthalmol. Vis. Sci.* **31**, 311.
11. Farber, D. B., Danciger, J. S. & Aguirre, G. (1990) *Invest. Ophthalmol. Vis. Sci.* **31**, 310.
12. Farber, D. B., Danciger, J. S. & Aguirre, G. (1992) *Neuron* **9**, 349–356.
13. Lee, R. H., Lieberman, B. S., Hurwitz, R. L. & Lolley, R. N. (1985) *Invest. Ophthalmol. Vis. Sci.* **26**, 1569–1579.
14. Hurwitz, R. L., Bunt-Milam, A. H., Chang, M. L. & Beavo, J. A. (1985) *J. Biol. Chem.* **260**, 568–573.
15. Baehr, W., Devlin, M. J. & Applebury, M. L. (1979) *J. Biol. Chem.* **254**, 11669–11677.
16. Towbin, H., Staehelin, T. & Gordon, J. (1979) *Proc. Natl. Acad. Sci. USA* **76**, 4350–4354.
17. Qin, N., Pittler, S. J. & Baehr, W. (1992) *J. Biol. Chem.* **267**, 8458–8463.
18. Hogan, B. L. M., Constantini, F. & Lacy, E. (1986) *Manipulation of the Mouse Embryo: A Laboratory Manual* (Cold Spring Harbor Lab., Plainview, NY).
19. Al-Ubaidi, M. R., Pittler, S. J., Champagne, M. S., Triantafyllos, J. T., McGinnis, J. F. & Baehr, W. (1990) *J. Biol. Chem.* **265**, 20563–20569.
20. Frohman, M. A. & Martin, G. R. (1989) *Technique* **1**, 165–170.
21. Harvey, R. J. & Darlison, M. G. (1991) *Nucleic Acids Res.* **19**, 4002.
22. Anant, J. S., Ong, O. C., Xie, H., Clarke, S., O'Brien, P. J. & Fung, B. K.-K. (1992) *J. Biol. Chem.* **267**, 687–690.
23. Maltese, W. A. (1990) *FASEB J.* **4**, 3319–3328.
24. Beavo, J. A. (1988) *Adv. Second Messenger Phosphoprotein Res.* **22**, 1–38.
25. Pittler, S. J. & Baehr, W. (1991) *Prog. Clin. Biol. Res.* **362**, 33–66.
26. Weber, B., Riess, O., Hutchinson, G., Collins, C., Lin, B., Kowbel, D., Andrew, S., Schappert, K. & Hayden, M. R. (1991) *Nucleic Acids Res.* **19**, 6263–6268.
27. Anant, J. S. & Fung, B. K.-K. (1992) *Biochem. Biophys. Res. Commun.* **183**, 468–473.
28. Catty, P. & Deterre, P. (1991) *Eur. J. Biochem.* **199**, 263–269.
29. Seabra, M. C., Brown, M. S., Slaughter, C. A., Südhof, T. C. & Goldstein, J. L. (1992) *Cell* **70**, 1049–1057.
30. Heckenlively, J. R. (1988) *Retinitis pigmentosa* (Lippincott, Philadelphia).
31. Inglehearn, C. F., Bashir, R., Lester, D. H., Jay, M., Bird, A. C. & Bhattacharya, S. S. (1991) *Am. J. Hum. Genet.* **48**, 26–30.
32. Sung, C.-H., Davenport, C. M., Hennessey, J. C., Maumenee, I. H., Jacobson, S. G., Heckenlively, J. R., Nowakowski, R., Fishman, G., Gouras, P. & Nathans, J. (1991) *Proc. Natl. Acad. Sci. USA* **88**, 6481–6485.
33. Dryja, T. P., Hahn, L. B., Cowley, G. S., McGee, T. L. & Berson, E. L. (1991) *Proc. Natl. Acad. Sci. USA* **88**, 9370–9374.
34. Farrar, G. J., Kenna, P., Jordan, S. A., Kumar-Singh, R., Humphries, M. M., Sharp, E. M., Sheils, D. M. & Humphries, P. (1991) *Nature (London)* **354**, 478–480.
35. Kajiwara, K., Hahn, L. B., Mukai, S., Travis, G. H., Berson, E. L. & Dryja, T. P. (1991) *Nature (London)* **354**, 480–483.
36. Rosenfeld, P. J., Cowley, G. S., McGee, T. M., Sandberg, M. A., Berson, E. L. & Dryja, T. P. (1992) *Nature Genet.* **1**, 209–213.
37. Farber, D. B., Flannery, J. G., Bird, A. C., Shuster, T. & Bok, D. (1987) in *Degenerative Retinal Disorders: Clinical and Laboratory Investigations*, ed. Hollyfield, F. G. (Liss, New York), pp. 53–67.