

# Expandable Wallstent for the treatment of obstruction of the superior vena cava

A F Watkinson, D M Hansell

## Abstract

**Background**—Palliative treatments for obstruction of the superior vena cava all have disadvantages. The use of a fine braided wire self expanding stent (Wallstent, Schneider (Europe) AG) in patients with malignant and benign causes of superior vena cava obstruction is reported.

**Methods**—Five patients with obstruction of the superior vena cava were treated with balloon angioplasty of the stricture and the percutaneous insertion of an expandable Wallstent endoprosthesis across the site of the stricture. Four patients had advanced mediastinal malignancy previously treated by radiotherapy and one patient had fibrosing mediastinitis.

**Results**—All patients experienced rapid symptomatic relief and, in three cases, complete palliation was achieved during survival times of seven weeks, nine weeks, and 24 weeks, respectively. Two surviving patients (with a recurrent thymoma and fibrosing mediastinitis) were free of symptoms when followed up at eight and nine months respectively.

**Conclusions**—Initial experience with the Wallstent endoprosthesis suggests that it is a valuable treatment alternative once conventional therapy has failed and gives rapid relief of symptoms to patients with obstruction of the superior vena cava.

(Thorax 1993;48:915-920)

Obstruction of the superior vena cava is a distressing condition characterised by considerable facial and arm swelling, shortness of breath, and intractable headaches; these latter two symptoms are often aggravated by certain postures such as stooping or lying flat. It is a frequent accompaniment to advanced mediastinal malignancy and traditional treatment relies on radiotherapy, chemotherapy, or surgery.<sup>1-4</sup> Radiotherapy and chemotherapy for malignant causes of obstruction of the superior vena cava may produce an initial improvement, but symptoms often recur with subsequent resistance to further treatment. Surgical management is associated with high morbidity and mortality in patients with an already short life expectancy. Percutaneous intravenous stent placement for the treatment

of obstruction of the superior vena cava has previously been reported with the Gianturco stent<sup>5-9</sup> and the Palmaz stent.<sup>10</sup> The self expanding metallic Wallstent has been used in arterial and hepatobiliary work<sup>11,12</sup> and in two cases of malignant obstruction of the superior vena cava.<sup>13</sup> We present our initial experience with the Wallstent in five patients with the condition: four due to malignancy and one due to fibrosing mediastinitis.

## Method

Approval from the hospital ethics committee was obtained and informed consent was given by each patient.

All patients had a digital subtraction superior vena cavogram (fig 1A) via a right femoral vein approach to: (1) exclude intraluminal thrombus or tumour, (2) confirm the length and severity of the stricture, and (3) identify the site of obstruction with respect to the right atrium and confluence of brachiocephalic veins. A 7 Fr straight flush catheter and a 0.038 inch diameter guidewire introduced through a 9 Fr introducer sheath (Cordis Corporation, Miami, Florida) were used to traverse the stricture. Balloon angioplasty of the stricture was then performed (fig 1B). The diameter of the balloon varied from 10 to 14 mm (Olbert, Meadox Surgimed A/S Stenlose, Denmark or Meditech, Watertown, South Africa) and a variable degree of dilatation was achieved (ranging from 50% to 100% of the fully inflated balloon diameter). A preloaded (9 Fr) Wallstent endoprosthesis (approximate cost £600) of appropriate length (44-77 mm) and expanded diameter (14-16 mm) was then positioned across the stricture and released from its restraining sheath (fig 1C). As the Wallstent expands from its sheath there is a corresponding reduction in length of 20-40%. Careful evaluation with fluoroscopy is required to ensure that the centre of the stent lies across the area of maximum stenosis. After placement a further cavogram was performed to confirm patency and free flow into the right atrium and pulmonary circulation (fig 1D). All patients were anticoagulated with intravenous heparin (24 000 units/24 hours) for 72 hours and received 75 mg aspirin daily thereafter. A chest radiograph was taken after the procedure to show the position and state of expansion of the stent to assist in follow up (fig 1E).

Department of  
Radiology, Royal  
Brompton National  
Heart and Lung  
Hospital, London  
SW3 6NP

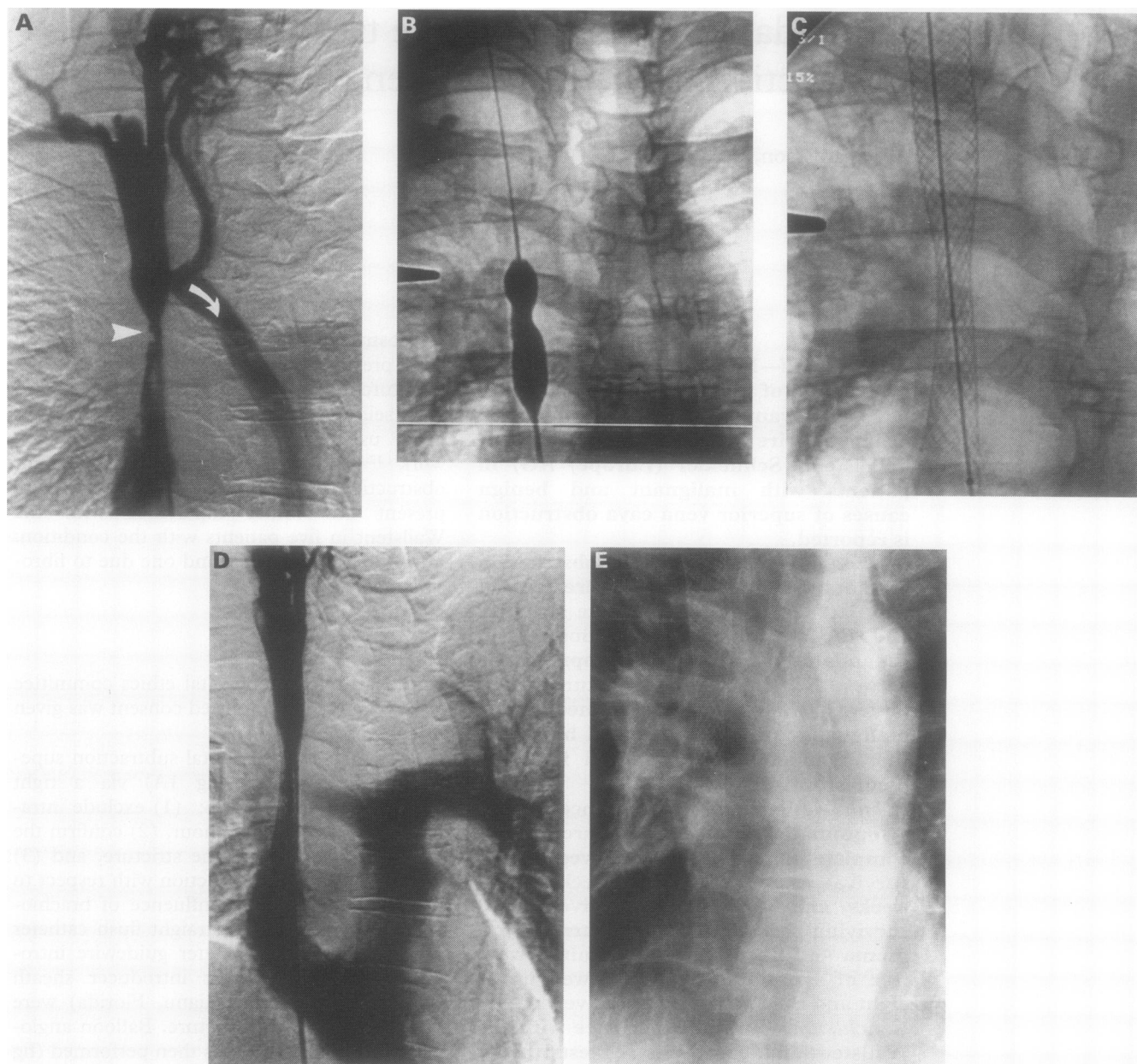
A F Watkinson  
D M Hansell

Reprint requests to:  
Dr D M Hansell

Received 8 February 1993  
Returned to authors  
20 April 1993

Revised version received  
19 May 1993

Accepted 27 May 1993



*Figure 1 Case 3. (A) Digital subtraction superior vena cavogram showing low stricture in superior vena cava (arrowhead) with collateral venous drainage in the superior mediastinum and retrograde flow into the azygos vein (arrow). (B) Balloon angioplasty of the stricture in the superior vena cava. (C) Wallstent in place across the stricture (14 mm diameter fully expanded, 8 mm at the "waist"), magnified view. (D) Cavogram performed after the procedure showing free flow through the superior vena cava into the pulmonary circulation. (E) One month after insertion of the stent a further slight expansion of the waist can be seen.*

### Case histories

#### CASE 1

A 61 year old woman presented in October 1989 with cough, haemoptysis, and a chest infection which was slow to resolve. Bronchoscopy and biopsy confirmed a non-small cell lung carcinoma in the right upper lobe; this was deemed inoperable and the patient received 30 Gy radiotherapy in 10 fractions. The patient represented two years later with weight loss, cough, increasing shortness of breath, and upper torso swelling of two months' duration. Further radiotherapy (26 Gy in 10 fractions) resulted in little improvement of these symptoms. On cavography a stricture, 4 mm long and 2 mm in diameter, was identified in the mid superior vena cava with extensive venous collaterals. Angioplasty was performed using a Meditech balloon, 3 cm long and 12 mm in diameter.

This achieved 60% dilatation of the stricture before the balloon burst. A Wallstent, 44 mm long and 14 mm in diameter, was positioned across the stricture. There were no complications following the procedure and symptomatic relief was achieved over the next 48 hours. The stent remained patent with no recurrence of symptoms of obstruction of the superior vena cava until the patient died from cerebral metastases seven weeks later.

#### CASE 2

A 43 year old woman presented in 1988 with an anterior mediastinal mass discovered on a routine chest radiograph. This was subsequently diagnosed as an inoperable thymoma and the patient received 60 Gy radiotherapy in 30 fractions with some reduction in the size of the mass. The patient remained asymptomatic until January 1992 when she

developed swelling of the arms and face and increasing shortness of breath. Obstruction of the superior vena cava was diagnosed and a stricture, 1 cm long and 2 mm in diameter, in the mid superior vena cava was confirmed on cavography. Following angioplasty with an Olbert balloon, 10 mm in diameter, 100% dilatation was achieved and a Wallstent, 50 mm long and 16 mm in diameter, was positioned across the fully dilated stricture. There was immediate symptomatic relief and on follow up 25 days later the patient was asymptomatic apart from slight puffiness of the fingers. A repeat cavogram was performed three months after the procedure because the patient had developed non-specific symptoms of upper chest discomfort; the Wallstent was shown to be patent and there was no haemodynamic impairment of venous return. The patient remains free from symptoms of obstruction of the superior vena cava eight months after insertion of the Wallstent.

#### CASE 3

A 67 year old man presented in November 1990 with right sided pleuritic chest pain, weight loss, cough, and haemoptysis. Subsequent investigation showed a small cell carcinoma in the anterior segment of the right upper lobe of his lung. He received radiotherapy (17.5 Gy in two fractions) with symptomatic improvement. He remained well until July 1991 when he presented with severe headache, facial and neck swelling, and increasing shortness of breath. Cavography confirmed a stricture, 1.5 cm long and 3 mm in diameter, in the lower third of the superior vena cava (fig 1A). Following angioplasty with a Meditech balloon, 4 cm long and 15

mm in diameter, 60% dilatation was achieved (fig 1B) and a Wallstent, 77 mm long and 14 mm in diameter, was positioned across the stricture (fig 1C). A good haemodynamic result was achieved with rapid flow through the superior vena cava into the pulmonary circulation (fig 1D). The patient had immediate and total symptomatic relief. A chest radiograph performed after the procedure confirmed the position of the stent, and another chest radiograph one month later showed some further expansion of the stent at the site of the stricture (fig 1E). The patient remained well until November 1991 when he was readmitted with haematemesis due to gastric erosions. He died 24 weeks after stenting with no recurrence of symptoms of obstruction of the superior vena cava.

#### CASE 4

A 46 year old woman presented in October 1991 with headaches, right sided chest pain, and arm and facial swelling. Investigations revealed a right upper lobe small cell carcinoma with extensive bony metastases. The patient received radiotherapy (20 Gy in five fractions) to the primary tumour and to bony metastases in the cervical spine (8 Gy in a single fraction) with good response. She remained well until May 1992 when symptoms of obstruction of the superior vena cava returned and a cavogram revealed a stricture, 2 cm long and 3 mm in diameter, in the lower superior vena cava with retrograde flow down the azygos vein. A Wallstent, 77 mm long and 14 mm in diameter, was positioned across the stricture (fig 2A) and balloon angioplasty with an Olbert catheter, 4 cm long and 14 mm in diameter, was performed

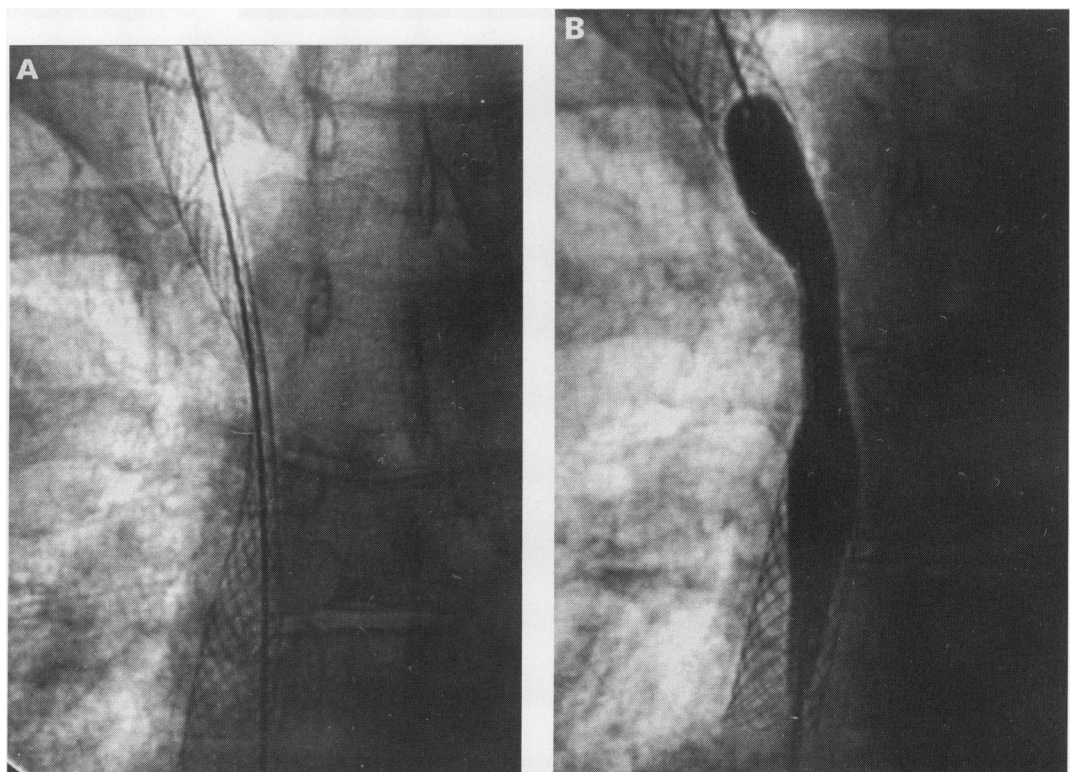


Figure 2 Case 4. (A) Wallstent in place before adequate dilatation had been achieved. (B) Balloon angioplasty from within the stent.

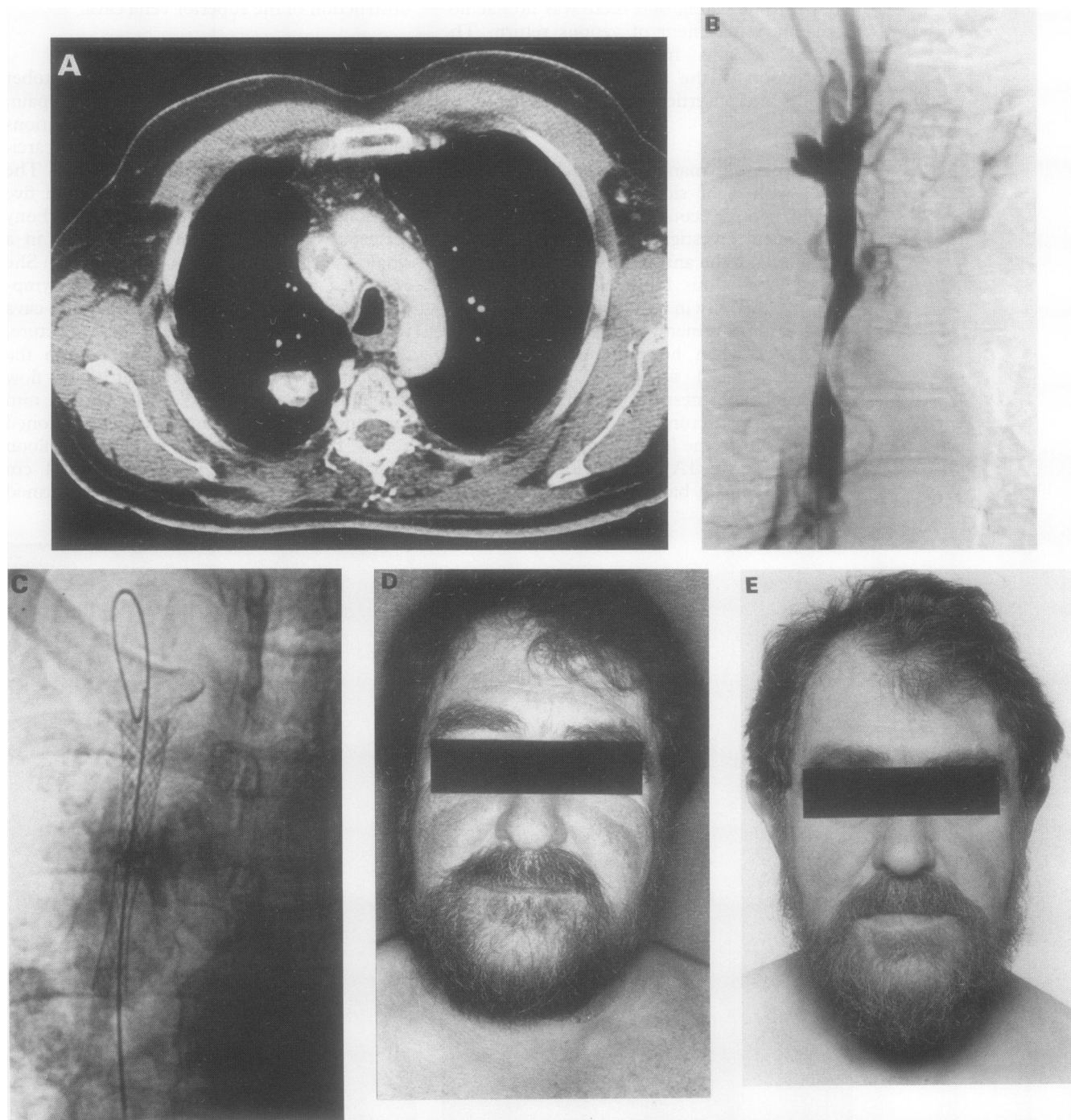


from within the stent (fig 2B). This was extremely difficult and the patient experienced pain during expansion of the balloon; only 50% dilatation was achieved. A cavogram performed after the procedure confirmed patency of the superior vena cava and good flow into the pulmonary circulation. The patient experienced rapid relief of her symptoms and after 72 hours all arm and facial oedema had resolved. The patient died nine weeks later without recurrence of symptoms of superior vena cava obstruction.

#### CASE 5

A 55 year old man was thought to have malignant mediastinal disease at presentation

in 1979 and received radiotherapy. Surgical biopsy at that time did not confirm malignancy and the diagnosis was subsequently revised to fibrosing mediastinitis secondary to granulomatous disease, probably tuberculosis. He had symptoms of obstruction of the superior vena cava for the five years before presenting in May 1992, but these had become significantly worse in the preceding six months. A computed tomographic scan at this time showed extensive upper lobe fibrosis and calcific foci as well as heavily calcified enlarged lymph nodes in the superior mediastinum (fig 3A). Cavography demonstrated a stricture in the mid superior vena cava (fig 3B). Balloon angioplasty with an Olbert catheter, 4 cm long



**Figure 3** Case 5 (A) Computed tomographic scan of the upper thorax with intravenous contrast enhancement showing heavily calcified mass in the vicinity of the superior vena cava (and in the right upper lobe), and venous collaterals in the paravertebral regions and anterior mediastinum. (B) Smooth extrinsic compression of the mid superior vena cava at the level of the lymph node mass. (C) Wallstent in place after balloon angioplasty. (D) Facial plethora and periorbital oedema which had been present for five years before stenting. (E) Eight months after insertion of the Wallstent.

and 12 mm in diameter, and placement of a Wallstent, 55 mm long and 14 mm in diameter were performed (fig 3C). During fluoroscopy a small volume of contrast was noted in the pericardial sac, presumably due to inadvertent puncture of the right atrium by the guidewire or catheter during negotiation of the stricture. There were no adverse consequences: the patient remained in sinus rhythm throughout the procedure and no pericardial effusion developed subsequently. There was relief of the symptoms of obstruction of the superior vena cava over the next three days and these continued to resolve over the next few weeks. The patient reported that he was able to stoop down for the first time in years and his facial plethora resolved steadily over the succeeding eight months (figs 3D and 3E).

Correct positioning of the Wallstent prosthesis was achieved in all patients with rapid relief of most symptoms of superior vena cava obstruction within 72 hours. There were no late complications attributable to stent placement. One patient experienced discomfort during inflation of the angioplasty balloon; this settled quickly on deflation. The three patients (cases 1, 4 and 3) who died seven weeks, nine weeks, and 24 weeks respectively after insertion of the Wallstent had complete palliation of their symptoms until the time of their death. The two surviving patients with a thymoma (case 2) and fibrosing mediastinitis (case 5) had no recurrence of the obstruction at eight and nine months respectively.

### Discussion

Radiotherapy or chemotherapy are the initial treatments of choice for obstruction of the superior vena cava resulting from malignant disease; in recurrent disease, however, they are often unsuccessful. Surgery for this condition has been shown to have several disadvantages. Previous workers have tried balloon angioplasty alone for the palliation of both benign and malignant obstruction. One patient with benign obstruction secondary to transvenous cardiac pacemaker insertion remained asymptomatic for 15 months.<sup>14</sup> In another report a patient with obstruction of the superior vena cava due to metastatic adenocarcinoma initially benefited from angioplasty; the patient underwent open mediastinal exploration one day later to confirm the histological diagnosis and at the same time the superior vena cava was patched with a vein graft.<sup>15</sup> It is unlikely that angioplasty alone will provide long term palliation in patients with obstruction of the superior vena cava.

The results of treatment of obstruction of the superior vena cava with self expanding metallic stents have been more favourable, both with the expandable Gianturco stent<sup>5-9</sup> and with the balloon expandable Palmaz stent.<sup>10</sup> The successful palliation of obstruction with the Gianturco stent has been reported in six cases of restenosis of malignant obstruction of the superior vena cava

following maximum tolerance radiotherapy.<sup>5</sup> In two of these obstruction was associated with massive thrombosis which was successfully treated by fibrinolysis before stent placement. A larger multicentre study<sup>8</sup> documented successful palliation in 17 patients with malignant obstruction of the superior vena cava, with most of the patients having metastatic carcinoma of the lung and surviving between a few days and several months. There were two long term survivors (thymoma 26 months, lymphoma 18 months). The only complication after stent insertion in this group of patients was a transient phrenic nerve palsy in a patient with bronchial carcinoma treated by radiotherapy. The postulated cause for this was compression of the phrenic nerve against surrounding tumour and radiation fibrosis during balloon angioplasty, rather than damage from the stent.

Quinn *et al*<sup>9</sup> reported the use of the Gianturco stent in four patients with obstruction of the superior vena cava with a 50% occlusion rate three months later. The early occlusion rate is attributed to the rigidity of the Gianturco stent and its use at major venous confluences and areas of vascular curvature.

Solomon *et al*<sup>10</sup> reported a series of six patients with obstruction of the superior vena cava, one of whom was treated with a Gianturco self expanding stent and five with a Palmaz balloon expandable stent. There was complete resolution of symptoms (within one to three days) in five cases, with partial improvement in the remaining patient who had persistent oedema of the head and neck. Two cases had recurrence of symptoms at a later date, however; one had rethrombosis treated by percutaneous thrombectomy and angioplasty on two occasions (at six and 10 weeks), and the other developed a further stenosis secondary to tumour progression just distal to the stent which was successfully treated by angioplasty. As the balloon expandable Palmaz stent does not have any intrinsic radial expansile force, unlike the Gianturco stent or Wallstent, the maximum achievable diameter of the lumen will be seen immediately after angioplasty.

The self expanding Wallstent metallic prosthesis already has an established role in the treatment of malignant obstruction of the biliary tree<sup>12</sup> and in peripheral and coronary arteries resistant to angioplasty.<sup>11</sup> The success of the Wallstent in these applications has led to its increasing use in other clinical areas, such as in obstruction of the urinary tract<sup>16</sup> and the superior vena cava.<sup>13</sup> In the series reported by Antonucci *et al*<sup>13</sup> two patients with bronchial carcinoma were treated for obstruction of the superior vena cava. In one patient the stent remained patent until death six weeks later, but in the other patient the stent occluded after three days. This was successfully recanalised with thrombolysis and angioplasty but occluded again after eight weeks. In our series immediate relief of symptoms in all five patients was achieved with no

evidence of early or late thrombosis or stent occlusion. In four of the five cases we performed angioplasty before the placement of the stent, and we regard this as an important part of the procedure even when full dilatation is not achieved. In three cases no premedication was given, but one patient (case 4) experienced discomfort on inflation of the angioplasty balloon which resolved when the balloon was deflated. As a result we now routinely prescribe premedication of 2.5 mg midazolam orally before the procedure. A definite contraindication to stent placement within the superior vena cava is the presence of intraluminal tumour or thrombus. Neither was encountered in our patients but, if thrombus is found, fibrinolytic therapy has been advocated before stent placement.<sup>8,9,13</sup> Short term anticoagulation and long term aspirin were used to prevent thrombosis and stent occlusion on the basis of experimental studies.<sup>17</sup> On follow up chest radiography there was static or continued expansion of the diameter of the Wallstent. Stent migration was not seen in any patient.

The role of Wallstents in non-malignant obstruction has not been clearly defined. Irving *et al*<sup>8</sup> treated four benign venous strictures with Gianturco stents, including one patient with obstruction of the superior vena cava secondary to mediastinal fibrosis following trauma. There was a good initial response following angioplasty alone. The obstruction recurred and a Gianturco stent was placed across the stricture. Total thrombosis of the superior vena cava occurred after only two months and the patient subsequently had a surgical bypass which remained patent for three years. In our series the rapid relief of symptoms and patency at nine months suggests that the Wallstent may have a role in benign obstruction of the superior vena cava. Our initial experience supports the use of the metallic Wallstent in cases of recurrent malignant obstruction of the superior vena cava after palliative radiotherapy or chemotherapy. Longer term follow up of patients with obstruction of non-malignant aetiology treated with intravenous stents is needed.

We would like to thank Dr J D Irving for technical help and Dr S G Spiro and Dr T W Evans for allowing us to present their patients.

- 1 Lokich JJ, Goodman R. Superior vena caval syndrome. Clinical management. *JAMA* 1975;231:58-61.
- 2 Perez CA, Presant CA, van Amburg IAL. Management of superior vena caval obstruction. *Semin Oncol* 1978;5: 123-34.
- 3 Stanford W, Doty D. The role of venography and surgery in the management of patients with superior vena cava obstruction. *Ann Thorac Surg* 1986;41:158-63.
- 4 Hoak B, Chapman J, Tiley E, Boland J. Quick and easy management of superior vena caval syndrome. *Ann Surg* 1989;52:622-3.
- 5 Charnsangavej C, Carrasco CH, Wallace S, Wright K, Ogawa K, Richli W, *et al*. Stenosis of the vena cava: preliminary assessment of treatment with expandable\* metallic stents. *Radiology* 1986;161:295-8.
- 6 Rösch J, Bedell JS, Putnam J, Antonivic R, Uchida B. Gianturco expandable wire stents in the treatment of superior vena cava syndrome recurring after maximum tolerance radiation. *Cancer* 1987;60:1243-6.
- 7 Putnam JS, Uchida BT, Antonivic R, Rösch J. Superior vena cava syndrome associated with massive thrombosis: treatment with expandable stents. *Radiology* 1988;167:727-8.
- 8 Irving JD, Kurdziel JC, Reidy JF, Schild H, Dick R, Adam A, *et al*. The Gianturco self-expanding stent: clinical experience in the vena cava and large veins. *Cardiovasc Intervent Radiol* 1992;15:328-33.
- 9 Quinn SF, Schuman ES, Lee Hall MC, Gross GF, Uchida BT, Standage BA, *et al*. Venous stenoses in patients who undergo hemodialysis: treatment with self-expandable endovascular stents. *Radiology* 1992;183: 499-504.
- 10 Solomon N, Holey MH, Jarmolowski CR. Intravascular stents in the management of superior vena cava syndrome. *Cath Cardiovasc Diagn* 1991;23:245-52.
- 11 Sigwart U, Pael J, Mirkovitch V, Jaffre F, Kappenberger L. Intravascular stents to prevent occlusion and restenosis after transluminal angioplasty. *N Engl J Med* 1987; 316:701-6.
- 12 Adam A, Chetty N, Roddie M, Yeung E, Benjamin IS. Self-expandable stainless steel endoprosthesis for treatment of malignant bile duct obstruction. *AJR* 1991;156: 321-5.
- 13 Antonucci F, Salomonowitz E, Stuckmann G, Stiefel M, Largiader J, Zollikofer CL. Placement of venous stents: clinical experience with a self-expanding prosthesis. *Radiology* 1992;183:493-7.
- 14 Sherry CS, Diamond NG, Meyers TP, Martin RL. Successful treatment of superior vena cava syndrome by venous angioplasty. *AJR* 1986;147:834-5.
- 15 Ali MK, Ewer MS, Balakrishnan PV, Ochoa DA, Morice RC, Raizner AE, *et al*. Balloon angioplasty for superior vena cava obstruction. *Ann Intern Med* 1987;107:856-7.
- 16 Williams G, Jajer R, McLoughlin J, Eldin A, Machan L, Gill K, *et al*. Use of stents for treating obstruction of urinary outflow in patients unfit for surgery. *BMJ* 1989; 298:1429.
- 17 Breckwoldt WL, Belkin M, Gould K, Allen M, Connolly RJ, Termin P. Modification of the thrombogenicity of the self-expanding vascular stent. *J Invest Surg* 1991; 4:269-78.