

Amblyopia induced by anisometropia without shrinkage of ocular dominance columns in human striate cortex

JONATHAN C. HORTON* AND MICHAEL P. STRYKER†

*Department of Ophthalmology and Koret Vision Research Laboratory of the Beckman Vision Center and †Department of Physiology and W. M. Keck Center for Integrative Neuroscience, University of California, San Francisco, CA 94143-0730

Communicated by Torsten N. Wiesel, March 12, 1993 (received for review November 17, 1992)

ABSTRACT Amblyopia can be induced by opacity of the ocular media (e.g., cataract), misalignment of the ocular axes (strabismus), or unequal refractive error in the eyes (anisometropia). Experiments in monkeys have shown that early monocular eyelid suture, a model of amblyopia caused by cataract, results in shrinkage of the eye's ocular dominance columns in striate cortex. This reduction of the geniculocortical projection from the deprived eye has been thought to explain in part the mechanism of amblyopia. We labeled the ocular dominance columns in monkeys with amblyopia by using cytochrome oxidase histochemistry. In animals rendered amblyopic by early unilateral eyelid suture, no pattern of cytochrome oxidase activity appeared in layer IVc. Outside layer IVc, alternating rows of light and dark patches were present; the pale patches fit in register with the shrunken ocular dominance columns of the deprived eye, which were labeled by autoradiography. Subsequent removal of one eye caused a striking cytochrome oxidase pattern to emerge in layer IVc that correlated precisely with the shrunken (deprived eye) and expanded (normal eye) ocular dominance columns. This correlation was shown by injecting one eye with [³H]proline. It has remained unsettled whether other forms of amblyopia are accompanied by shrinkage of ocular dominance columns. To address this issue, in an analogous clinical case, we examined the pattern of cytochrome oxidase activity in a human subject with a history of anisometropic amblyopia who suffered a lesion of one optic nerve shortly before death. The ocular dominance columns were normal in width, indicating that some forms of amblyopia occur without shrinkage of ocular dominance columns.

Amblyopia causes visual loss among ≈2% of the American population (1). The most severe form of the disease occurs in children born with a dense cataract in one eye. If cataract surgery is delayed beyond a critical period in early life, vision remains permanently impaired despite later removal of the offending media opacity and provision of the proper refractive correction. Without an ocular defect to explain the persistence of low acuity after cataract removal, it has long been suspected that amblyopia is due to anomalous wiring of the eye's central connections within the brain. Evidence in favor of this notion first came from a series of experiments by Wiesel and Hubel (2, 3), who created an animal model of amblyopia by raising kittens with the lids of one eye sutured. Upon recording from striate cortex, they found that the vast majority of cells responded exclusively to visual stimulation of the normal, open eye. Later, the apparent anatomical counterpart of this shift in physiological ocular dominance was demonstrated in cats and monkeys by injection of [³H]proline into the vitreous of the deprived eye. This procedure transneuronally labels the axon terminals of geniculate neurons in layer IVc of striate cortex (4), which are

segregated into a mosaic of alternating, parallel stripes serving the left eye or the right eye. These stripes are called ocular dominance (OD) columns (5). In normal subjects, the OD columns of the left eye and the right eye are roughly equal in width, whereas in animals raised with unilateral eyelid suture to simulate congenital cataract, the OD columns of the deprived eye appear dramatically shrunken (6–12). This column shrinkage presumably occurs because the deprived eye is handicapped in the competition between the two eyes for synaptic connections in layer IVc during early cortical development. Column shrinkage demonstrates that abnormal early sensory experience can disrupt the normal maturation of the cerebral cortex. It also provides an appealing explanation for the phenomenon of amblyopia: contraction of OD columns reduces the input to striate cortex serving the deprived eye, thereby partially disconnecting the eye from the cortical machinery required for the normal processing and interpretation of visual information.

Efforts to extend these models of amblyopia to the human condition have been hampered by the fact that various experimental methods suitable for labeling the OD columns in animals cannot be used in humans. However, in recent years, the OD columns have been labeled successfully by using a histochemical technique that reveals the distribution of cytochrome oxidase cyt_{ox} , a mitochondrial enzyme, within striate cortex (13). In normal monkeys, levels of cyt_{ox} are homogeneous throughout layer IVc because physiological activity is equal in columns belonging to the right eye and the left eye. After removal of one eye, a pattern of alternating pale and dark columns emerges in layer IVc (14, 15). It has been previously established by combining cyt_{ox} and [³H]proline eye injection in a double-label experiment that the pale columns correspond to the OD columns of the enucleated eye (16).

The cyt_{ox} method has the special advantage that it can also be used in the human brain postmortem to study patterns of metabolic activity (17). Specimens obtained from patients with a history of loss of one eye show a mosaic of alternating dark and light stripes, corresponding to the OD columns. The stripes appear equal in width, even when death ensues >20 years after the loss of one eye. This finding indicates that loss of one eye produces no shrinkage of OD columns, as long as it occurs after the critical period of column plasticity, which ends sometime during early childhood.

We have now applied cyt_{ox} histochemistry to investigate how amblyopia affects the OD columns in human amblyopia. Initial experiments were conducted in monkeys to lay the groundwork for interpreting the data from human studies. In the monkey experiments, we labeled the OD columns with [³H]proline and then correlated the pattern of autoradiographic label with the pattern of cyt_{ox} histochemistry in adjacent sections from the same animal. This approach allowed us to define the exact conditions required to label the OD columns with cyt_{ox} in amblyopic subjects. Armed with

The publication costs of this article were defrayed in part by page charge payment. This article must therefore be hereby marked "advertisement" in accordance with 18 U.S.C. §1734 solely to indicate this fact.

Abbreviations: OD, ocular dominance; cyt_{ox} , cytochrome oxidase.

this information, we then labeled the OD columns in a patient with a history of amblyopia from anisometropia.

MATERIALS AND METHODS

Visual Deprivation. Amblyopia was induced in cynomolgus monkeys (*Macaca fascicularis*) by suturing together the lids of the right eye under ketamine general anesthesia and lidocaine local anesthesia. With normal vision in the other eye, their growth and development was unimpaired. This procedure, and all other experimental procedures, was approved by the University of California, San Francisco, Committee on Animal Research.

[³H]Proline Injection. The OD columns were labeled by injection of [³H]proline into a single lamina of the lateral geniculate body. For geniculate injections, monkeys were initially anesthetized with ketamine and then maintained under general anesthesia with N₂O/O₂ (60:40) and continuous infusion of sodium thiopental. After endotracheal intubation and placement in a stereotaxic frame, monkeys were paralyzed with intravenous gallamine and artificially respired. The lateral geniculate body in each hemisphere was then located by recording with a tungsten microelectrode while stimulating the visual field with small spots of light. After location of a suitable injection site within 6° of the foveal representation (to label OD columns within the exposed, flat cortical operculum), the metal electrode was replaced with a glass pipette containing [³H]proline (20–40 Ci/mmol; 1 Ci = 37 GBq) dissolved in saline (0.2 mCi/μl). The planned injection site was verified by recording again through the glass pipette and [³H]proline was then pressure injected (0.5–1.0 μl) in the middle of a single lamina innervated by the deprived eye. Several injections were made in each animal. After a survival time of 3 days, to permit transport of radioactive label to the cortex, the monkeys were given a lethal dose of intravenous thiopental and perfused transcardially with fixative. In one monkey, the OD columns were labeled by intravitreal injection of 2 mCi of [³H]proline under general anesthesia. To maximize column labeling, the injection was repeated 3 days later. Tissues were processed for autoradiography or cyt_{ox} activity as described elsewhere (16–18).

RESULTS

The pattern of cyt_{ox} activity in striate cortex produced by neonatal eyelid suture was first studied in two monkeys. Amblyopia was induced by fusing the right eyelids 1 week after birth. At age 1 year, [³H]proline was injected into single laminae of the lateral geniculate body to label the cortical OD columns. Tracer injections were made in the lateral geniculate body rather than the eye, because eye injections carry a risk of altering cortical cyt_{ox} activity. Similar results were obtained in both animals. Autoradiographs revealed shrunken OD columns belonging to the amblyopic eye, as anticipated from the prior work of Hubel, Wiesel, and LeVay (6, 10) (Fig. 1A). However, adjacent sections processed for cyt_{ox} activity showed completely uniform enzyme activity in layer IVc (Fig. 1B), despite the fact that cyt_{ox} activity was sharply reduced in geniculate laminae supplied by the deprived eye. In layers II and III of striate cortex, alternating dark and light rows of cyt_{ox} patches (also called “blobs” or “puffs”) were visible (14, 15). The light rows of patches fit into precise register with the deprived, shrunken OD columns in layer IVc (data not shown).

In these experiments, the OD columns of the amblyopic eye showed no loss of cyt_{ox} activity in layer IVc, although severe anatomical shrinkage of the OD columns was confirmed by proline injection. This result means that cyt_{ox} histochemistry cannot be used to reveal the OD columns in

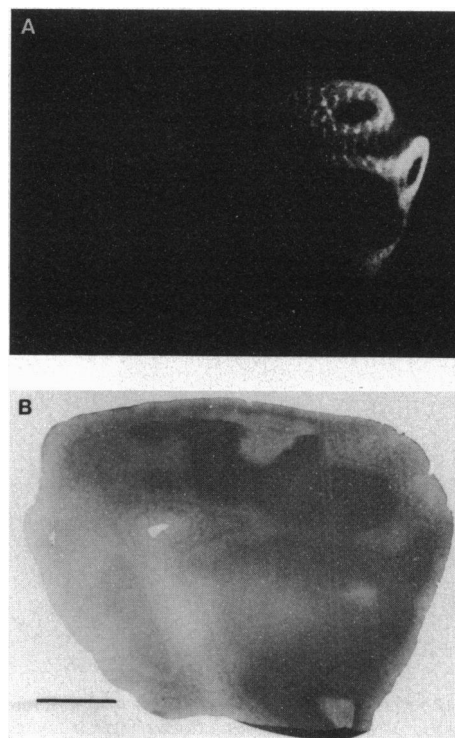


FIG. 1. (A) Autoradiograph from a visually deprived monkey showing the OD columns in layer IVc labeled by injection of [³H]proline into the lateral geniculate body. In this dark-field photograph, the shrunken OD columns of the amblyopic eye appear as thin, white stripes. (B) Adjacent section showing no columns of cyt_{ox} activity, despite shrinkage of the OD columns in A. (Bar = 5 mm.)

animals with amblyopia from early, severe unilateral media opacity, unless an additional manipulation is performed. We postulated that subsequent enucleation of one eye might allow one to label the OD columns by the cyt_{ox} method. To test this notion, the right eyelids of an additional monkey were fused a week after birth. The left occipital lobe was excised *en bloc* at age 21 months by a sterile neurosurgical technique under general anesthesia with sodium thiopental. No cyt_{ox} columns were visible within layer IVc (Fig. 2A), but alternating rows of pale and dark patches were visible in layers II and III (Fig. 2B). The findings in this hemisphere confirmed the results obtained in the two previous animals and served as an internal control for the effects of visual deprivation alone.

[³H]Proline was then injected into the animal's normal left eye to label the OD columns in the remaining right occipital lobe. A week later the left eye was enucleated using a sterile oculoplastic surgical technique under combined ketamine general anesthesia and lidocaine retrobulbar anesthesia, and the right eyelids were reopened. The monkey was treated with buprenorphine, a long-acting opioid analgesic, after each procedure to ensure analgesia. Adequate analgesia was judged by constant observation of the animal's behavior until full recovery, which occurred quickly after each procedure. During a 2-week survival period, the vision in the remaining right eye was tested daily, and the monkey could perceive light only, indicating that lid suture had produced a profound degree of amblyopia.

Serial sections were prepared from the right striate cortex for cyt_{ox} staining or autoradiography. In layer IVc, cyt_{ox} histochemistry showed thin dark columns alternating with wide pale columns (Fig. 2C). An adjacent section dipped for autoradiography (Fig. 2D) showed expanded columns of label from the normal eye, interrupted by thin gaps corresponding to the OD columns of the uninjected, amblyopic eye. These

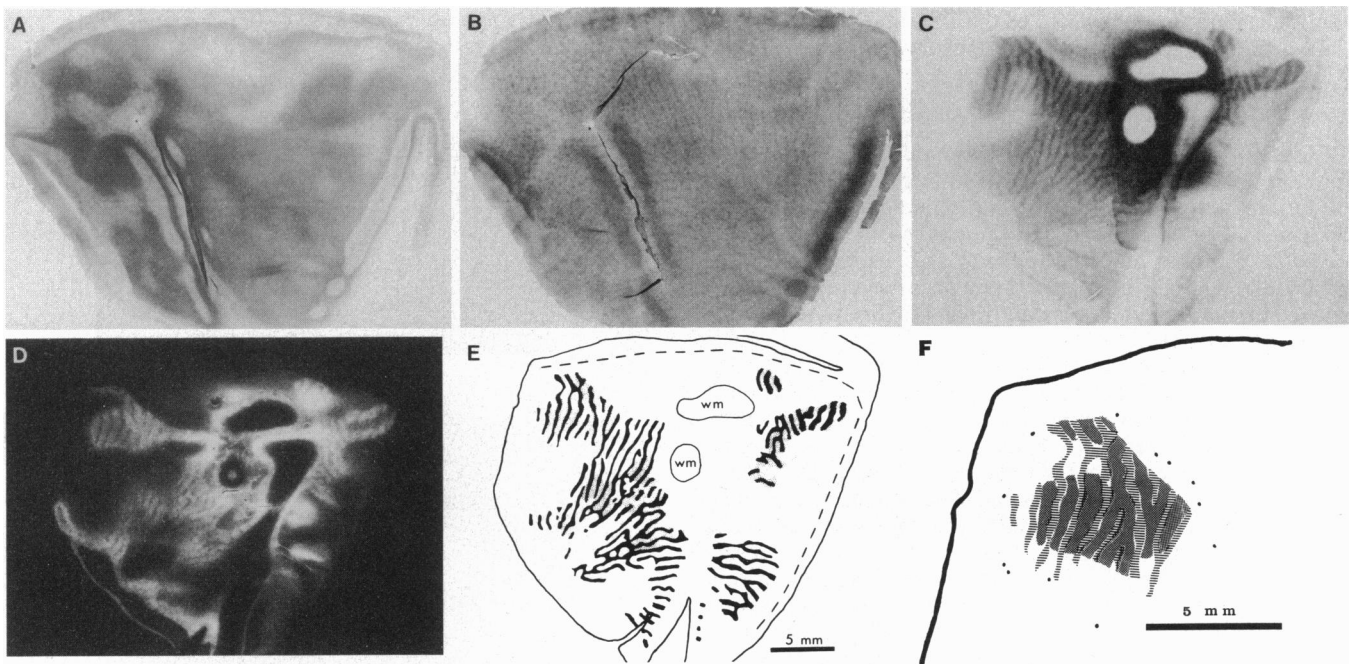


FIG. 2. (A) Flattened section through left occipital lobe of a lid-sutured monkey showing homogeneous cyt_{ox} activity in layer IVc (darkest regions) of striate cortex. (B) Section through upper layers, revealing alternating pale and dark rows of cyt_{ox} patches. (C) Matching right striate cortex from the same animal, 2 weeks after enucleation of the normal left eye, showing thin dark columns alternating with wide light columns in layer IVc. In this single section, OD columns are visible within 156 mm^2 of layer IVc; the dark/light column ratio is 37:63. (D) Dark-field autoradiograph from section adjacent to C, showing labeled OD columns of the left eye, which was injected with $[^3\text{H}]$ proline before enucleation. (E) Composite diagram depicting the dark cyt_{ox} columns in C with black ink and the autoradiographically labeled columns in D with stippling. Dashed line, V1/V2 border; wm, white matter. (F) Magnified view of columns in upper left portion of E. Parallel horizontal lines indicate dark cyt_{ox} columns in C, and small dots mark the OD columns labeled by autoradiography in D. Proline-labeled columns fit between the dark cyt_{ox} columns, proving that the dark, shrunken cyt_{ox} columns in C are the OD columns of the remaining, uninjected, amblyopic right eye.

two sections were aligned by matching small blood vessels to establish that the dark columns of cyt_{ox} activity fit within the label-free gaps of the autoradiograph (Fig. 2 E and F). This double-hemisphere, double-label experiment showed that enucleation of the normal eye causes thin, dark columns of cyt_{ox} activity to appear in layer IVc that precisely represent the OD columns of the amblyopic eye.

Equipped with an approach to label the OD columns in human amblyopia, we next studied the pattern of cyt_{ox} activity in the visual cortex of a 53-year-old man with anisometropic amblyopia detected at age 4.5–5 years in the left eye. Glasses were prescribed after the patient's amblyopia was discovered, but he wore them infrequently during his childhood. He never received patching therapy. There was no history of strabismus or cataract. He sought our evaluation after developing blindness in the right eye, which previously had normal acuity. His visual acuity was no light perception in the right eye and 20/400 in the left eye with best optical correction. Cycloplegic retinoscopy yielded a dioptric refractive error of +3.50 sphere, +0.75 cylinder $\times 175^\circ$, right eye; +8.50 sphere, +2.25 cylinder $\times 145^\circ$, left eye. The amblyopia was explained by nearly six diopters of anisometropia, which had produced a constantly blurred image upon the left retina.

A magnetic resonance scan showed a metastatic tumor from the lung compressing the right optic nerve. The patient died 3 months later, with no improvement in the vision of the amblyopic left eye after the right eye became blind. On microscopic examination, the left eye appeared entirely normal, thus fulfilling the essential criteria for amblyopia: poor vision without ocular pathology. The right eye showed depletion of ganglion cells and nerve fiber layer from compression of the optic nerve.

Sections were cut through flattened blocks from the occipital lobes and processed for cyt_{ox} . Alternating dark and

light stripes were visible in sections passing through layer IVc of striate cortex (Fig. 3 A and B). The overall pattern of stripes was reconstructed by tracing serial sections in a microscope projector (Fig. 3 C and D). By analogy with the prior monkey experiment, the dark stripes of cyt_{ox} activity correspond to the OD columns of the intact, amblyopic left eye. This inference is supported by noting that the monocular crescent representation appears light in the left striate cortex and dark in the right striate cortex, as expected after loss of the right eye. Surprisingly, the dark columns of the amblyopic left eye do not appear shrunken. Indeed, the OD column mosaic is indistinguishable from column mosaics reconstructed previously in normal patients without amblyopia (18). There are regions of local irregularity in column width, as also found in specimens from normal patients, but the total area occupied by each eye's set of columns is nearly equal. In each hemisphere we reconstructed $\approx 75\%$ of the mean surface area of human primary visual cortex. Columns were traced over 1646 mm^2 in the left striate cortex, and the dark stripes occupied 48% of the total column area. Columns were reconstructed over 1436 mm^2 in the right striate cortex, and dark stripes accounted for 54% of the column area. In calculating these percentages the contribution of the monocular crescent was excluded. The slight predominance of the contralateral eye in each cortex reflects the normal attenuation of the ipsilateral eye's columns, which occurs in peripheral binocular cortex (18, 19).

DISCUSSION

Our observations provide further information pertaining to the structural changes that underlie amblyopia in the visual cortex of primates. We find that eyelid suture in neonatal monkeys causes no loss of metabolic activity in layer IVc (Fig. 4)—as reflected by levels of cyt_{ox} —despite anatomical

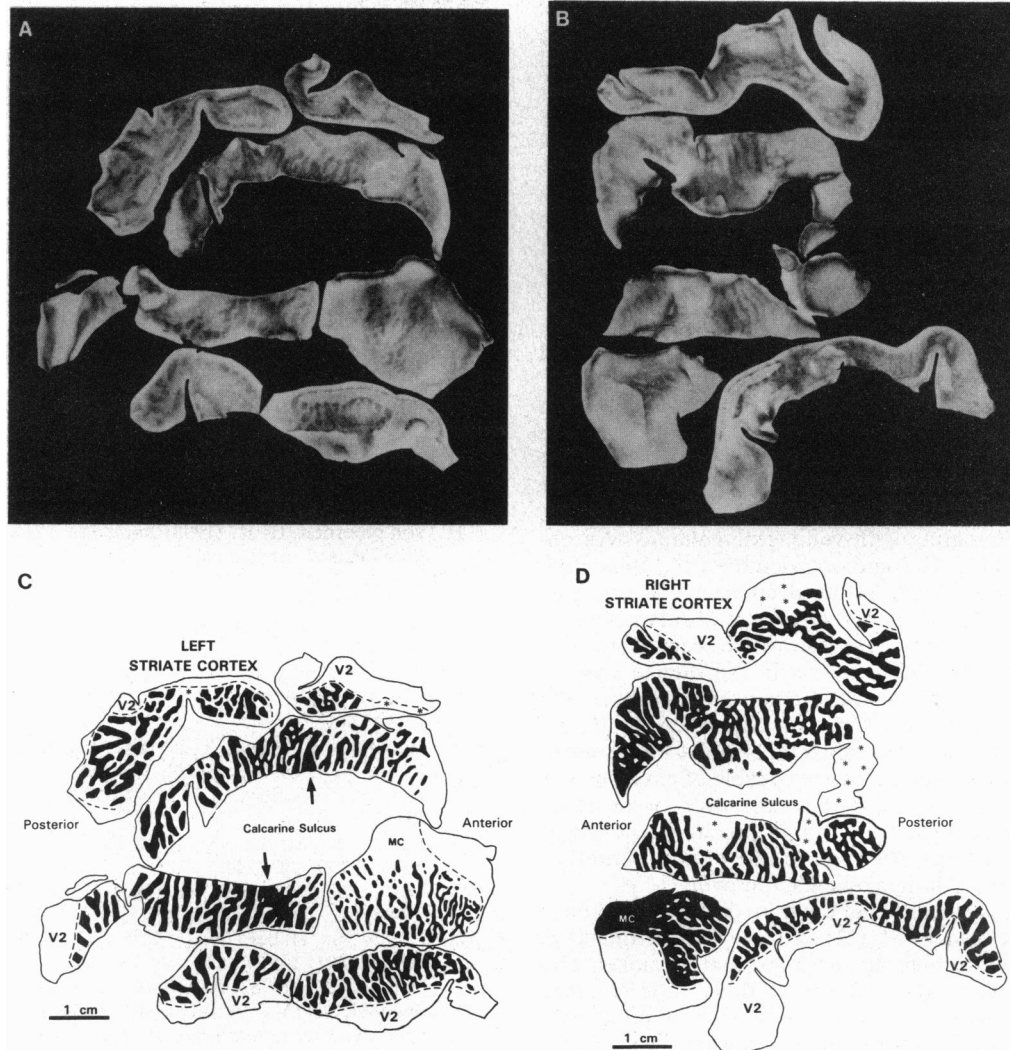


FIG. 3. Flattened sections reacted for cyt_{ox} showing OD columns from the left *A* and right *B* striate cortex of a man with anisometric amblyopia in the left eye. Reconstruction of columns in the left *C* and right *D* cortex from serial sections cut through each tissue block reveals no shrinkage of the dark columns corresponding to the amblyopic eye. Dashed line, V1/V2 border; MC, monocular crescent; *, regions where columns were unclear. Arrows in *C* mark matching portions of the optic disc representation of the right eye, which were apposed in the brain prior to dissection. Note that OD columns in humans are wider than those in macaques, and, consequently, human visual cortex contains fewer hypercolumns.

shrinkage of the OD columns. The absence of a cyt_{ox} pattern in layer IVc is consistent with recent findings obtained by Tigges *et al.* (20) in monkeys raised with an opaque contact lens in one eye. This result is also consistent with the report by Hubel *et al.* (6) that within layer IVc of early lid-sutured monkeys, the cells serving the amblyopic eye retain brisk responses and normal receptive field properties. By contrast, outside layer IVc, Hubel *et al.* encountered virtually no cells that could be driven effectively via the amblyopic eye. It has remained uncertain whether this shift in eye preference outside layer IVc occurs because lid suture causes cells to switch their allegiance to the normal eye, or because cells originally destined to favor the amblyopic eye simply become less responsive to visual stimulation. Our observation of diminished cyt_{ox} activity in rows of patches aligned with the OD columns of the amblyopic eye (Fig. 4) provides evidence that favors the latter possibility.

Although our results indicate that early lid suture in monkeys produces no pattern of cyt_{ox} activity in layer IVc of striate cortex, subsequent enucleation of one eye gives rise to a striking cyt_{ox} pattern of alternating light and dark stripes. By ocular injection of [3H]proline, we have established that these stripes correspond precisely to the anatomical OD

columns. In our experiment, the normal eye was removed, and the resultant dark thin stripes were shown to represent the OD columns of the remaining, amblyopic eye (Fig. 4). If

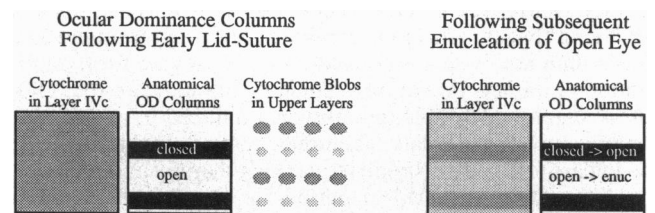


FIG. 4. Summary diagram showing that early eyelid suture in monkeys induces no pattern of cyt_{ox} activity in layer IVc, despite shrinkage of OD columns verified by [3H]proline injection into the lateral geniculate body. Cyt_{ox} staining in upper layers reveals small, pale patches in register with the shrunken OD columns of the amblyopic eye. Subsequent enucleation of the open eye causes a cyt_{ox} pattern of wide, pale stripes alternating with thin, dark stripes in layer IVc. These cyt_{ox} stripes correspond precisely to the anatomical OD columns labeled by eye injection of proline. In this experiment, we reopened the sutured eye, but we doubt the cyt_{ox} pattern would have differed had the amblyopic eye been left closed.

we had enucleated the amblyopic eye, a pattern of wide dark cyt_{ox} columns (normal eye's OD columns) alternating with thin, pale cyt_{ox} columns (amblyopic eye's OD columns) would be predicted, although we have not done this experiment. We chose to enucleate the normal eye in our monkey experiment in order to mimic the human case as closely as possible.

Among humans the most common cause of amblyopia is not cataract but strabismus or anisometropia (1). We have labeled the OD columns in a human subject with a history of amblyopia caused by uncorrected anisometropia during early childhood. The OD columns in visual cortex were completely normal in width. From prior animal studies of amblyopia induced by eyelid suture (6–12) or atropine blur (21) we had anticipated that the OD columns might be shrunken.

Hendrickson *et al.* (21) have studied monkeys raised with daily atropine drops in one eye to simulate anisotropic amblyopia. In one animal, cyt_{ox} activity in layer IVc was uniform, whereas in another animal the enzyme yielded poor staining. In the remaining six animals, a cyt_{ox} pattern of thin, dark columns alternating with wide, pale columns was observed in layer IVc. The authors identified the thin, dark columns as the OD columns of the atropinized eye, inferring that amblyopia induced by visual blur is accompanied by shrinkage of OD columns. This result would seem contrary to the finding of normal OD columns in the human case of anisotropic amblyopia we have analyzed. However, the animal model is different from our clinical case. In the monkeys, atropinization was initiated 2–14 days after birth, at a time when the OD columns are capable of expansion or retraction. We do not know the exact age of onset of anisometropia in our patient, but it probably developed several years after birth. By this age, the critical period for OD column plasticity in humans may be over.

There is also a possibility that the thin, dark cyt_{ox} columns seen by Hendrickson *et al.* (21) in layer IVc of monkeys raised with atropine blur do not represent shrunken OD columns. A similar cyt_{ox} pattern of thin, dark columns alternating with wide, pale columns has been previously reported after eyelid suture in adult monkeys, whose anatomically labeled OD columns were normal (16). In these monkeys (deprived as adults) the thin, dark cyt_{ox} columns in layer IVc were centered within the anatomical OD columns belonging to the normal open eye, but were narrower than the actual OD columns. The basis for the cyt_{ox} pattern found in these adult-suture experiments remains to be explained, but this result indicates that visual deprivation is capable of inducing patterns of cyt_{ox} activity in layer IVc that do not represent the OD columns, at least as they would be defined by ocular injection of [^3H]proline.

We conclude that anisometropia may induce amblyopia without shrinkage of OD columns in human visual cortex, implying that this form of amblyopia has a different cortical basis than amblyopia produced by early, severe form deprivation (cataract, lid suture). Clinical data indicate that children remain vulnerable to amblyopia induced by strabismus or anisometropia (or late, acquired cataract) until at least age 6–7 years (1). They respond to patching therapy until this age, or even later. The critical period for the plasticity of OD columns is over by 3 months of age in monkeys (10). The duration of the critical period for anatomical plasticity of OD columns in layer IVc of human striate cortex is still unknown, but it is unlikely to extend beyond 1 year of age. We propose

that in milder forms of human amblyopia—namely, those caused by later, acquired media opacity, strabismus, or anisometropia—the OD columns in layer IVc are normal but neural connections are perturbed between layer IVc and other cortical layers. This interpretation is consistent with the finding in cats and monkeys that the critical period in layer IVc ends long before the critical period in other cortical layers (10, 22–25). Further study of more human cases should allow us to delineate the critical period for maturation of the OD columns and to describe more completely the pathological changes that accompany different forms of amblyopia.

We thank Gary E. Baker and Creig S. Hoyt for review of the manuscript, and Dr. P. Sehgal and the N. E. Regional Primate Center for supplying the monkeys. The patient was cared for by Dr. Warren Borgquist. This work was supported by National Eye Institute Grants EY08755 to J.C.H. and EY02874 to M.P.S., and by grants from the National Children's Eye Care Foundation, Research to Prevent Blindness, and That Man May See, Inc.

1. von Noorden, G. K. (1990) *Binocular Vision and Ocular Motility* (Mosby, St. Louis).
2. Wiesel, T. N. & Hubel, D. H. (1963) *J. Neurophysiol.* **26**, 1003–1017.
3. Wiesel, T. N. & Hubel, D. H. (1965) *J. Neurophysiol.* **28**, 1029–1040.
4. Wiesel, T. N. & Hubel, D. H. (1974) *Brain Res.* **79**, 273–279.
5. Hubel, D. H. & Wiesel, T. N. (1977) *Proc. R. Soc. London Ser. B* **198**, 1–59.
6. Hubel, D. H., Wiesel, T. N. & LeVay, S. (1977) *Philos. Trans. R. Soc. London Ser. B* **278**, 377–409.
7. Shatz, C. J. & Stryker, M. P. (1978) *J. Physiol. (London)* **281**, 267–283.
8. LeVay, S., Stryker, M. P. & Shatz, C. J. (1978) *J. Comp. Neurol.* **179**, 223–244.
9. LeVay, S. & Stryker, M. P. (1979) *Soc. Neurosci. Symp.* **4**, 83–98.
10. LeVay, S., Hubel, D. H. & Wiesel, T. N. (1980) *J. Comp. Neurol.* **191**, 1–51.
11. Wiesel, T. N. (1982) *Nature (London)* **299**, 583–591.
12. Swindale, N. V., Vital-Durand, F. & Blakemore, C. (1981) *Proc. R. Soc. London Ser. B* **213**, 435–450.
13. Wong-Riley, M. (1979) *Brain Res.* **171**, 11–28.
14. Horton, J. C. & Hubel, D. H. (1981) *Nature (London)* **292**, 762–764.
15. Hendrickson, A. E., Hunt, S. P. & Wu, J.-Y. (1981) *Nature (London)* **292**, 605–607.
16. Horton, J. C. (1984) *Philos. Trans. R. Soc. London Ser. B* **304**, 199–253.
17. Horton, J. C. & Hedley-Whyte, E. T. (1984) *Philos. Trans. R. Soc. London Ser. B* **304**, 255–272.
18. Horton, J. C., Dagi, L. R., McCrane, E. P. & deMonasterio, F. M. (1990) *Arch. Ophthalmol.* **108**, 1025–1031.
19. LeVay, S., Connolly, M., Houde, J. & Van Essen, D. C. (1985) *J. Neurosci.* **5**, 486–501.
20. Tigges, M., Boothe, R. G., Tigges, J. & Wilson, J. R. (1992) *J. Comp. Neurol.* **316**, 173–186.
21. Hendrickson, A. E., Movshon, J. A., Eggers, H. M., Gizzi, M. S., Boothe, R. G. & Kiorpes, L. (1987) *J. Neurosci.* **7**, 1327–1339.
22. Blakemore, C., Garey, L. J. & Vital-Durand, F. (1978) *J. Physiol. (London)* **238**, 223–262.
23. Cynader, M., Timney, B. N. & Mitchell, D. E. (1980) *Brain Res.* **191**, 545–550.
24. Olson, C. R. & Freeman, R. D. (1980) *Exp. Brain Res.* **39**, 17–21.
25. Daw, N. W., Fox, K., Sato, H. & Czepita, D. J. (1992) *J. Neurophysiol.* **67**, 197–202.