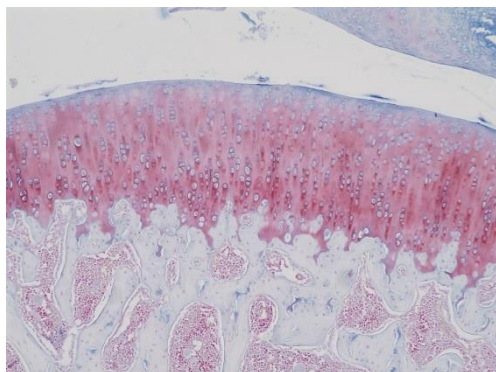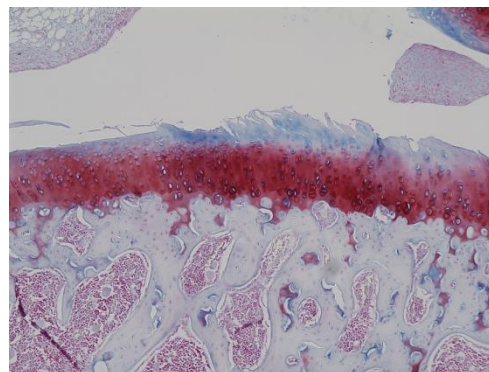
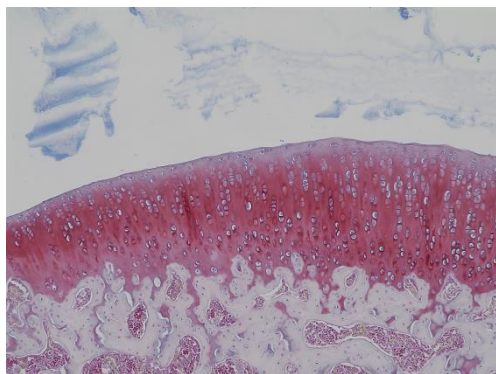


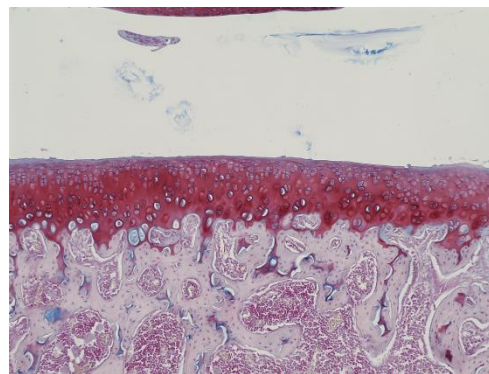
Sham-operated rats



Non-treated control
rats with OA



Boiogito (2%)-treated
rats with OA



Indomethacin-treated
rats with OA

Supplemental Fig. 1. Histochemical changes in joints of rats with osteoarthritis. Cartilage surface irregularities, diffuse hypercellularity, and decreased Safranin O staining were seen in joints of rats with OA 4 weeks after surgery. Daily administration of boiogito and indomethacin partially tended to alleviate the histochemical changes in articular cartilage of rats with OA.