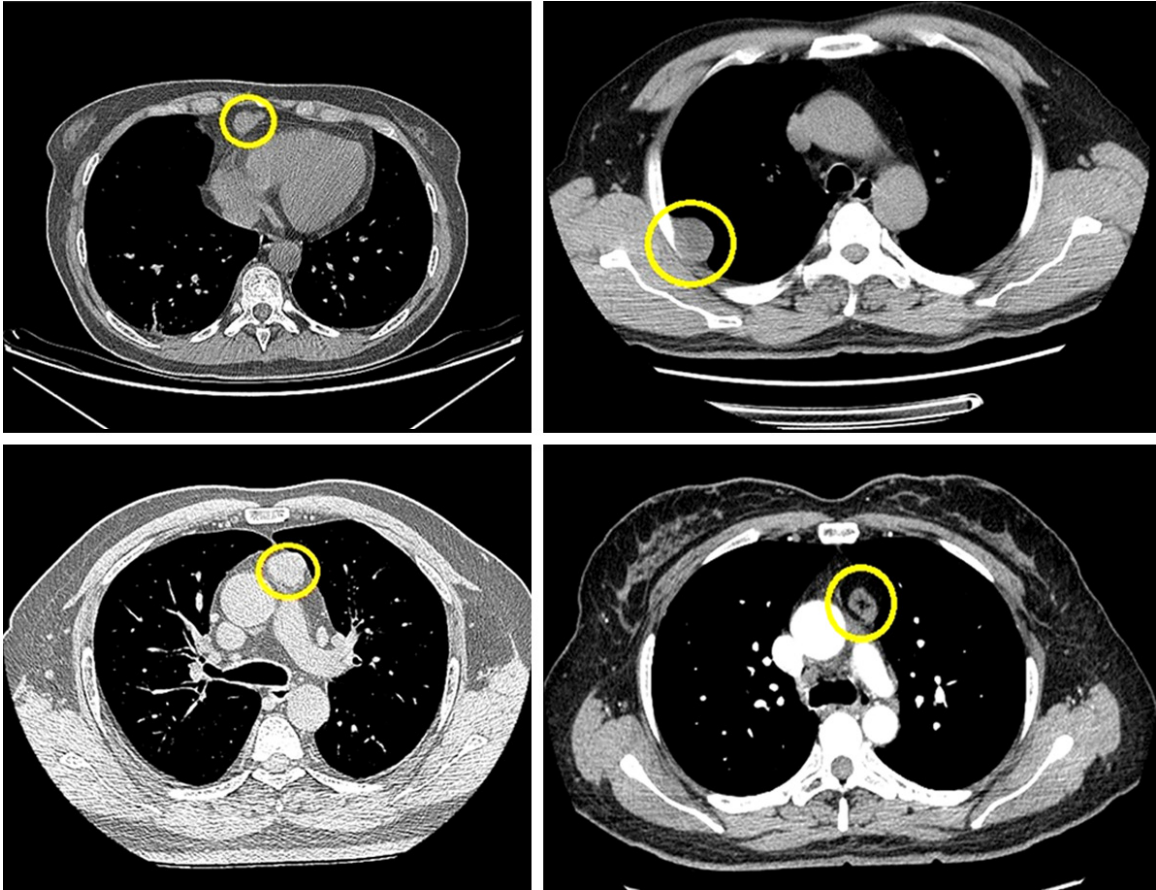


Application of 3DR in selection of TSO with robot



Supplementary Figure 1. Actual locations of the tumor in thoracic CT slices obtained from the 4 different patients enrolled in the current study.