

## SENILE CARDIAC AMYLOIDOSIS

BY

ARIELA POMERANCE\*

*From the Department of Morbid Anatomy and Histology, Central Middlesex Hospital, Park Royal,  
London N.W.10*

Received August 17, 1964

Although the unexplained occurrence of amyloid deposits in the elderly was first described as long ago as 1876 (Soyka), it is not generally realized that appreciable deposition of amyloid is found in a high proportion of elderly people, and is almost entirely localized to the heart. A preliminary investigation has shown this condition in 10 per cent of patients over 80 dying in this hospital, and an incidence ranging from 2 to 15 per cent has been reported from other countries. If these figures are representative, senile cardiac amyloid would appear to be the commonest existing form of amyloid, and likely to continue increasing with the increasing age of the population.

Since clinical signs and symptoms are produced in many cases, and there is an increased likelihood of digitalis sensitivity in patients with cardiac amyloidosis (Cassidy, 1961), this condition should be considered in the differential diagnosis of any elderly patient with congestive heart failure.

### SUBJECTS AND METHODS

The gross and microscopical pathology and clinical records of 21 patients with senile cardiac amyloidosis were studied. Of these 21, 20 were found in 226 hearts from patients over 75, which formed part of an investigation into various aspects of geriatric heart disease (Pomerance, 1965). The remaining patient was the only previous example in our necropsy records. This was in a man aged 87 in whom a curious greyish black "peppering" of the left atrial endocardium (Fig. 1) had been noted as an incidental finding at necropsy. The nature of this appearance was not clear at the time, but microscopy showed that it was due to nodular deposits of amyloid in the endocardium (Fig. 2 and 4).

During the period of the investigation, the hearts of almost all adults dying in this hospital were examined macroscopically in greater detail than usual, while all hearts from patients over the age of 80 were fixed in formalin for subsequent histological examination. A number from younger age-groups have also been fixed and sectioned for comparison, together with all hearts with any lesion, however minor, the nature of which was not immediately apparent from naked eye examination. Altogether 393 hearts were examined after fixation in a 16-months period up to January 1964. The sex and age distribution are shown in Fig. 3.

Deposits of amyloid were found in 20: 16 were diagnosed on macroscopic examination by the characteristic appearance of the amyloid nodules in the atrial endocardium, but, in all except the most severely involved hearts, this appearance was not easily visible before formalin fixation and could have been overlooked on inspection of fresh specimens only. For this reason, only hearts which had also been examined after fixation were considered in assessing the proportion of patients in whom predominantly cardiac amyloid deposition was present.

In the course of this study it was noted that a high proportion of hearts from patients over 90 showed macroscopically identifiable amyloidosis. The sections of all the patients in this group were therefore re-examined by methyl violet staining, and two further cases were found with small deposits that had not been obvious from the routine hæmatoxylin and eosin, and elastic van Gieson preparations.

\* In receipt of a grant from the North West Metropolitan Regional Hospital Board.

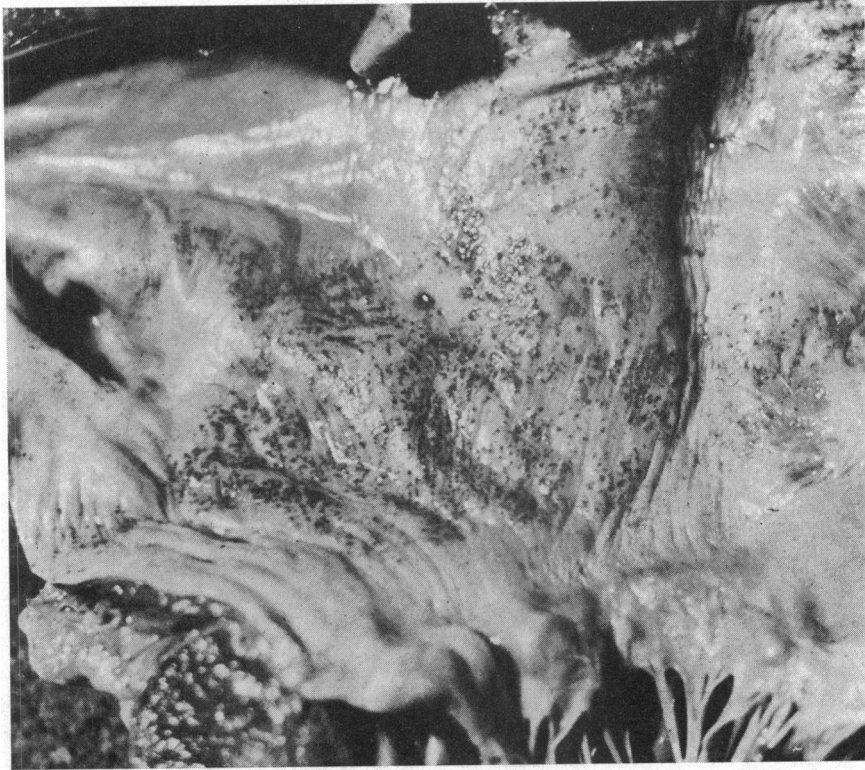

FIG. 1.—Heart opened to show part of left atrium with multiple small dark foci of amyloid in the atrial endocardium (formol saline fixed specimen). ( $\times 2$  approx.)

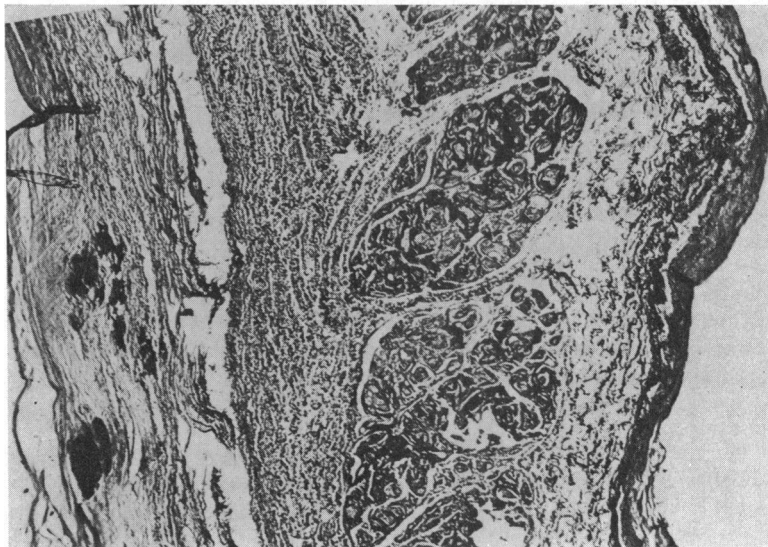


FIG. 2.—Photomicrograph of atrial septum, showing nodular masses of amyloid in the endocardium of the left atrium, and heavy deposition of amyloid around the myocardial fibres. (Methyl violet.  $\times 45$ .)

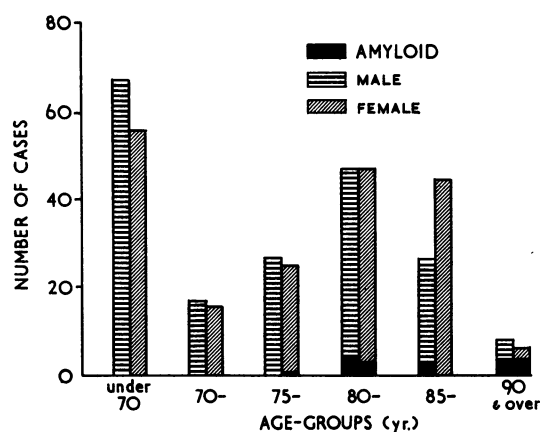


FIG. 3.—Distribution of cases examined and incidence of amyloid by age-group and sex.

To determine whether similar small deposits had been overlooked in a significant number of cases already examined, the sections of myocardium from 76 further patients were similarly reassessed. These included 10 who had died in congestive heart failure, the cause of which was not apparent from either the necropsy or the clinical records, 8 with ischæmic heart disease, 16 with hypertension, 4 with chronic valvular disease, 3 with chronic pulmonary heart disease, and one with bacterial endocarditis. The remaining 34 patients were mainly over 80 years of age, but were otherwise unselected.

#### RESULTS

The clinical and pathological data of the patients with senile cardiac amyloidosis are summarized in the Table. There were 13 men and 8 women. Ages ranged from 77 to 97 years; only one patient was under 80 years of age, and 8 were over 90. The average age was 87 years. Percentage incidence for all the cases over 80 years examined was 12 per cent for men and 8 per cent for women. In the over 90 group, there were only 16 cases, but half of these had cardiac amyloidosis. Heart weights ranged from 230 to 720 g. (average 399 g.), and in most instances the weight was not related to the severity of the amyloidosis. Other forms of heart disease were present in 7 patients, 4 ischæmic, 2 hypertensive, and 1 rheumatic, but were not solely responsible for death; 11 died with congestive heart failure, and in 5 of them the ætiology had not been suspected. One patient had been fibrillating, but was not in failure at the time of death.

Electrocardiograms were available for study in 7 cases, but did not show any diagnostic features. Widespread T wave flattening with changes attributed to left ventricular hypertrophy were seen in one patient, and conduction defects with complete heart block in 2. Among the remaining patients, ischæmic patterns were found in two, while in two there was no significant abnormality. Three patients were noted as being sensitive to digitalis, and one with the most severely affected heart in this series developed fatal ventricular tachycardia soon after digitalis treatment for congestive cardiac failure was begun.

Since malnutrition has been considered a possible cause the state of nutrition of these patients was assessed, and graded as normal, thin, and obese. Adequate information on the social circumstances was also available in 14 patients, and it appeared that 10 were well looked after, with satisfactory dietary supervision, 2 lived alone or in company with equally elderly relatives, and their diet may well have been restricted, and 2 were suffering from nutritional deficiency on admission. Thirteen patients were noted as thin, one was obese, and the remainder appeared normally nourished.

The quantity of amyloid in the heart was roughly assessed as slight, moderate, or marked deposition, from the appearances of the methyl violet stained sections of myocardium. Deposition was

TABLE  
SUMMARY OF MAIN CLINICAL PATHOLOGICAL FINDINGS IN 21 PATIENTS EXAMINED

Case No., age (yr.), and sex	Nutrition	Congestive failure	Severity of amyloid	Other cardiac pathology	ECG changes	Comments
1 87 M	Normal	+	+		Abnormal Q waves in V2 and V3 suggesting antero- septal infarction	
2 92 M	Normal	+	++	Old (fibrotic) infarct		Sensitive to digitalis
3 77 F	?	-	++		Nothing significant	On steroids
4 82 M	Normal	+	+++	Previous hypertensive heart disease		Sensitive to digitalis
5 91 F	Normal	-	+			
6 88 M	Normal	+	+	Hypertensive heart disease	Heart block	Rheumatoid arthritis and anæmia
7 91 M	Thin	-	++	Old (fibrotic) infarct	Suggestive of ischæmia	
8 80 F	Thin	?	+++		Nothing significant	
9 96 M	Thin	+	+++			
10 96 F	Thin	-	++			
11 84 F	Thin	+	+++			Hypo- albuminæmia
12 86 M	Thin	-	++			Hypo- albuminæmia
13 95 F	Obese	+	++			Hypo- albuminæmia
14 97 F	Thin	-	++			
15 81 M	Normal	-	+			
16 92 M	Thin	+	++	Mild rheumatic mitral stenosis	Heart block	
17 80 F	Thin	-	++			
18 81 M	Thin	+	++++	Small infarct		Deterioration on digitalis
19 82 M	Thin	+	++		Widespread T wave flattening; changes of LV hypertrophy	Sensitive to digitalis
20 87 M	Thin	-	++	Small area of fibrosis		
21 84 M	Thin	-	+			

slight in 4, and was not apparent macroscopically in 3. Only 1 of the 4 was in congestive heart failure, and since this patient also had hypertensive heart disease and anæmia, it did not seem likely that the small amount of amyloid present in the myocardium contributed significantly. Conspicuous amyloid infiltration (Fig. 2) was seen in 5 patients, 4 of whom were in congestive cardiac failure. All remaining 12 patients had moderate deposits of amyloid (Fig. 5); 5 were in congestive failure.

Routine sections of the other organs were searched for amyloid, but no significant quantities were found. Small amounts of amyloid were seen in an occasional small hepatic and splenic vessel in 2 patients, otherwise the sections of liver, spleen, kidney, pancreas, and intestine were free from amyloid deposits. Small deposits in pulmonary alveolar walls or in small arteries were relatively frequent, occurring in half the cases. Uterine vessels in two and prostatic vessels in one contained small areas of material that stained as amyloid, and similar involvement of a few small tongue and thyroid vessels was present in another instance. These small quantities of amyloid interstitial deposits were confined to vessel walls, and in none of these patients was there suggestion of the pattern of secondary amyloidosis or of the usual primary form.

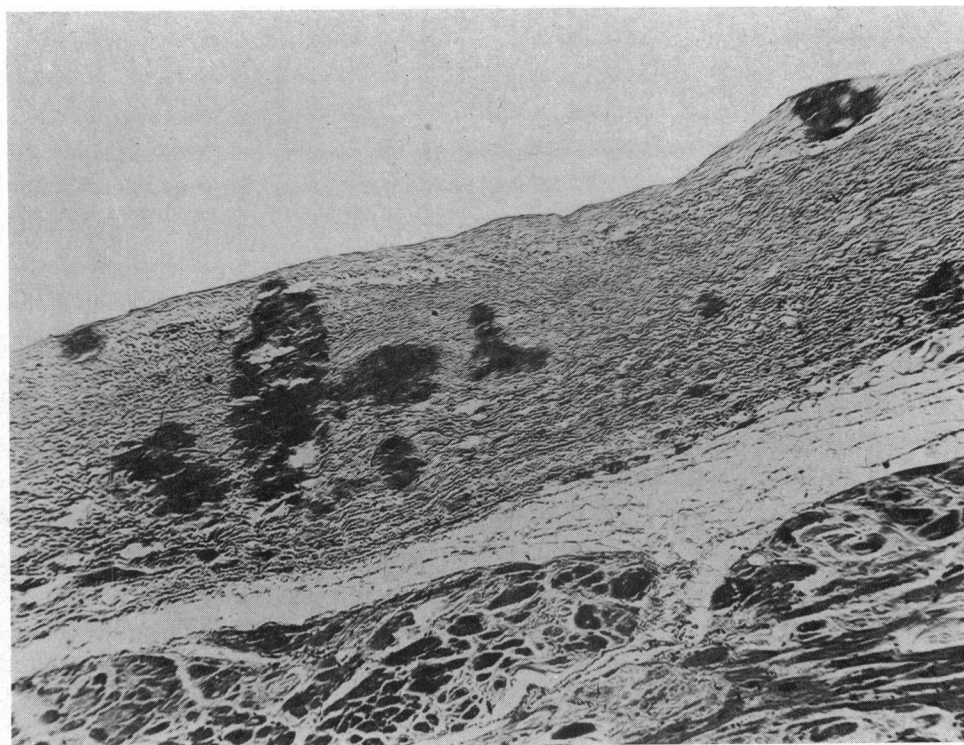


FIG. 4.—Photomicrograph of left atrium showing nodular masses of amyloid confined to the endocardium.

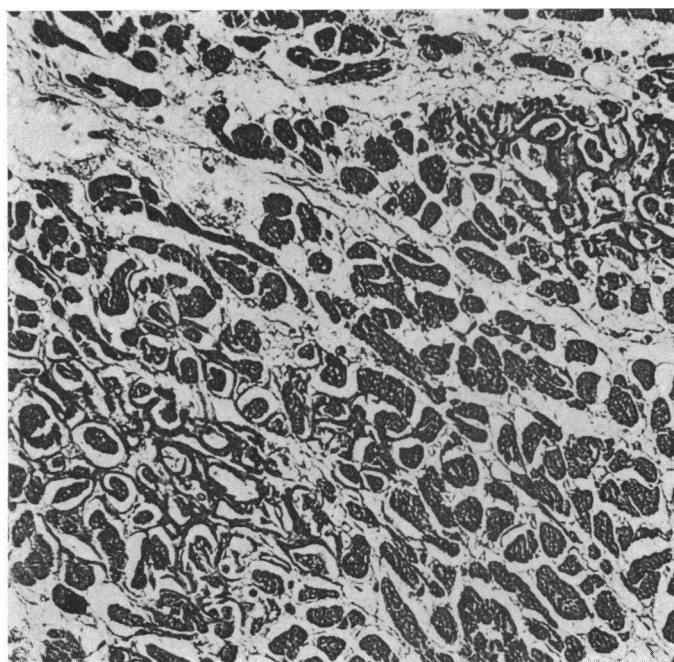


FIG. 5.—Photomicrograph of left ventricular myocardium, showing two areas of moderately heavy amyloid deposition around the muscle fibres. (Methyl violet.  $\times 83$ .)

## DISCUSSION

The first description of senile cardiac amyloidosis is generally attributed to Soyka (1876). At this time amyloidosis was thought to be always associated with chronic suppuration, but Soyka mentions its occurrence without apparent predisposing disease, and describes predominantly cardiac involvement in two elderly patients. Almost 60 years later, when Budd (1934) recorded primary amyloidosis of the heart in a man of 75, the concept of primary amyloid was beginning to be accepted. Budd's case report contains the first illustration of the atrial nodules which appear to be a characteristic feature of senile cardiac amyloidosis, and which are the only macroscopic feature on which this diagnosis can be made at necropsy. Subsequently, several papers describing small groups of cases appeared—3 from Scandinavia (Ranström, 1946), 5 (King, 1948) and 7 (Lee and Kaufmann, 1957) from America. Following King's report, and a study of primary amyloid made by Dahlin (1949), it was realized that amyloid confined to the heart might not be uncommon in the elderly, and Dahlin and Edwards (1949) in a pilot investigation found 5 cases in 100 men aged 80 to 90. This study was later extended (Josselson, Pruitt, and Edwards, 1952) to cover 100 hearts from each sex in the seventh and eighth decades, and amyloid was found in 20.

Mulligan (1958) found 17 examples in a period of 15 years in his study of causes of death over the age of 70. Buerger and Braunstein (1960) compared the incidence in two spaced five-year periods and found an increase from 0.02 per cent in 1940–41 to 2.0 per cent in 1953–57. They attributed this to an increase in the number of patients in the tenth decade rather than to any true increase in incidence of the disease.

The authors of these last three papers also discuss the clinical features and possible causes, as do briefly the two most recent communications on this subject (Eliot, McGee, and Blount, 1961; and Delarue *et al.*, 1963). Although such work emanates mainly from centres in the U.S.A., the largest and most comprehensive study is from Hamburg, where Hüsselmann (1955) found senile cardiac amyloid in 15 per cent of men over 70. The higher incidence is of interest in view of the possible nutritional basis of this disease, since the standard of nutrition in Germany is likely to have been lower than in America during the period in which Hüsselmann's investigation took place.

There do not appear to be any comparable figures from Britain, though McKeown (1963) found 6 instances in a necropsy survey of heart disease in 1500 patients over 70 years in Belfast, and this condition is generally considered to be rare except by those who have made a study of amyloidosis (Symmers, 1956). It seems likely that the apparent rarity is due largely to failure to consider this diagnosis both by the clinician and pathologist, and one of the purposes of this communication is to emphasize the comparative frequency of cardiac amyloid in the aged to increase its recognition in the future.

Although the cardiovascular distribution and lack of any known causative disease place senile cardiac amyloidosis among the primary amyloidoses, the consistent pattern of predominant, almost exclusive cardiac involvement, and the age of the patients, justify its consideration as a separate group (Briggs, 1961). Furthermore, while primary amyloidosis in middle age is a rare disease, senile cardiac amyloid appears common, and was present in 10 per cent of patients over 80, and 50 per cent of those over 90, coming to necropsy in this hospital during a period of 16 months.

It is difficult to assess the full clinical significance of the condition since multiple pathology is common in the elderly. Mulligan (1958) considered it contributed to death in all his 17 cases, and was the primary cause in 7; others (Josselson *et al.*, 1952; Buerger and Braunstein, 1960) found cardiac failure in a considerably lower proportion of their cases. As might reasonably be anticipated, patients with severe cardiac deposition were more likely to have congestive cardiac failure than those with only moderate deposition. Among the patients from this hospital, 11 of the 21 died in congestive cardiac failure, and no cause other than the amyloidosis could be demonstrated in 5. In the 4 patients in whom only small amounts of amyloid were seen, these did not appear to have had any clinical significance. Heavy deposits were associated with failure in 5, and were the only cardiac abnormality in 3, though one of these had also been anæmic for several years. A fourth patient, though normotensive terminally, had had hypertensive heart disease for many years,

but his heart failure was of progressive and intractable type and he was sensitive to digitalis, which suggests that the amyloid played a significant part in the pathogenesis of his heart failure. Digitalis sensitivity has been suggested by Cassidy (1961) as a finding of diagnostic value in cardiac amyloidosis, and of our 11 patients in congestive cardiac failure, 4 showed this sensitivity. It was noted in the clinical findings of earlier admissions in 3 patients, and a further patient developed ventricular tachycardia when routine therapy for congestive cardiac failure was begun. Amyloid deposition was classed as moderate in 2 of these and severe in the remaining 2 (Fig. 2). Of the 5 with moderate amyloidosis in congestive cardiac failure, 2 had no other cardiac lesion, one had right ventricular hypertrophy secondary to chronic bronchitis, one had an old myocardial infarct, and one had mild rheumatic mitral stenosis. Since this patient had survived to 92 years without any symptoms from his rheumatic heart disease, it may reasonably be assumed to have little part in his terminal cardiac failure. The patient with old myocardial infarction was one of those sensitive to digitalis, which suggests that the amyloidosis was an important factor in his case.

The findings in the present series are similar to those of the American investigators, and indicate that senile cardiac amyloidosis is a disease of clinical importance and should be considered among the differential diagnoses of possible pathological processes underlying any case of congestive cardiac failure in the elderly, and particularly likely in cases where other cardiac disease is absent or does not appear sufficiently severe to account for the failure. Clinical confirmation of the diagnosis is difficult, since the only significant deposits are found in the heart, and the usual biopsy sites are unlikely to show amyloid deposits, even when severe cardiac involvement is present. Similarly the Congo red test is likely to be negative, as the total amount of amyloid in the body is small. Cardiographic changes are also of no diagnostic value (Josselson *et al.*, 1952); no specific changes were found in the tracings available from our patients, though these were carefully re-examined after the necropsy diagnosis of cardiac amyloid was known. It is possible that a radioactive uptake test may be feasible and provide the answer, at a future date, but at present there are no diagnostic laboratory investigations. Plasma protein estimations and electrophoresis may be of value. Hüsselmann (1955) found a decrease in total protein and albumin, with frequent moderate increases in  $\alpha_2$  and  $\gamma$  globulin in the serum analysed *post mortem* in 14 patients. In 3 of our patients plasma proteins had been investigated, and albumin was found to be decreased in all. As Hüsselmann points out, these findings are non-specific. Mulligan (1958) has suggested that malnutrition is an important aetiological factor, and the protein changes may be secondary to faulty absorption or utilization of protein. Of our patients, 13 were described as thin or emaciated, 6 as normal, and one as obese. In 14, the social history, before admission to hospital, was known, and was apparently satisfactory in 10, but half of these patients were in the thin group. As elderly people often eat little and capriciously, it is possible that deficient protein intake was present even in those with a satisfactory social history. Two of our patients were admitted in a neglected state, with anæmia and hypo-albuminæmia, and two others had lived alone or with equally elderly relatives. In 2 patients, anæmia was apparently due to rheumatoid arthritis, but these were the only instances in which any disease known to be associated with amyloidosis was present. The pattern of amyloidosis in these patients was the same as in the other 19 typical, senile cardiac amyloidoses, and was not that of secondary amyloidosis.

The aetiology of senile cardiac amyloidosis is as obscure as in other forms of amyloidosis. Similar findings in other organs have been noted in aged dogs, cattle, baboons, and hamsters, and are known to occur spontaneously in certain strains of mice, which are susceptible to experimental induction of amyloid (Thung, 1957). In these mice the experimentally induced amyloidosis is regarded as a precocious variety of the senile form, and Thung suggests that amyloidosis in man may be a comparable condition, and the primary amyloidosis of middle age a pre-senile form of the senile cardiac amyloidosis described in this paper. In mice it is known that genetics and diet play a part in the development of this condition, and it is possible that diet is implicated in the human form. Genetically determined forms of amyloid are now well documented (Gafni, Sohar, and Heller, 1964), and Gafni *et al.* consider that many cases of idiopathic primary amyloidosis are likely to be sporadic examples of inherited types. It is possible, therefore, that senile cardiac amyloidosis

is also genetically determined, and will develop eventually in some families, if sufficiently long-lived; it may be accelerated by malnutrition, and may become manifest as "typical" amyloidosis at a much younger age, in response to factors that are as yet unknown. The main purpose of this paper is to emphasize that the apparently rare condition of amyloidosis is commonly found in the hearts of the elderly, in whom it is not infrequently associated with congestive failure. Investigation of possible ætiological and genetic factors in these patients may usefully contribute to an understanding of the nature of amyloidosis as a whole.

#### SUMMARY

Amyloid deposition, almost entirely localized to the heart, is common in the elderly. Twenty-one patients are described. Senile cardiac amyloid was found at necropsy in 10 per cent of patients over 80, and 50 per cent of those over 90, in a recent survey of 16 months. Congestive cardiac failure was present in over half the cases, and apparently due entirely to the amyloidosis in 5. No constant or characteristic clinical or cardiographic features were found and the diagnosis could only be made at necropsy, when small nodules of amyloid were visible in the atrial endocardium in patients with significant cardiac involvement. Four patients showed digitalis sensitivity. These findings are compared with those from other countries, and the possible role of genetic and nutritional factors in the pathogenesis briefly discussed. In view of the high incidence of senile cardiac amyloidosis, the proportion of patients with cardiac failure, and the possibility of digitalis sensitivity, this malady should be considered in the differential diagnosis of any elderly patient in congestive cardiac failure.

I should like to thank the physicians and surgeons of Central Middlesex Hospital, particularly Dr. A. D. Abdullah, Dr. R. J. Porter, Mr. T. G. I. James, Mr. F. A. Henley, and Mr. J. W. P. Gummer, for permission to include patients under their care, and Dr. K. P. Ball who kindly reviewed the electrocardiograms. I am grateful to Dr. R. A. B. Drury for his continued support and provision of laboratory facilities, the staff of the Central Middlesex Hospital Histopathology Department for the very considerable amount of technical work involved, and Mr. A. Booker and Mr. F. Warren for the photography. I am indebted to the North-West Metropolitan Regional Hospital Board Clinical Research Fund for financial support.

#### REFERENCES

- Briggs, G. W. (1961). Amyloidosis. *Ann. intern. Med.*, **55**, 943.
- Budd, J. W. (1934). Primary amyloid disease of the heart. Report of a case. *Amer. J. Path.*, **10**, 299.
- Buerger, L., and Braunstein, H. (1960). Senile cardiac amyloidosis. *Amer. J. Med.*, **28**, 357.
- Cassidy, J. T. (1961). Cardiac amyloidosis. Two cases with digitalis sensitivity. *Ann. intern. Med.*, **55**, 989.
- Dahlin, D. C. (1949). Primary amyloidosis, with report of six cases. *Amer. J. Path.*, **25**, 105.
- , and Edwards, J. E. (1949). Cardiac Clinics. CXXVI. Amyloid localized in the heart. *Proc. Mayo Clin.*, **24**, 89.
- Delarue, J., Chomette, G., Ganter, P., Pinaudeau, Y. (1963). Les paramyloidoses primitives: L'amylose cardiaque sénile. *Ann. Anat. path.*, **8**, 27.
- Eliot, R. S., McGee, H. J., and Blount, S. G. (1961). Cardiac amyloidosis. *Circulation*, **23**, 613.
- Gafni, J., Sohar, E., and Heller, H. (1964). The inherited amyloidoses: their clinical and theoretical significance. *Lancet*, **1**, 71.
- Hüsselmann, H. (1955). Beitrag zum Amyloidproblem auf Grund von Untersuchungen an menschlichen Herzen. *Virchows Arch. path. Anat.*, **327**, 607.
- Josselson, A. J., Pruitt, R. D., and Edwards, J. E. (1952). Amyloid localized to the heart. Analysis of 29 cases. *Arch. Path.*, **54**, 359.
- King, L. S. (1948). Atypical amyloid disease, with observations on a new silver stain for amyloid. *Amer. J. Path.*, **24**, 1095.
- Lee, H. Y., and Kaufmann, W. (1957). Cardiac amyloidosis in the aged. *Arch. Path.*, **64**, 494.
- McKeown, F. (1963). Heart disease in old age. *J. clin. Path.*, **16**, 532.
- Mulligan, R. M. (1958). Amyloidosis of the heart. *Arch. Path.*, **65**, 615.
- Pomerance, A. (1965). Pathology of the heart with and without cardiac failure in the aged. *Brit. Heart J.*, **27**, 697.
- Ranström, S. (1946). Amyloidosis myocardii. *Acta med. scand.*, **123**, 111.
- Soyka, J. (1876). Ueber amyloide Degeneration. *Prag. med. Wschr.*, **1**, 165.
- Symmers, W. St. C. (1956). Primary amyloidosis: a review. *J. clin. Path.*, **9**, 187.
- Thung, P. J. (1957). The relation between amyloid and ageing in comparative pathology. *Gerontologia (Basel)*, **1**, 234.