

# Management of spontaneous pneumothorax using a Heimlich flutter valve

A. BERNSTEIN, M. WAQARUDDIN, and M. SHAH

*Department of Thoracic Medicine, Hope Hospital, Salford, M6 8HD*

Intrapleural evacuation of air was achieved with a Heimlich flutter (non-return) valve in 16 patients with a total of 18 pneumothoraces, 17 of which were spontaneous. Complete lung expansion occurred in 17 (94.4%) of these episodes by five days, and 12 (66%) showed full expansion within one hour. Valve blockage occurred in one patient whose pneumothorax was associated with exudation through the intrapleural catheter and standard under water drainage is recommended in this situation or where there is effusion.

The flutter valve precludes the need for the cumbersome apparatus of under water seal drainage and therefore avoids the well-known possible dangers of connecting an intrapleural catheter to a water trap. Another advantage is the immediate mobility of the patient.

Those who advocate active therapy in spontaneous pneumothorax most commonly utilize tube thoracotomy initially, i.e., the insertion of an intrapleural catheter which is subsequently connected to an under water seal bottle.

This paper discusses an alternative approach to the cumbersome under water drainage system, i.e., the use of a small valve which allows for one way drainage of air from the pleural cavity.

**TECHNIQUE** The procedure is carried out in the ward, usually with the patient recumbent in bed. With strict asepsis and local anaesthesia, an intercostal tube is inserted in the second anterior interspace providing that the lung is not adherent at this site. We have used an Argyll trocar catheter, size 20 Fr. (Fig. 1) and, after insertion a Heimlich valve is attached to the external end of the catheter.

The Heimlich valve (Fig. 2) is essentially a flutter valve consisting of a single piece of rubber tubing enclosed in a hard transparent plastic case which is

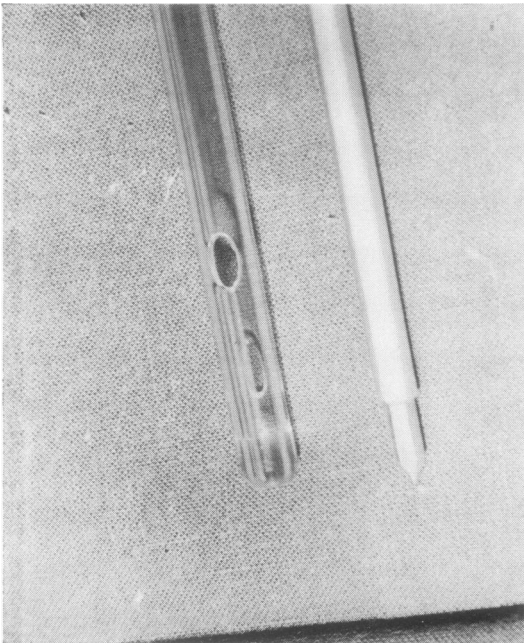


FIG. 1. Argyll trocar catheter, distal end.

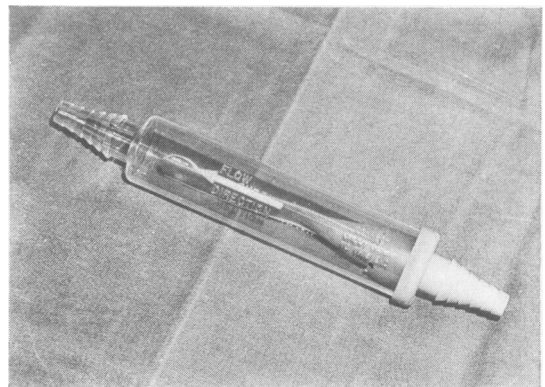


FIG. 2. Heimlich valve.

tapered and ridged at either end. One end of the enclosed rubber tubing is compressed so that the two flat sides remain in contact with each other, preventing reflux but allowing escape of air. The proximal ridged end is coloured blue and an arrow, clearly indicating the direction of flow, is embossed on the casing. The whole valve is 17.5 cm in length and weighs 22.5 grammes.

In all patients there was an immediate egress of air on release of the Spencer Wells forceps. This was noted by an easily visible separation of the ends of the rubber tubing, and a sound not unlike a 'raspberry' was usually heard.

The area around the tube insertion is further sealed with Vaseline gauze and adhesive tape. The connection between catheter and valve is similarly sealed. The valve is attached to the chest wall, ensuring that the distal end is unimpeded (Fig. 3).



FIG. 3. Patient immediately after completion of procedure.

The patient is encouraged to breathe deeply and cough intermittently for the next hour. This usually promotes further egress of air which can be both seen and heard as described above. Full expansion of the lung is indicated by absence of flutter. After one hour a postero-anterior film in full expiration is performed, the patient being ambulant at this time.

#### FURTHER ROUTINE

1. Ampicillin, in a dose of 500 mg six-hourly by mouth, is given for the duration of intubation and for a further two days.
2. Daily chest radiographs are taken in full expiration.
3. On the fifth day following intubation, assuming full expansion is achieved, the catheter is clamped proximal to the Heimlich valve. A further radiograph is performed after two to four hours. If the lung has remained fully expanded, the catheter is removed, the patient holding breath in forced expiration, and the opening is sealed. Because of the experimental nature of the procedure all patients were observed in hospital for a further seven days.
4. Patients whose lungs failed to expand or did so only minimally were immediately changed to an under water seal drainage system.
5. Those patients whose pneumothoraces were complicated by exudation or effusion were also transferred to under water seal drainage.

#### PATIENTS

In the period March 1971 to August 1972, 25 patients with pneumothorax were seen. Apart from one pneumothorax as a result of pleural biopsy, all were spontaneous. Five patients needed no drainage procedures and three were treated only with under water seal drainage. The remaining 16 patients were treated by Heimlich valve and they comprise the present series.

There were 13 male and three female patients with an average age of 42.6 years, ranging from 15 to 74 years. There were 18 episodes of pneumothorax, 11 on the right side and seven on the left, two patients each having had a single ipsilateral recurrence re-treated by Heimlich valve drainage. Eleven patients had no previous history of chest disease, four had chronic bronchitis, and one of these had an additional, past history of pulmonary tuberculosis. One patient had had a previous pneumothorax on the same side and in one patient the pneumothorax complicated a pleural biopsy performed with an Abram's needle. The onset of pain and/or dyspnoea varied from one hour to one month prior to intubation.

#### RESULTS

Of the 18 episodes of pneumothorax 17 (94.4%) had fully expanded within five days of intubation. Twelve of these (66%) showed full expansion on the one-hour postero-anterior film taken in full expiration. One patient failed to respond to both Heimlich valve and under water seal drainage and a large apical bulla was found subsequently at thoracotomy. Exudation led to

blockage of the valve and re-collapse on the fourth day in another patient, but substitution with under water seal drainage was followed by complete re-expansion. In a third patient, although the lung remained fully expanded, it was decided to change the drainage because of the risk of valve blockage by pleural effusion.

During the period of the study there were two recurrences (11%). In each case, pleurectomy and ligation of apical bullae were performed.

#### DISCUSSION

Our approach to the management of pneumothorax parallels the active regime suggested by Ruckley and McCormack (1966). We initially made a rough calculation of the percentage decrease in lung volume using the method of Kircher and Swartzel (1954). Tube thoracotomy was indicated in the following circumstances: (a) pneumothorax causing reduction of lung volume by 50% or more (Briggs, Walters, and Byron, 1953; Leading article, *British Medical Journal*, 1968); (b) pneumothorax causing significant dyspnoea, especially in those patients with poor pulmonary reserve; (c) pneumothorax which, though initially small, is seen to be increasing in size. A five-day period of intubation was decided on in the hope that by the end of this time the irritation produced by the tube may have produced some pleural adhesion, thereby helping to prevent recurrence.

The standard under water drainage system has several drawbacks (Heimlich, 1965), the most important of which are a compulsory delay of ambulation during the period of intubation and the ever present dangers of bottle elevation or breakage. There is a frequent lack of understanding of the system by nursing and other staff and finally there is the time needed to clean and sterilize bottle and tubing. However, in spite of these disadvantages, it has been the most popular method of therapy by those who favour an active approach to the treatment of spontaneous pneumothorax, either alone (Briggs *et al.*, 1953) or combined with intrapleural suction (Kreutzer, Brizzolara, and Rogers, 1952; Klassen and Meckstroth, 1962; Wolcott, Shaver, and Jennings, 1963).

The idea of a valve drainage system is not a new one. Fuld (1944) described an emergency procedure for use in pneumothorax on the battlefield, utilizing an inverted air inlet valve from a transfusion set. A well-recognized emergency method of treating tension pneumothorax is the

insertion of an intrapleural needle and tying a punctured rubber glove finger over the needle butt (Birch, 1967). Knight (1967) described a simple pneumothorax valve using a ball valve principle which has unfortunately fallen into dis-favour because of frequent blockage.

The Heimlich valve was originally described (Heimlich, 1965) for use as a drainage procedure avoiding the need for intrapleural suction after thoracotomy. It has the advantages of pre-sterilization and is cheap enough to be disposable. It allows for immediate ambulation of the patient and is easily understood by all staff since egress of air may be both seen and heard. Negative pressure or under water suction may be applied to its distal end. An obvious further application of this valve is its use over a long-term period in those patients with persistent pneumothorax whose poor pulmonary reserve excludes a surgical approach.

Sargent and Turner (1970), in describing a catheter technique for use in pneumothorax following needle lung biopsy, have found the routine use of the Heimlich valve satisfactory. In some cases, however, they found it necessary to apply negative pressure to the valve. Boylen (1972) has had good results in a similar situation.

The main disadvantage associated with this valve is in those situations where pneumothorax is associated with exudate or effusion through the tube. We found, in contrast to Heimlich, that the valve leaves tend to adhere in these situations, leading to blockage of the outward flow of air. This usually necessitated a change of valve and led to substitution of under water drainage in one patient. Obviously extreme care should be used in ensuring that all connections are secure and airtight.

The fact that as many as 66% of our patients showed complete expansion in one hour suggests that a pressure higher than atmospheric exists in the pleural cavity in spontaneous pneumothorax more commonly than is generally thought. Intrapleural pressure also exceeds atmospheric pressure during expiration and coughing, and this could easily be seen by observation of the valve leaves.

All five patients whose pneumothoraces failed to expand completely within one hour showed only minimal collapse at that time. In three patients who showed full expansion at one hour, a minimal re-collapse was seen over the next 72 hours. This was presumably related to leakage in the system in spite of our precautions or because the rate of pleural evacuation was slightly exceeded by continuing air leak from the lung.

REFERENCES

- Birch, C. A. (1967). *Emergencies in Medical Practice*, 8th ed., p. 164. Livingstone, London and Edinburgh.
- Boylen, C. T. (1972). Personal communication.
- Briggs, J. N., Walters, R. W., and Byron, F. X. (1953). Spontaneous pneumothorax. *Dis. Chest*, **24**, 564.
- Fuld, H. (1944). Simple device for control of tension pneumothorax. *Brit. med. J.*, **2**, 503.
- Heimlich, H. J. (1965). Heimlich flutter valve: effective replacement for drainage bottle. *Hosp. Topics*, **43**, 122.
- Kircher, L. T., and Swartzel, R. L. (1954). Spontaneous pneumothorax and its treatment. *J. Amer. med. Ass.*, **155**, 24.
- Klassen, K. P., and Meckstroth, C. V. (1962). Treatment of spontaneous pneumothorax. *J. Amer. med. Ass.*, **182**, 1.
- Knight, R. K. (1967). A pneumothorax valve. *Lancet*, **1**, 190.
- Kreutzer, F. L., Brizzolara, L. G., and Rogers, W. L. (1952). Treatment of spontaneous pneumothorax by means of continuous intrapleural suction. *Dis. Chest.*, **21**, 663.
- Leading article (1968). Spontaneous pneumothorax. *Brit. med. J.*, **1**, 720.
- Ruckley, C. V., and McCormack, R. J. M. (1966). Management of spontaneous pneumothorax. *Thorax*, **21**, 139.
- Sargent, E. N., and Turner, A. Franklin (1970). Emergency treatment of pneumothorax. *Amer. J. Roentgenol.*, **109**, 531.
- Wolcott, M. W., Shaver, W. A., and Jennings, W. D. (1963). Spontaneous pneumothorax—management by tube thoracostomy and suction. *Dis. Chest*, **43**, 78.