

Adenocarcinoma in the columnar epithelial lined lower (Barrett) oesophagus

ANTHONY HAWE, W. SPENCER PAYNE, LOUIS H. WEILAND,
and ROBERT S. FONTANA

Mayo Clinic and Mayo Foundation, Rochester, Minnesota, U.S.A.

Hawe, A., Payne, W. S., Weiland, L. H., and Fontana, R. S. (1973). *Thorax*, 28, 511-514. **Adenocarcinoma in the columnar epithelial lined lower (Barrett) oesophagus.** At the Mayo Clinic, five patients with Barrett oesophagus developed adenocarcinoma of the oesophagus at sites cephalad from the anatomic cardia but separated from it by a definite segment of columnar lined oesophagus. Twelve similar cases have been reported in the literature, including one from this institution. Of 85 Mayo Clinic patients in whom a clinical diagnosis of benign Barrett oesophagus was made in the 20-year period 1950-69, two subsequently developed oesophageal cancer. Since its description in 1950 by Barrett, the columnar epithelial lined lower oesophagus has been encountered with increasing frequency. The full clinical implications of this unusual condition are only partially appreciated at this time, and the present report, as well as previous ones, suggest that the condition may be premalignant.

Barrett oesophagus is an unusual condition (Barrett, 1950; Allison and Johnstone, 1953), and carcinoma of the oesophagus arising within its columnar epithelium is distinctly rare. The present report concerns our experience with five cases of adenocarcinoma in Barrett oesophagus in which the lesion was surgically resected.

MATERIAL AND METHODS

Case histories of 360 patients who had undergone resection for carcinoma of the oesophagus (exclusive of the cardia) at the Mayo Clinic in the 12-year period 1960-71 were reviewed. Five of these patients had an adenocarcinoma arising in a Barrett oesophagus. In each instance, the tumour was distinctly separated from the anatomic cardia by a segment of columnar-lined oesophagus (carcinomas that arose at the cardia with columnar-lined oesophagus above it were considered gastric carcinomas and were excluded from the study). In all five patients, the specimen of oesophagus was re-examined, and the characteristic features were reconfirmed both grossly and microscopically.

FINDINGS

CLINICAL FEATURES AND COURSE Four of the patients were males and one was a female. The average age at diagnosis and resection was 56 years, with a range of 39 to 75 years (Table). All

TABLE
DOCUMENTED REPORTED CASES OF CARCINOMA OF THE OESOPHAGUS ASSOCIATED WITH A COLUMNAR EPITHELIAL LINED LOWER OESOPHAGUS (BARRETT OESOPHAGUS)

Year	Author	Patient		Carcinoma		
		Age (yr)	Sex	Location	Type	Resected
1952	Morson and Belcher	56	M	Mid	Adeno	Yes
1954	Thomas and Hay	66	M	Mid	Adeno	Yes
1955	Pattinson <i>et al.</i>	66	F	Mid	Adeno	No
1955	McCorkle and Blades	34	M	Mid	Adeno	Yes
1956	Smithers	40	M	Mid	Adeno	No
1959	Armstrong <i>et al.</i>	55	M	Mid	Adeno	Yes
1963	Adler	—	—	Cardia	Adeno	Yes
1966	Raphael <i>et al.</i>	70	F	Mid	Adeno	Yes
1970	Burns <i>et al.</i>	47	M	Mid	Adeno	No
1970	Burns <i>et al.</i>	52	M	Mid	Adeno	No
1971	Tamura and Schulman	53	M	Mid	Squamous	Yes
1971	Shafer	62	M	Lower	Adeno	Yes
1972	Present study	57	M	Mid	Adeno	Yes
		39	M	Lower	Adeno	Yes
		42	M	Mid	Adeno	Yes
		66	M	Lower	Adeno	Yes
		75	F	Lower	Adeno	Yes

but one of the patients had histories of long-standing oesophageal difficulty (5 to 40 years) antedating the more recent progressive obstructive symptoms of oesophageal cancer. The chronic symptoms were due to gastro-oesophageal incompetence and consisted of recurrent postural regurgi-

tation, postprandial and nocturnal pyrosis, and epigastric pain with interscapular radiation. Three patients had previously been suspected of having Barrett oesophagus with stricture and had gained relief 1, 4, and 7 years previously by oesophageal dilatation. Symptoms of progressive oesophageal obstruction varied from six months to one year prior to diagnosis. All patients experienced loss of weight (8 to 40 lb ; 3.6 to 18.0 kg). One patient had haematemesis.

Radiographic examination of the oesophagus revealed a stricture in the mid oesophagus in three patients and at the junction of the middle and lower thirds in two patients. In four patients, the stricture was suggestive of a malignancy. On fluoroscopic study all patients had typical oesophageal motility below the stricture. A co-existing sliding hiatal hernia was apparent in all five patients.

All patients underwent oesophagoscopy examination. Adenocarcinoma was confirmed by biopsy. The degree of obstruction precluded examination of the distal oesophagus or study of oesophageal motility and mucosal electric potentials.

All patients had resectable lesions, and all survived operation without complications. Two patients died of recurrent carcinoma two and five years after operation. The others were alive at follow-up 3, 8, and 18 months after resection.

PATHOLOGICAL FEATURES The resected specimens contained ulcerated adenocarcinoma that varied from 1 cm to 7 cm in greatest dimension. Each of the tumours arose above the cardia with intervening gastric mucosa (Fig. 1). In three patients, the tumour was located below the upper limit of the columnar-lined oesophagus, and in two, the tumour involved the squamocolumnar junction.

Microscopically (Fig. 2), all five adenocarcinomas had moderate to poor differentiation. By Broders' classification, two lesions were grade 2, two were grade 3, and one was grade 4. All were infiltrative and had various amounts of desmoplastic reaction. In these respects they were similar to gastric carcinomas. Regional lymph nodes were metastatically involved in four of the five patients.

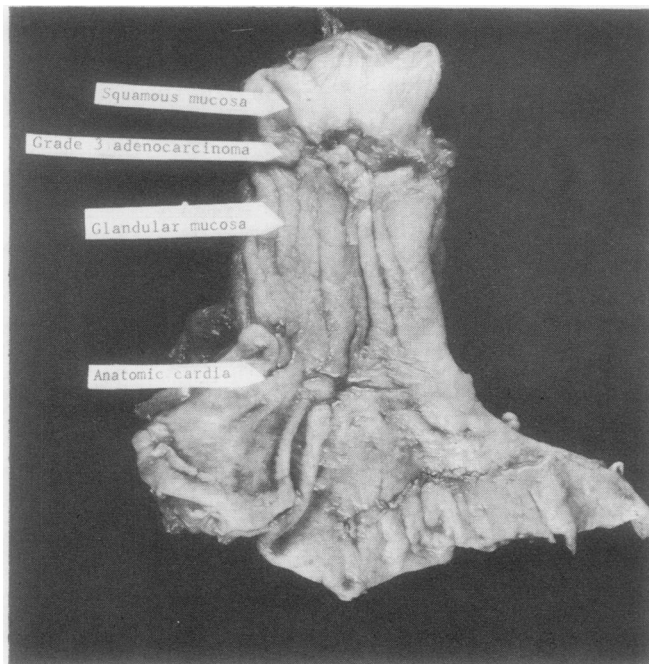


FIG. 1. Gross specimen showing relatively small ulcerated carcinoma situated 5 cm above the anatomic cardia. Mucous membrane above tumour is squamous tissue and that below is glandular tissue.

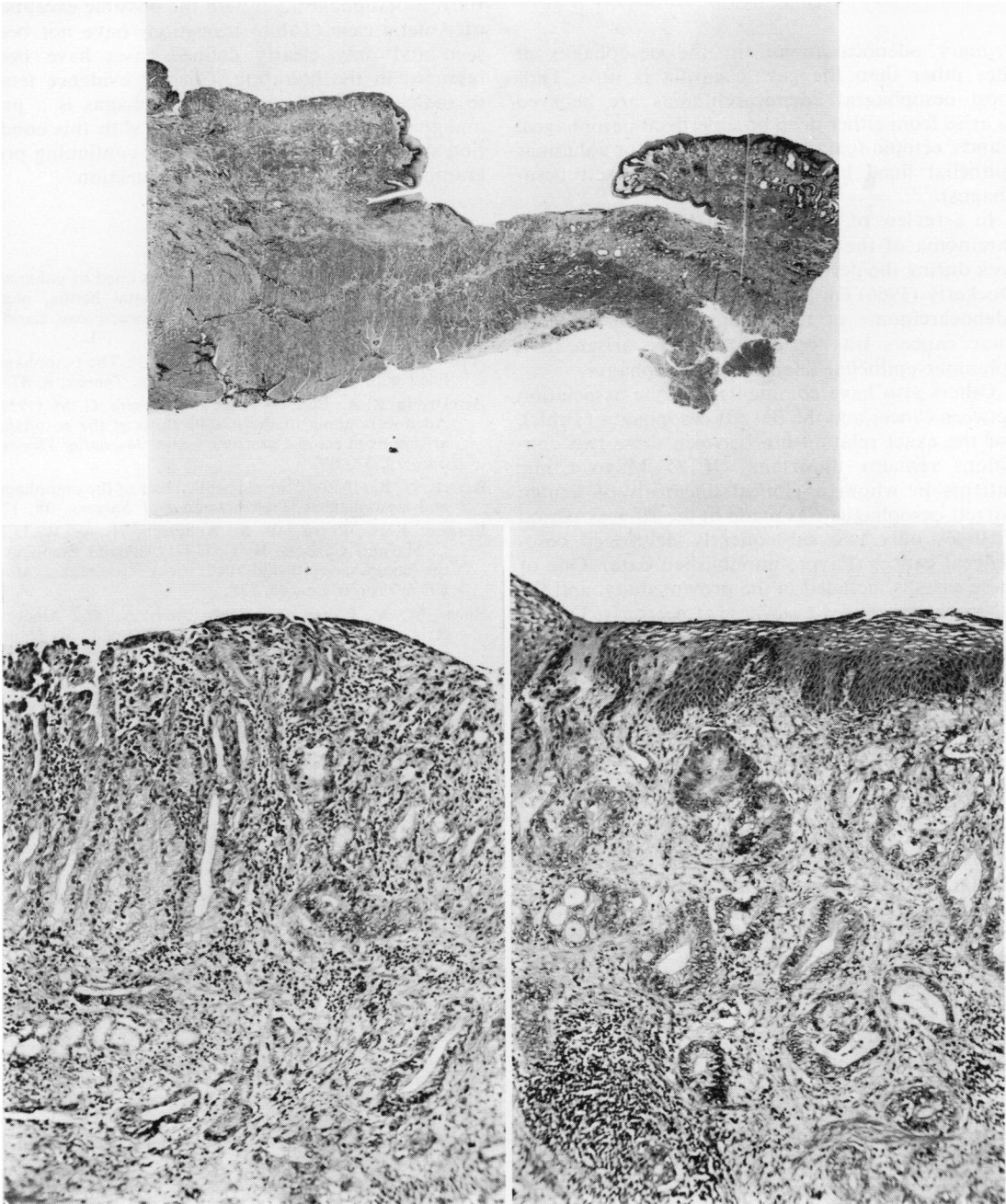


FIG. 2. (Top) *Ulcerated, undermining adenocarcinoma infiltrating into oesophageal muscle. Both edges of ulcer show partial squamous lining but surface epithelium on left is columnar. (Haematoxylin and eosin $\times 5$).* (Lower left) *Infiltrating adenocarcinoma in depth of benign gastric type mucosa (taken from left edge of ulcer shown above). (Haematoxylin and eosin $\times 90$).* (Lower right) *Infiltrating adenocarcinoma with overlying benign squamous epithelium (taken from right edge of ulcer shown above). (Haematoxylin and eosin $\times 90$).*

DISCUSSION

Primary adenocarcinoma in the oesophagus at sites other than the gastric cardia is rare. Thus most oesophageal adenocarcinomas are believed to arise from either deep or superficial oesophageal glands, ectopic foci of gastric mucosa, or columnar epithelial lined lower oesophagus (Barrett oesophagus).

In a review of 1,312 Mayo Clinic patients with carcinoma of the oesophagus or cardia who were seen during the period 1946-63, Raphael, Ellis, and Dockerty (1966) encountered only 10 patients with adenocarcinoma of the oesophagus. Only one of these cancers was believed to have arisen in a columnar epithelial lined lower oesophagus.

Others also have commented on the association between cancer and the Barrett oesophagus (Table), but the exact relationship between these two conditions remains uncertain. Of 85 Mayo Clinic patients in whom a clinical diagnosis of benign Barrett oesophagus was made in the 20-year period 1950-69, only two subsequently developed oesophageal cancer (Payne, unpublished data). One of these cases is included in the present study, and the other was diagnosed elsewhere at necropsy. During this same period five additional patients have been seen at the Mayo Clinic in whom both conditions were diagnosed simultaneously (Raphael *et al.*, 1966; this study).

The association of carcinoma of the oesophagus and cardia with chronic oesophageal disease has been recognized for many years. Unfortunately, the Barrett oesophagus is not as clearly definable a clinical entity as achalasia, diverticulum, web, lye stricture of the oesophagus, tylosis palmaris et plantaris, or Plummer-Vinson (Paterson-Kelly) syndrome, all of which have been implicated as having an increased incidence of cancer of the oesophagus.

Although Burgess *et al.* (1971) have recently outlined the essential features of the Barrett oesophagus, subclinical stages of the condition undoubtedly exist which would be difficult to delineate by available methods. Moreover, the association of Barrett oesophagus with diaphragmatic hernia, gastro-oesophageal incompetence, and reflux oesophagitis has led to speculation that the association between diaphragmatic hernia and cancer of the oesophagus and cardia may be more frequently related to the development of a columnar epithelial lined lower oesophagus than is generally appreciated (Michel, Olsen, and Dockerty, 1967; Grimes and Zboralske, 1968). The development of carcinoma might destroy the evidence of a pre-existing

Barrett oesophagus, yet with the possible exception of Adler's case (Table) transitions have not been seen and only clearly defined cases have been reported in the literature. Current evidence tends to indicate that the Barrett oesophagus is a pre-malignant condition, and patients with this condition should be advised to pursue a continuing programme of oesophageal cancer detection.

REFERENCES

- Adler, R. H. (1963). The lower esophagus lined by columnar epithelium: its association with hiatal hernia, ulcer, stricture, and tumor. *Journal of Thoracic and Cardiovascular Surgery*, **45**, 13.
- Allison, P. R., and Johnstone, A. S. (1953). The oesophagus lined with gastric mucous membrane. *Thorax*, **8**, 87.
- Armstrong, R. A., Blalock, J. B., and Carrera, G. M. (1959). Adenocarcinoma of the middle third of the esophagus arising from ectopic gastric mucosa. *Journal of Thoracic Surgery*, **37**, 398.
- Barrett, N. R. (1950). Chronic peptic ulcer of the oesophagus and 'oesophagitis'. *British Journal of Surgery*, **38**, 175.
- Burgess, J. N., Payne, W. S., Andersen, H. A., Weiland, L. H., and Carlson, H. C. (1971). Barrett esophagus: the columnar-epithelial-lined lower esophagus. *Mayo Clinic Proceedings*, **46**, 728.
- Burns, W. A., Flores, P. A., Moshyedi, A., and Albecete, R. A. (1970). Clinical conditions associated with columnar lined esophagus. *American Journal of Digestive Diseases*, **15**, 607.
- Grimes, O. F., and Zboralske, F. F. (1968). Carcinoma in association with hiatal hernia. *Journal of Thoracic and Cardiovascular Surgery*, **55**, 30.
- McCorkle, R. C., and Blades, B. (1955). Adenocarcinoma of the esophagus arising in aberrant gastric mucosa. *American Surgeon*, **21**, 781.
- Michel, J. O., Olsen, A. M., and Dockerty, M. B. (1967). The association of diaphragmatic hiatal hernia and gastroesophageal carcinoma. *Surgery, Gynecology and Obstetrics*, **124**, 583.
- Morson, B. C., and Belcher, J. R. (1952). Adenocarcinoma of the oesophagus and ectopic gastric mucosa. *British Journal of Cancer*, **6**, 127.
- Pattinson, J. N., Osborne, G., and Morson, B. C. (1955). Hiatus hernia with adenocarcinoma arising in the region of the cardia. *Journal of the Faculty of Radiologists*, **7**, 90.
- Payne, W. S. Unpublished data.
- Raphael, H. A., Ellis, F. H., Jr., and Dockerty, M. B. (1966). Primary adenocarcinoma of the esophagus: 18-year review and review of literature. *Annals of Surgery*, **164**, 785.
- Shafer, R. B. (1971). Adenocarcinoma in Barrett's columnar-lined esophagus. *Archives of Surgery*, **103**, 411.
- Smithers, D. W. (1956). Adenocarcinoma of the oesophagus. *Thorax*, **11**, 257.
- Tamura, H., and Schulman, S. A. (1971). Barrett-type esophagus associated with squamous carcinoma. *Chest*, **59**, 330.
- Thomas, J. V., and Hay, L. J. (1954). Adenocarcinoma of the esophagus: report of a case of glandular metaplasia of the esophageal mucosa. *Surgery*, **35**, 635.