

## Second primary lung carcinoma

R. ABBEY SMITH, B. K. NIGAM,  
and JOAN M. THOMPSON<sup>1</sup>

*Cardiothoracic Unit, Walsgrave Hospital, Coventry, and Department of Statistics<sup>1</sup>  
West Midlands Regional Health Authority, Edgbaston, Birmingham*

**Abbey Smith, R., Nigam, B. K., and Thompson, Joan M. (1976).** *Thorax*, 31, 507–516. **Second primary lung carcinoma.** Fifty-five patients suffering from second primary lung carcinoma, 10 synchronous and 45 after resection for lung carcinoma (metachronous), have been observed from 1400 resections. The first manifestation of a second carcinoma in this series has always been the appearance of a new shadow in the follow-up radiograph. In our experience, second primary lung carcinoma is a disease affecting only heavy cigarette smokers. Heavy cigarette smokers suffering from squamous-cell carcinoma are at special risk. The results of re-operation, the significance of the time interval between the original operation and the appearance of the second primary carcinoma, and the slow growth rate of some second primaries are briefly discussed. No clear-cut methods exist for distinguishing a second primary from a metastasis from the original carcinoma.

In discussing second primary lung carcinoma, the main difficulty is definition. The arguments for and against considering a new shadow in a patient's follow-up chest radiograph, after resection for lung carcinoma as a second primary, have continued since Warren and Gates' (1932) report and the surgical reports of Robinson and Jackson (1958), Hughes and Blades (1961), and le Gal and Bauer (1961).

From a study of radiographic changes no one can distinguish extension or metastasis from the first carcinoma from a fresh primary lung carcinoma. The histopathological features of the fresh lesion are not available at the time the new radiological shadow first appears. A second operation, leading to histopathological diagnosis of the new lesion, is possible in less than one-third of patients who develop a second primary after resection—17 patients re-operated on from 55 in our series; 10 from 41 in the series of Shields and Robinette (1973), and 12 from 34 in the report of Razzuk *et al.* (1974).

Necropsy findings in a patient who develops a fresh lesion, which is inoperable and, by extending, causes the patient's death, are equivocal. Metastases at necropsy may be due to either the original or a fresh lesion. Auerbach *et al.* (1967) described the difficulty in confirming independent

primary lesions at necropsy. In Chaudhuri's (1971) view, a fresh lesion can be established as a second primary carcinoma only if the histopathological features of the original and new carcinomas are different. Struve-Christensen (1971) emphasizes the importance of clinical factors in differentiating a metastasis from a second primary. A fresh lesion may with conviction be described as a second primary if the time interval between the appearance of the original and the new lesion is long.

Microscopic multiple primary bronchial carcinomas are relatively common, and the time taken for a microscopic primary to become a clinically apparent carcinoma varies. Other things being equal, we see no overriding reason for rejecting a fresh lesion which appears within one year of resection as a second primary solely on the grounds that the time interval is short. We have excluded examples of stump recurrence of carcinoma, extension of residual carcinoma of the lung following a too conservative resection, or extension of carcinoma in hilar lymph nodes. For purposes of patient management the single shadow (and the second primaries we have seen have all presented as single shadows), which appears in the chest radiograph at variable times after resection and has the same clinical, radio-

logical, and bronchoscopic characteristics as the original tumour, we regard as a second primary lung carcinoma.

Neptune, Woods, and Overholt (1966) state . . . 'From a practical viewpoint we do not believe it makes any difference in management whether new-found disease is primary or recurrent. All such cases require careful evaluation and if the new lesion appears localized and is amenable to surgical excision, then this should be the procedure of choice'. We have followed this practice for the last 18 years.

Some may think that we have diagnosed second primary lesions too frequently, particularly when the time interval is short. Stump recurrence after resection has been excluded by bronchoscopy and slow progress of carcinoma in hilar nodes by mediastinoscopy. In local extension of the tumour the fresh shadow develops at the site of the previous resection.

These sequelae of resection may be rapidly fatal, but we have seen untreated patients survive eight years with stump recurrence, six years with increasing local hilar node involvement, and 12 years with extension locally in the lung at the resection site.

A metastasis from the original lesion is the difficult differential diagnosis. It is unusual to find extrathoracic manifestations of carcinoma at the time a second primary first shows radiologically. The long period during which the second primary seems confined to the lungs is a feature of the disease. Diffuse spread of carcinoma to both lungs after resection has an unmistakable radiological appearance.

#### PATIENTS UNDER REVIEW

Between 1953 and 1973 a second primary lung carcinoma has been diagnosed in 55 patients from a total of 1400 patients who have undergone resection. The follow-up, including twice-yearly chest radiographs of each of these 1400 patients, has, with one exception, been complete. This large number of second primaries has been revealed by the follow-up method, and their development is not due to an unusual preponderance of one cell type or exposure to carcinogen (except tobacco smoke). The time interval between the original operation and the appearance of the second primary is shown (in Table I). The means of diagnosis or presumptive diagnosis of the original tumour and the second primary are shown (Table II). The low incidence of malignant cells in the sputum may be explained by this method of

investigation not being pursued when the diagnosis seemed obvious. We do not believe that a low incidence of malignant cells in the sputum is a characteristic of multiple primary carcinomas.

Of the 55 patients who developed a second primary, six synchronous primary lesions were not operated on: 32 patients had the original operation only; 15 were operated on a second time, and two were operated on a third time. The type of original and subsequent operation is shown in Table III.

TABLE I  
TIME INTERVAL BETWEEN ORIGINAL PRIMARY AND FIRST RADIOLOGICAL APPEARANCE OF SECOND PRIMARY

Simultaneous	Time interval (years)				Total
	< 1	1-3	4-12	13+	
10	8	9	28	0	55

TABLE II  
METHOD OF DIAGNOSIS OR PRESUMPTIVE DIAGNOSIS OF ORIGINAL AND SECOND PRIMARY LUNG CARCINOMAS

	Radiological and positive bronchoscopic	Radiological and positive cells in sputum	Radiological only	Necropsy	Total
Original carcinoma	28	1	26	0	55
Second primary	17	3	31	4	55

TABLE III  
TYPE OF OPERATION

	Pneumonectomy	Lobectomy	Segmental	Total
Original operation	15	32	2	49
Second operation	0	10	5	15
Third operation	—	—	2	2

Six patients with synchronous primaries were not operated on

Specimens for histopathological examination were obtained from either the first operation, the subsequent operation, bronchial biopsy in patients not operated on a second time, or at necropsy. Sixty-eight specimens were reported as squamous-

cell carcinoma, four as adenocarcinoma, three undifferentiated, and two oat-cell carcinoma.

Confirmation of a difference in histology between the original and second primary carcinoma was obtainable in only four patients. Lymph-node invasion was present in five patients at the original operation and in three different patients at the second operation. The second primary carcinoma appeared on the contralateral side in 43 of the 55 patients. In six patients with synchronous primaries, the lesions were bilateral.

#### RESULTS OF RE-OPERATION

In each of the 15 second operations resection of the second primary was possible. Every diagnosis of a new radiological shadow was confirmed as a second primary at operation. There were no hospital deaths following re-operation; neither radiotherapy nor cytotoxic drugs were used before or after operation. No patient who had had a pneumonectomy was re-explored.

Of the 15 patients who underwent a second operation, 11 died before the end of the third postoperative year, three with third primaries, and the remainder with extension of the carcinoma. Three patients have survived between three and five years from the date of the second operation. Of these, one is alive four-and-a-half years after the second operation with a third primary present; one died from a myocardial infarct without gross evidence of carcinoma at necropsy; and the other died from a third primary. Only one patient survived for more than five years after the second operation. This patient died following resection of a primary carcinoma of the colon five-and-a-half years after a second operation on the contralateral side, and at necropsy a third primary was detected in the originally affected lung.

The two patients who underwent a third operation survived less than two years. One of these had, at approximately two-year intervals, a right middle lobectomy, a left upper lobectomy, and segmental resection of the right lower lobe and died five months after the third operation from a paraplegia of uncertain cause. An isolated microscopic fourth primary was present in the bronchial epithelium but there was no clinical or radiological evidence of its existence. The other patient had a left upper lobectomy and a local removal of tracheal carcinoma two years later, followed after 18 months by a residual left lower lobectomy. She died within a year of this third operation from extension of the carcinoma. All patients

living more than three years after re-operation had squamous-cell carcinoma and were heavy smokers. Two smoked more than 60 cigarettes daily before the first operation.

We would agree with Razzuk *et al.* (1974) that the prognosis following re-operation is grave. These authors, from a series of 12 re-operations, describe only one patient alive more than five years later. Neptune *et al.* (1966) report two patients alive more than five years after re-operation; both had a contralateral lobectomy following the original lobectomy, at intervals of 31 and 32 months. From five re-operations Struve-Christensen (1971) reported no five-year survivors.

#### DISCUSSION

**INFLUENCE OF SMOKING** A true assessment of how heavily a patient has smoked during his lifetime is extremely difficult, even by personal interview. With the shortcomings of all methods of collecting information retrospectively in mind, we carried out during 1971 a comparison between the smoking habits of patients with second primary lung carcinomas and those of a group of patients who after operation did not develop a second primary.

At the end of 1971, 39 patients with second primary lung carcinoma were interviewed, often on more than one occasion, concerning the duration and amount of cigarette smoking. If the patient had died, close relatives were interviewed. Only 39 of the total of 55 patients were investigated in this way because in nine adequate information was not available and seven developed a second primary after December 1971. The smoking habits of these 39 patients were compared with those of a larger group of 124 patients, 60 of whom had survived less than two years and 64 more than 10 years with no second primary. It had been shown that there was no significant difference in the age or smoking habits of these two groups of single primaries.

The 124 patients with single primaries included eight non-smokers and one who smoked a pipe only, while the 39 patients with multiple primaries were all smokers. However, this difference was not statistically significant. All the patients with multiple primaries smoked 10 or more cigarettes a day, while three of those with single primaries smoked less than 10 cigarettes a day, in addition to the nine non-cigarette smokers specified above. This seems to indicate that patients with multiple primaries are heavier smokers than those with

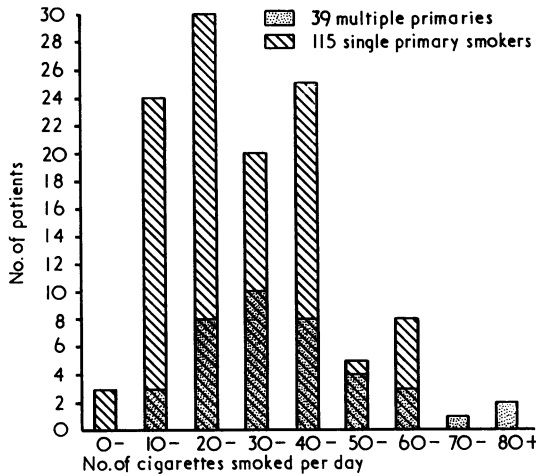


FIG. 1. See text.

single primaries. The distributions of the numbers of cigarettes smoked are illustrated in Figure 1.

The analysis in Table IV shows that there is no significant difference in the number of years smoked up to resection in the two groups, but that the multiple primaries group smoke significantly more cigarettes per day than the single primaries. The multiple primaries group smoked an average of 36 cigarettes per day up to resection compared with an average of 28 for the single primaries.

There was no significant difference between the proportions giving up smoking after resection in the two groups.

To counteract the difference in the sizes of the two groups, 39 of the single primaries group were matched for age and sex with the 39 multiple primaries and their smoking habits were again compared. These 39 smoked an average of 27 cigarettes per day, so that there was no significant difference between them and the group of 115 single primary smokers from which they were chosen. There was still a significant difference between the average number of cigarettes smoked per day by the multiple primaries group and these selected single primaries. The distributions of numbers of cigarettes smoked in the two groups are illustrated in Figure 2.

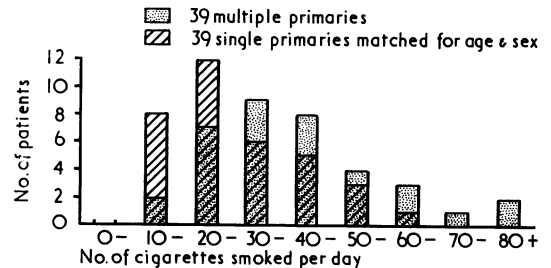


FIG. 2. See text.

Owing to the small numbers, the patients were grouped into those who had smoked less than 20, 20-49 or 50+ cigarettes per day. As one would expect, there was no significant difference between

TABLE IV  
ANALYSIS OF SINGLE AND MULTIPLE PRIMARIES

Factors	Single Primaries	Multiple Primaries	P
Age at resection (yr)	54.6 ± 8.51 (n = 124)	55.3 ± 6.94 (n = 39)	NS
Extent of operation:			
Pneumonectomy	74	11	< 0.001
Lobectomy	50	28	
Occupational dust exposure	50/124	12/39	NS
Smoking			
No of cigarettes smoked per day	28.4 ± 14.48 (n = 115) <sup>1</sup>	36.5 ± 17.58 (n = 39)	< 0.01
No of years smoked up to resection	35.1 ± 10.60 (n = 113)	35.5 ± 10.90 (n = 37)	NS
Smoking given up after resection	56/124	18/39	NS
Histology			
Oat cell	14	2 <sup>2</sup>	NS
Squamous	94	33	
Other	16	6	
Node invasion at operation	36/124	5/39	< 0.05

Data for multiple primaries refer to first primary

<sup>1</sup>8 non-smokers and 1 pipe only excluded

<sup>2</sup>2 multiple primaries included twice because of double histology - squamous and adenocarcinoma

the 39 selected single primaries and the total group of 115 single primaries ( $\chi^2=0.04$ ). The 39 patients with multiple primaries smoked significantly more cigarettes per day than the 115 patients with single primaries ( $\chi^2=7.44$ ,  $P<0.05$ ), and also more than the selected 39 patients with single primaries ( $\chi^2=5.57$ ,  $0.05<P<0.10$ ).

The part which excessive cigarette smoking appears to play in the development of a second primary has not been emphasized in some surgical reports. Auerbach *et al.* (1961) clearly described the nature and extent of changes in the bronchial epithelium from cigarette smoking. Glennie, Harvey, and Salama (1964) mention smoking in relation to multiple primary carcinoma of the bronchus. Watson (1965), discussing 56 patients surviving more than 10 years after surgery, noted that nine continued to smoke and three of these developed a new primary lung cancer. Abbey Smith (1966) stated 'Some heavy smokers with squamous cell carcinoma develop second primaries but many do not.' Each of the 15 patients of Neptune *et al.* (1966) who were re-operated on for carcinoma (not all for second primary lesions) were male cigarette smokers.

Our interest in the importance of smoking arose from the fact that, as new patients with a second primary lung carcinoma presented, it was evident from their history that each was a heavy smoker. So far we have not diagnosed a second primary carcinoma in a patient smoking less than 10 cigarettes each day.

**TIME INTERVAL BETWEEN ORIGINAL AND SECOND LUNG PRIMARY** It is necessary to differentiate three distinct time intervals—the time between the original operation and the initial radiographic appearance of the second primary, the time between operation and confirmation of the diagnosis of the same second primary, and the time between the first operation and the second operation. These three intervals may differ by as much as five or more years. The time interval between the original operation and the first radiological appearance of the second primary can be ascertained only by frequent chest radiographs. On the other hand, an abnormality may be present in the chest radiograph and the patient may not present for diagnosis for a period of several years. An exact definition of the time interval may be important. We have not seen a fresh primary appear in a patient's radiograph later than 12 years after the original operation. Twenty-five years ago it was incorrectly assumed that if a patient survived five

years from the date of operation he was unlikely to die from lung carcinoma. We now believe that it is unusual for a patient to die of lung carcinoma if the chest radiograph is normal at the end of the twelfth year after operation.

Second primaries occurring more than 12 years after resection are recorded, although it is not always clear whether the interval under consideration is the time of first radiological appearance of the new shadow, the time of final diagnosis of the second primary, the time between the original and a second operation, or the interval between the first operation and necropsy. Nor is a distinction between a fresh primary and a metastasis always made. Possible ambiguities in the time interval actually being described and also in the pathology of the second lesion must be accepted in reports of long time intervals. Brock (1964) reported 15 years between right lower and left upper lobectomy for primary tumours; Clifton, Das Gupta, and Pool (1964) 13 years between left lower lobectomy and wedge resection of the right upper lobe; Watson (1965) fresh carcinoma in 6 of 56 patients surviving resection by more than 10 years; Belcher and Anderson (1965) two patients with fresh lesions 10 and 12 years after resection; le Roux (1968) six patients surviving 9 to 12 years after pneumonectomy with fresh carcinoma; Struve-Christensen (1971) one second primary at 10 years; Chaudhuri (1971) three second primaries at 13, 11, and 10 years after resection; Shields and Robinette (1973) eight second primaries diagnosed after the tenth year from a total of 41 post-resection second primaries; and Razzuk *et al.* (1974) second primaries at 15, 14, 12, 12, and 10½ years after resection from a total of 29 patients with multiple primary carcinoma.

We have no evidence whatsoever for assuming, when the intervals exceed 12 years, that the lesion was radiologically present during or before the twelfth year. C. A. Jackson, of Harefield Hospital, one of the first to draw attention to the clinical importance of multiple primary carcinomas of the lung (Robinson and Jackson, 1958), has shown us the notes and radiographs of a patient whose chest radiograph was normal during the fifteenth year after resection and who developed a second primary carcinoma during the sixteenth year. We recollect isolated reports of even longer intervals without being able to provide references. Intervals exceeding 12 years between operation and detection of the second primary must be accepted. However, because the appearance of a fresh primary between eight and 12 years after resection is so relatively common, and after the twelfth

year so rare, some significance might be attributed to this observation. Second primary lung carcinoma accounts for about a quarter of deaths between the eighth and twelfth years after resection, but never for deaths after the twelfth year, in our series.

It could be argued that commonplace reasons for failure to diagnose a second primary after the twelfth year exist, such as the few patients who survive into and after the thirteenth year, the difficulty in obtaining frequent chest radiographs of patients of advancing years, and the fact that the survivors after the thirteenth year are those who gave up smoking after operation. Fifty-seven patients have survived 13 to 22 years after operation, and 56 of these have twice-yearly chest radiographs. In none has a second primary carcinoma been detected. Twenty-one of these 56 patients did not give up smoking after operation and four have died—one from cardiac infarction, two from cardiorespiratory failure, and one from a contralateral pneumothorax. At necropsy these patients showed no gross carcinoma. These 21 patients smoked less over a shorter period than those who developed second primaries, but they included three patients who regularly smoked 30 cigarettes each day, two patients 40 a day, one 50, and one 60 cigarettes daily since adolescence. Until the outcome is known in each of these patients the importance of not finding a second primary after 12 years must be speculative. Four patients who developed second primaries in the 8 to 12-year interval stopped smoking at the time of their original operation.

**DIFFERENCES IN RATE OF GROWTH OF SECOND PRIMARIES** The rate of growth of a second primary carcinoma is unpredictable, which makes patient management difficult. The rate of growth can be different for carcinomas of a similar cell type and is independent of the extent and nature of the first operation. Four patients from the 40 not operated on have lived more than five years after the first radiological evidence of a second primary without any treatment. Not only have they survived for five years but they have remained in sufficiently good health to continue working. The radiographs of a patient surviving more than five years were reported (Fig. 3 in Abbey Smith (1970)). Radiographs of two other patients, both heavy smokers (50+ per day) surviving more than five years without treatment, are shown (Figs 3-4).

**CASE 1.** A man aged 56 had a right upper lobectomy in 1966 for a squamous-cell tumour of the

right upper lobe (Fig. 3). In 1969 a small shadow appeared in the left upper zone (Fig. 4a). The patient remained symptom free and at work although the lesions slowly increased in size (Fig. 4b). In 1974 the small lesion in the left upper lobe was resected by segmental resection and found to be a squamous-cell carcinoma with the histopathological features of a primary. The patient was discharged from hospital on the fourteenth day and has remained well since.

**CASE 2** A man aged 57 had a right pneumonectomy for a squamous-cell carcinoma of the right main bronchus in 1968. In 1969 a small shadow was visible in the left upper lobe. No treatment was given. The patient remained symptom free and at work. In 1970 (Fig. 5a) the lesion had grown, and the radiographs in 1972 and 1973 are shown (Fig 5b and c). Figure 5d shows the radiographic appearance in 1975. The lesion continues to grow. The patient is virtually symptom free and remains at work in spite of being advised to curtail his activities. Squamous-cell carcinoma cells are present in the sputum.

These radiographs show the slow rate of growth of some second primaries and also the differences in the size reached by a second primary during the same time interval. It is not possible to compare the rates of growth of a first with a second primary because the first primary is resected, if operable, as soon as the radiological shadow appears. It is, of course, well known that some carcinomas grow slowly (Abbey Smith, 1954); our impression is that a second primary is more likely to grow slowly than the first primary. These case reports show how silently the second primary may progress and illustrate how a second primary first diagnosed 15 years after operation may have been present at 12 years or even earlier and not recognized, unless regular chest radiographs are taken.

We have not seen a patient with a second primary appearing more than eight years after operation survive for five years. An explanation that when the time interval is long the patient will be older, and more likely to die from cardiorespiratory complications, is not wholly convincing.

Whether to treat a second primary lesion actively is a difficult decision. A slow rate of growth is not to be depended upon. Exploration should be advised for any patient whose chest radiograph shows a new shadow 1 cm or more in diameter which has been present over a period of one month, if the general condition of the patient is satisfactory. A persistent single new shadow in

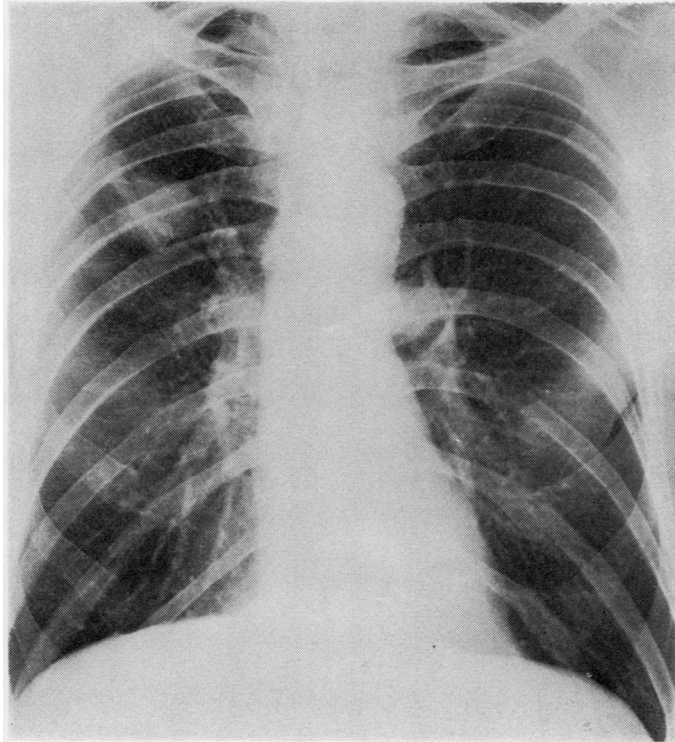


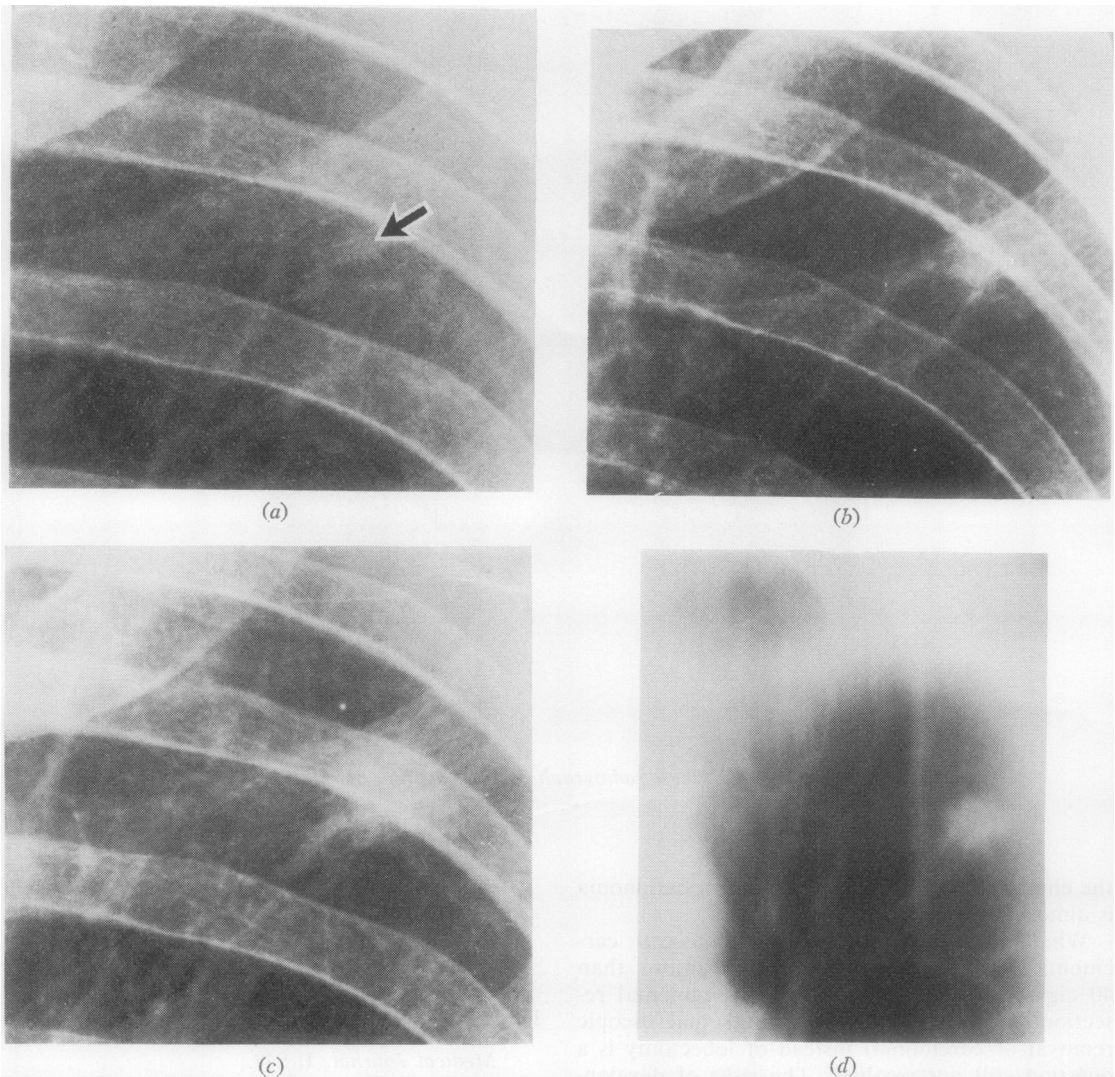
FIG. 3. Case 1. Chest radiograph in 1966 at time of right upper lobectomy.

the chest radiograph after resection for carcinoma is almost invariably malignant.

Whether a patient with squamous-cell carcinoma who has regularly smoked more than 40 cigarettes a day should have a segmental resection (when this achieves total macroscopic removal of carcinoma) instead of lobectomy is a question still not resolved. The risks of development of a second primary lesion must be set against the risks of local recurrence of tumour from an inadequate local resection.

#### REFERENCES

- Abbey Smith, R. (1954). Long survival in untreated lung carcinoma. *British Journal of Tuberculosis and Diseases of the Chest*, **48**, 311.
- (1966). Development and treatment of fresh lung carcinoma after successful lobectomy. *Thorax*, **21**, 1.
- (1970). Long-term clinical follow-up after operation for lung carcinoma. *Thorax*, **25**, 62.
- Auerbach, O., Stout, A. P., Hammond, E. C., and Garfinkel, L. (1961). Changes in bronchial epithelium in relation to cigarette smoking in relation to lung cancer. *New England Journal of Medicine*, **265**, 253.
- , —, —, and — (1967). Multiple primary bronchial carcinomas. *Cancer*, **20**, 699.
- Belcher, J. R. and Anderson, R. (1965). Surgical treatment of carcinoma of the bronchus. *British Medical Journal*, **1**, 948.
- Brock, Sir Russell, C. (1964). Thoracic surgery and the long term results of operation for bronchial carcinoma. *Annals of the Royal College of Surgeons of England*, **35**, 195.
- Chaudhuri, M. R. (1971). Independent bilateral primary bronchial carcinomas. *Thorax*, **26**, 476.
- Clifton, E. E., Das Gupta, T., and Pool, J. L. (1964). Bilateral pulmonary resection for primary or metastatic lung cancer. *Cancer*, **17**, 86.
- Glennie, J. S., Harvey, P. W., and Salama, V. (1964). Multiple primary carcinoma of the bronchus: a report of three cases. *Journal of Thoracic and Cardiovascular Surgery*, **48**, 40.
- Hughes, R. K. and Blades, B. (1961). Multiple primary bronchogenic carcinoma. *Journal of Thoracic and Cardiovascular Surgery*, **41**, 421.



**FIG. 4.** (a) Detail of left upper zone of chest radiograph taken in 1969. Arrow points to new shadow. (b) Appearance in 1971. (c) Appearance in 1973. (d) Tomogram appearance before segmental resection of posterior segment of left upper lobe in 1974 for secondary primary carcinoma.



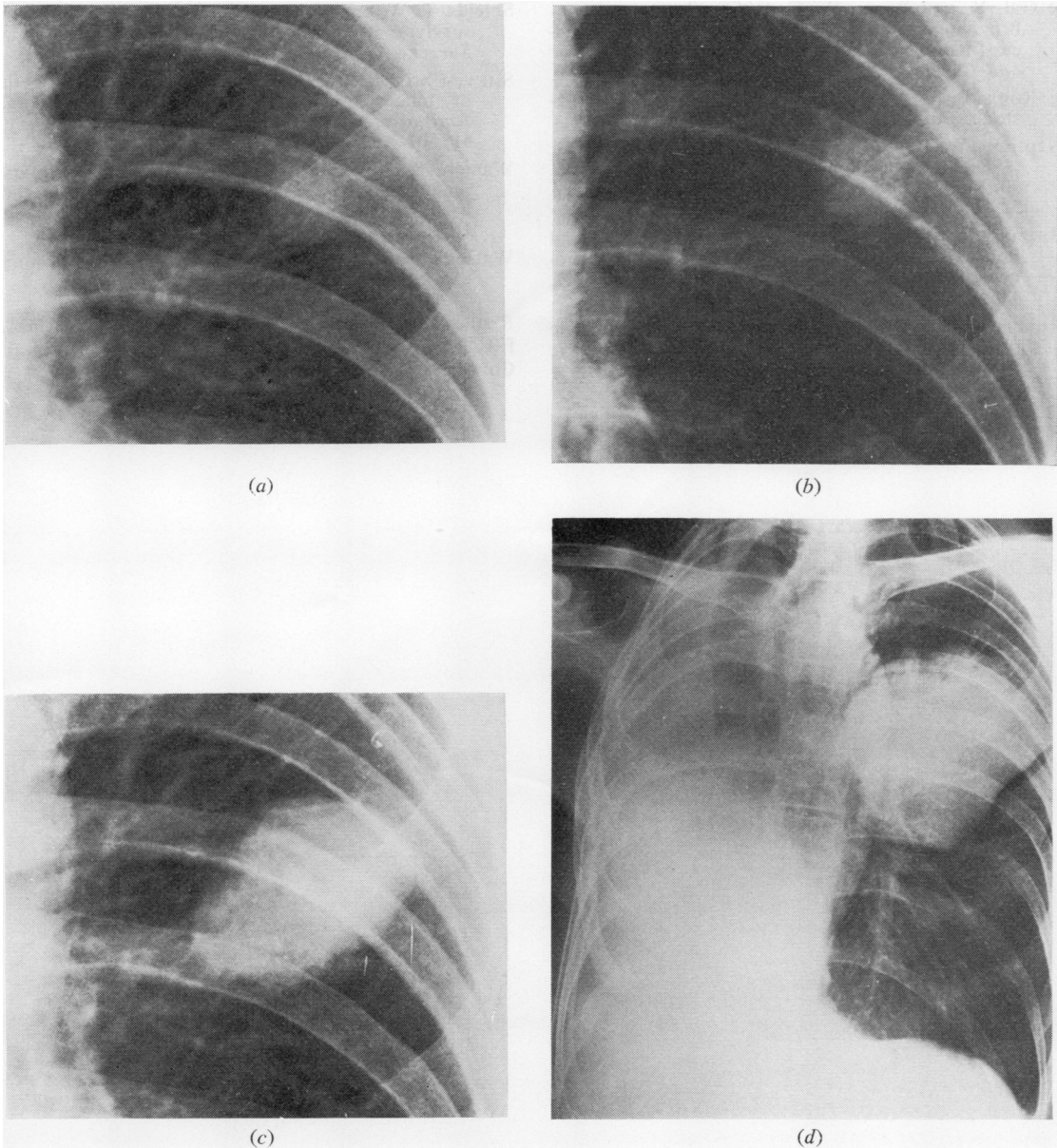


FIG. 5. (a) Case 2. Detail of left upper zone of chest radiograph in 1970. The shadow was first visible in 1969. (b) Appearance in 1972. (c) Appearance in 1973. (d) Appearance in May 1975 (compare size with Fig. 4d).

- le Gal, Y. and Bauer, W. C. (1961). Second primary bronchogenic carcinoma—A complication of successful lung cancer surgery. *Journal of Thoracic and Cardiovascular Surgery*, **41**, 114.
- le Roux, B. T. (1968). *Bronchial Carcinoma*. Livingstone, Edinburgh.
- Neptune, W. B., Woods, F. M., and Overholt, R. H. (1966). Reoperation for bronchogenic carcinoma. *Journal of Thoracic and Cardiovascular Surgery*, **52**, 342.
- Razzuk, M. A., Pockey, M., Urschel, H. C., Jr., and Paulson, D. L. (1974). Dual primary bronchogenic carcinoma. *Annals of Thoracic Surgery*, **17**, 425.
- Robinson, C. L. N. and Jackson, C. A. (1958). Multiple primary cancer of the lung. *Journal of Thoracic Surgery*, **36**, 166.
- Shields, T. W. and Robinette, C. D. (1973). Long term survivors after resection of bronchial carcinoma. *Surgery, Gynecology and Obstetrics*, **136**, 759.
- Struve-Christensen, E. (1971). Diagnosis and treatment of bilateral primary bronchogenic carcinoma. *Journal of Thoracic and Cardiovascular Surgery*, **61**, 501.
- Warren, S. and Gates, O. (1932). Multiple primary malignant tumors: a survey of the literature and a statistical study. *American Journal of Cancer*, **16**, 1358.
- Watson, W. L. (1965). Ten-year survival in lung cancer: a study of 56 cases. *Cancer*, **18**, 133.

Requests for reprints to: R. Abbey Smith, ChM, FRCS, Cardiothoracic Unit, Walsgrave Hospital, Coventry, Warwickshire.