

Diagnostic fibreoptic bronchoscopy in the immunocompromised host with pulmonary infiltrates

RICHARD A. MATTHAY, WAYNE C. FARMER, AND DIXON ODERO

From the Department of Medicine, Division of Pulmonary Medicine, Yale University School of Medicine, New Haven, Connecticut 06510, USA

Matthay, R. A., Farmer, W. C., and Odero, D. (1977). Thorax, 32, 539-545. Diagnostic fibreoptic bronchoscopy in the immunocompromised host with pulmonary infiltrates. Nineteen immunocompromised patients with pulmonary infiltrates underwent diagnostic fibreoptic bronchoscopy with transbronchial forceps and brush biopsy. A specific diagnosis was obtained in 21/25 procedures (10/11 focal lesions and 11/14 diffuse lesions). The most common diagnosis was infection, and organisms isolated included bacteria, fungi, *Pneumocystis carinii*, and herpes simplex. A pneumothorax requiring tube drainage occurred in two cases and mild lung parenchymal bleeding was noted in two others. It is concluded that fibreoptic bronchoscopy with forceps and brush biopsy can be performed safely with an excellent diagnostic yield in immunocompromised hosts with lung lesions. Supplemental oxygen should be administered during fibreoptic procedures in these patients and platelet transfusions should be given when thrombocytopenia is present.

Since its introduction in 1968, flexible fibreoptic bronchoscopy has been widely employed in the evaluation and management of patients with pulmonary disorders (Khan *et al.*, 1976). The procedure is easily performed, is associated with few complications, and affords greater visualisation of the endobronchial tree than rigid bronchoscopy. Patients can undergo this procedure with minimal discomfort, and biopsy of previously inaccessible areas of the lung may be accomplished using the standard biopsy forceps accompanying the flexible fibreoptic bronchoscope.

Recently, several studies have demonstrated a high degree of diagnostic accuracy employing fibreoptic bronchoscopy for determining the aetiology of both focal and diffuse pulmonary infiltrates (Levin *et al.*, 1974; Zavala, 1975; Cunningham *et al.*, 1977). The safety and diagnostic yield of this procedure applied specifically to immunocompromised hosts with pulmonary lesions requires analysis. These patients are frequently at risk for lung biopsy procedures, particularly due to the presence of arterial hypoxaemia, abnormal clotting factors, and thrombocytopenia (Greenman *et al.*, 1975; Hanson *et al.*, 1976). The purpose of this study was to determine whether fibreoptic bronchoscopy employing brush and forceps biopsy

is a safe and accurate method for determining the aetiology of pulmonary infiltrates in the immunocompromised patient.

Material and methods

Nineteen consecutive immunocompromised patients who underwent fibreoptic bronchoscopy for diagnosis of pulmonary infiltrates were studied prospectively. The study population was limited to patients who had established diagnoses of leukaemia, lymphoma, collagen vascular disease, organ transplantation or other diseases for which they had received corticosteroids, cytotoxic drugs, and/or radiation therapy. There were 13 men and six women with an average age of 44, range 19-75 years. Underlying disease, characteristics of chest radiographs, arterial blood gas values, platelet count, prothrombin time, partial thromboplastin time, complications, diagnostic yield, and patient outcome were analysed.

Immunocompromised patients who developed pulmonary lesions were evaluated with cultures of sputum, transtracheal aspirates (Ries *et al.*, 1974), blood, urine, and, if indicated, cerebrospinal fluid. If these failed to yield a diagnosis by appropriate stains and cultures fibreoptic bronchoscopy was

performed. Procedures followed were those described by Levin *et al.* (1974) and Ellis (1975). Patients received nothing by mouth for at least six hours before the procedure. Premedications including codeine (30–60 mg) and atropine (0.4–0.6 mg) were given intramuscularly 30 minutes before the procedure. The patients' oropharynx and naris were anaesthetised with 4% lidocaine. In addition, viscous lidocaine was used to anaesthetise and lubricate the naris. The Olympus BF 5B2 fiberoptic bronchoscope was passed transnasally (Smiddy *et al.*, 1971). Under direct vision, the vocal cords were examined and further anaesthetised with 2% lidocaine through the bronchoscope's suction and biopsy channel. The trachea was then entered and biopsy performed. When indicated, to ensure comfort and to facilitate the procedure diazepam (Valium), 5–10 mg, was administered intravenously. Topical anaesthetic (1% lidocaine) was instilled into the airways with careful dose monitoring.

Supplemental oxygen was administered through a single-prong catheter attached to the naris (Petty *et al.*, 1973). For one patient requiring assisted ventilation the bronchoscope was passed directly into the trachea through an endotracheal tube using an adaptor that provides a tight seal to maintain adequate tidal volume and ventilation (Amikam *et al.*, 1972). Patients with platelet counts less than 50 000/mm³ received platelet transfusions (10 platelet packs in most cases) during and immediately after the procedure to obtain platelet counts greater than 100 000/mm³.

After complete examination of the tracheo-bronchial tree, including subsegmental bronchi, if no endotracheal lesions were seen, the bronchoscope was guided directly or by fluoroscopy into the segment containing the lesion for biopsy. Under fluoroscopic guidance, the standard biopsy forceps that accompanies the Olympus bronchoscope was passed peripherally in a closed position until mild resistance was met. The position of the forceps was carefully checked with fluoroscopy in both the lateral and anteroposterior projections. The proximity of the forceps to the visceral pleura was also noted. When satisfactory placement in the areas of involvement was achieved, the forceps was retracted 1 to 2 cm and opened, then advanced under fluoroscopic guidance into the lesion or within 1 to 2 cm of the visceral pleura in diffuse disease or until moderate resistance was encountered. The forceps was gently closed and slowly retracted while the bronchoscope was secured in the same position or slowly advanced to ensure accurate repositioning of the bronchial brush or forceps. The specimen was withdrawn

through the bronchoscope's biopsy channel. Multiple biopsy specimens were taken from the same or different areas of involvement. Unilateral biopsies were done to prevent the possible occurrence of bilateral pneumothoraces. Bronchial brushings (Fennessey, 1966; Fry and Manalo-Estrella, 1970; Repsher *et al.*, 1972; Finley *et al.*, 1974) of the same areas were performed and sent for cytological and microbiological examination. The biopsy specimens were placed in 10% formalin solution for histological examination. Additional specimens were placed in appropriate culture media.

Biopsy was performed in the radiology department using a single plane fluoroscopy unit with an image intensifying screen. Emergency equipment with cardiorespiratory arrest or pneumothorax management was available in all cases. Chest radiographs were taken just before the procedure and immediately afterwards.

Results

Nineteen patients underwent 25 fiberoptic bronchoscopy procedures. Underlying diseases are listed in Table 1. Risk factors for fiberoptic bronchoscopy are indicated in Table 2. Arterial oxygen tension among 16 hypoxaemia patients breathing ambient air ranged from 34 to 70 (average 55) mmHg. Platelet counts in seven thrombocytopenic patients ranged from 2400 to 90 000/mm³ (average 51 000/mm³). Five patients with platelet counts less than 50 000/mm³ received platelet transfusions during and immediately after bronchos-

Table 1 *Immunocompromised patients (19) and underlying diseases*

<i>Underlying disease</i>	<i>No. of patients</i>
Hodgkin's disease	6
Other lymphoma	2
Acute myelogenous leukaemia	4
Other leukaemia	1
Renal transplant	2
Bronchogenic carcinoma	1
Multiple myeloma	1
Histiocytic medullary reticulosis	1
Systemic lupus erythematosus	1

Table 2 *Risk factors for fiberoptic bronchoscopy in immunocompromised hosts (25 procedures, 19 patients)*

<i>Risk factor</i>	<i>No. of procedures</i>	<i>No. of patients</i>
Arterial hypoxaemia	18	16
Thrombocytopenia	9	7
Abnormal partial thromboplastin time	4	4
Abnormal prothrombin time	3	3

copy to obtain platelet counts greater than 100 000/mm³. An abnormal prothrombin time, greater than three seconds beyond control, was noted in three patients, and an abnormal partial thromboplastin time, greater than 45 seconds, was identified in four.

DIAGNOSTIC YIELD

The results of fiberoptic bronchoscopy with brush and forceps biopsy are shown in Table 3. The diagnostic yield of brush biopsy was 63% and of transbronchial forceps biopsy 68%. The combined diagnostic yield for both brush and forceps biopsies was 84% (21/25 procedures). Bronchoscopy results were confirmed subsequently by positive blood cultures, clearing of pulmonary infiltrates with appropriate therapy, open lung biopsy, or necropsy.

Table 4 indicates diagnoses obtained by fiberoptic bronchoscopy. Secondary neoplasms were all bronchogenic carcinomas. Two patients, aged 29 and 41, had previously received radiation therapy to the thorax and intensive chemotherapy for Hodgkin's disease. The second tumours in these two patients developed in the previous radiation field. The third patient had received radiotherapy to the neck only for non-Hodgkin's lymphoma.

A specific infection was diagnosed by fiberoptic bronchoscopy in 14 patients. Table 5 shows that bacterial infection was identified most commonly followed by fungal organisms. A patient (RM) with histiocytic medullary reticulosis died with an invasive pulmonary *Aspergillus fumigatus* infection in spite of amphotericin B therapy (Fig. 1). A

Table 5 Specific pulmonary infections (14) diagnosed in immunocompromised hosts and outcome

Infection	No. of procedures	Infection resolved
Bacteria (<i>Klebsiella</i> 5, <i>Nocardia</i> 2, <i>Pseudomonas</i> 1, <i>Staphylococcus aureus</i> 1)	9	7/9
Fungus (<i>Aspergillus fumigatus</i> 1, <i>Aspergillus flavus</i> 1, <i>Candida albicans</i> 1)	3	2/3
Protozoan (<i>Pneumocystis carinii</i>)	1	0/1
Virus (Herpes simplex)	1	1/1

second patient (MM) with erythroleukaemia developed an invasive pulmonary *A. flavus* infection and recovered after amphotericin B and rifampicin therapy (Fig. 2). *Candida albicans* was identified on transbronchial brush and forceps biopsy specimens from a patient with acute myelogenous leukaemia. The pulmonary nodular infiltrates cleared after treatment with amphotericin B. *Pneumocystis carinii* was isolated from brush and forceps biopsy specimens of a patient with stage IVB Hodgkin's disease after corticosteroids and cytotoxic chemotherapy had been discontinued. In spite of pentamidine therapy followed by pyramethamine and sulphadiazine therapy the patient died two months later with respiratory failure. At necropsy there was no evidence of *Pneumocystis carinii* in the lungs. Herpes simplex was identified on viral cultures of the lung in a patient receiving cytotoxic drugs for Hodgkin's disease (stage IVB), and the patient recovered spontaneously with clearing of the chest radiograph.

No specific diagnosis was obtained by fiberoptic bronchoscopy in four patients. Subsequently two of these patients died, and a necropsy revealed radiation pneumonitis in one. No necropsy was performed in the other patient. The pulmonary infiltrates cleared spontaneously in the third patient with Hodgkin's disease, and in the fourth case a diagnosis of pulmonary *Nocardia* infection was made on repeat fiberoptic bronchoscopy.

COMPLICATIONS

The morbidity of bronchoscopy with transbronchial forceps and brush biopsy was low. Pneumothorax requiring a chest tube occurred as a result of two procedures. Mild, transient haemoptysis with an increase in alveolar filling on the chest radiograph was noted in two other patients, and in neither instance was blood transfusion necessary. Both patients with bleeding had leukaemia and were thrombocytopenic with platelet counts of 2400/mm³ and 40 000/mm³ respectively. In one the partial thromboplastin time was abnormal; however, in both, the pro-

Table 3 Diagnostic yield of fiberoptic bronchoscopy in immunocompromised hosts with pulmonary infiltrates (19 patients)

Type of pulmonary infiltrate	Specific diagnosis	No. of procedures	Diagnostic yield %
Diffuse	11	14	79
Focal	10	11	91
Total	21	25	84

Table 4 Diagnoses obtained by fiberoptic bronchoscopy in immunocompromised hosts with pulmonary infiltrates (25 procedures)

Diagnosis	No. of procedures
Specific infection	14
Secondary neoplasm	3
Lung haemorrhage	1
Radiation pneumonitis	1
Lipoid pneumonitis	1
Mucous plug	1
No specific diagnosis	4

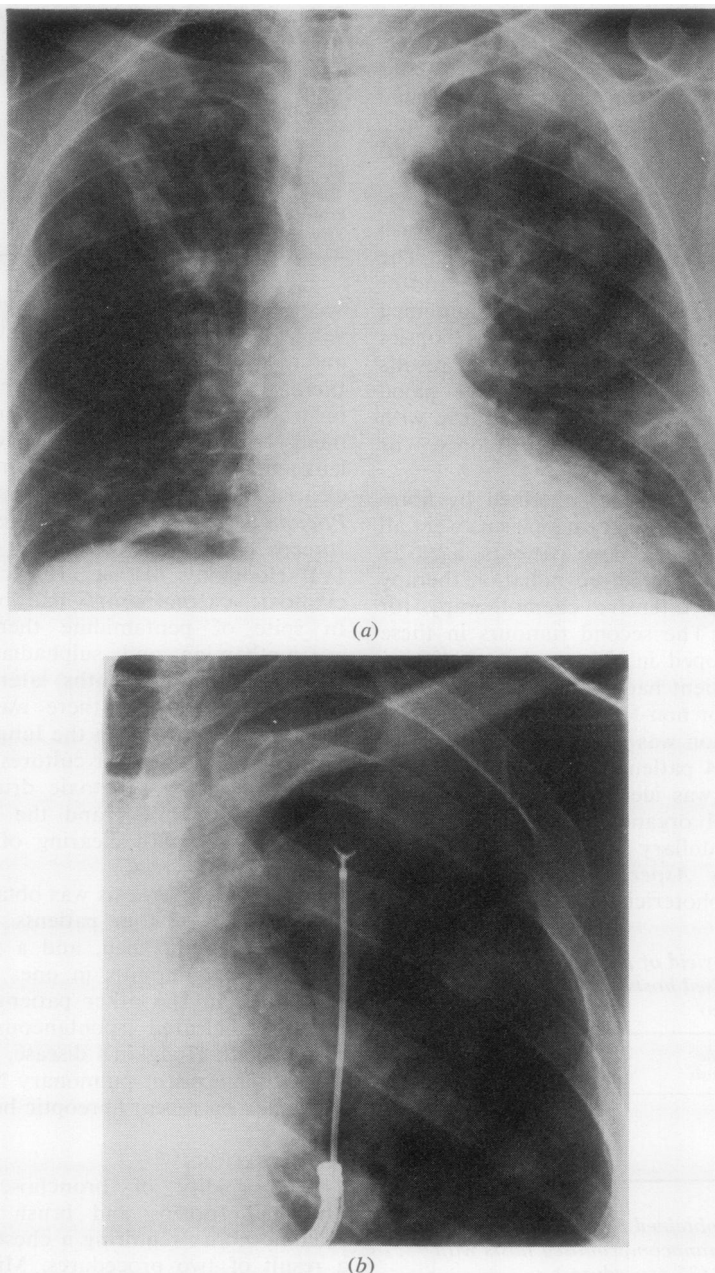


Fig. 1 Chest radiograph of a 65-year-old man (RM) with histiocytic medullary reticulosis receiving cytotoxic drugs and prednisone: (a) shows a bilateral, predominantly nodular infiltrate; (b) demonstrates the position of the biopsy forceps in the left upper lung zone during fiberoptic bronchoscopy. *Aspergillus fumigatus* was isolated on both transbronchial brush and forceps biopsies. *Aspergillus precipitans* rose from a titre of 1:8 to 1:32.

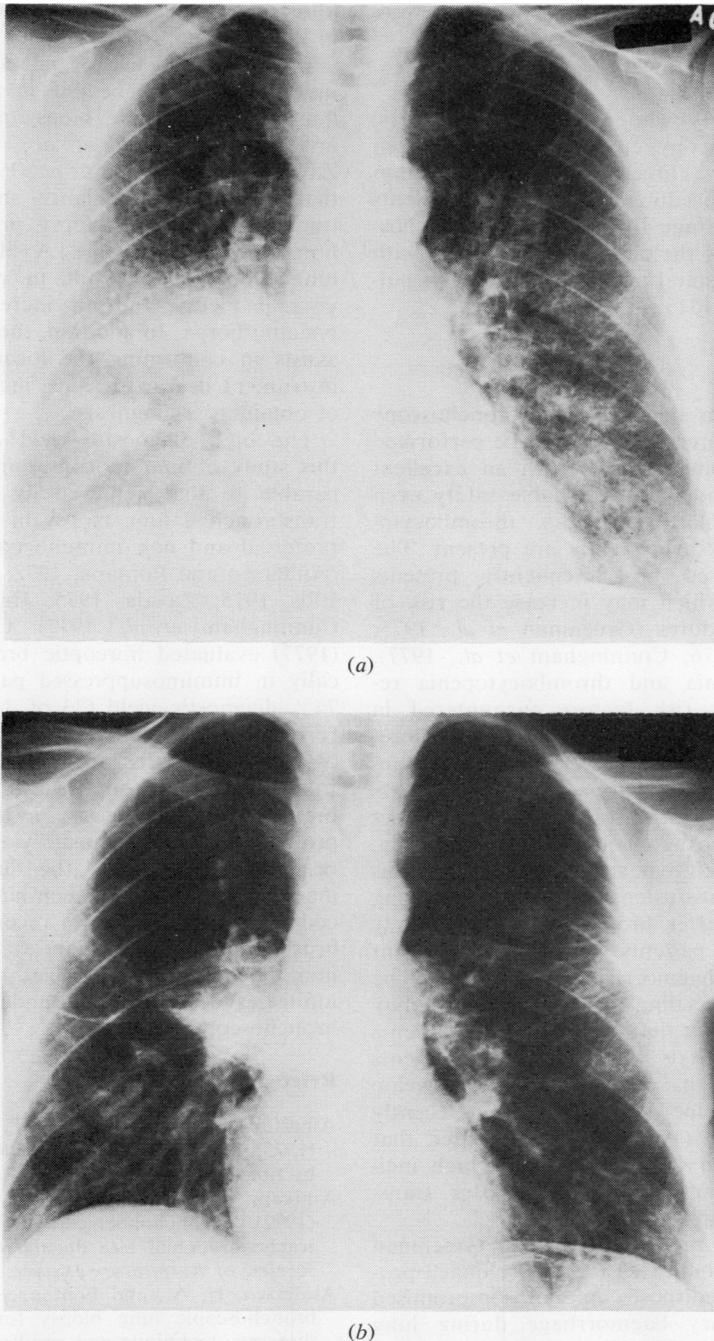


Fig. 2 Chest radiographs of a 52-year-old woman (MM) with erythroleukaemia receiving cytotoxic chemotherapy. Brush and transbronchial forceps lung biopsies revealed *Aspergillus flavus*, and *Aspergillus precipitans* rose from a titre of 1:8 to 1:32: (a) shows diffuse, bilateral infiltrates; (b) after four weeks' therapy with amphotericin B and rifampicin reveals considerable clearing of the pulmonary infiltrates.

thrombin time was normal. No fatalities were attributed to fiberoptic bronchoscopy.

OUTCOME

Of the 19 patients who underwent diagnostic fiberoptic bronchoscopy, eight are still alive seven to 16 months later. Three deaths occurred within one week of the procedure and eight other patients died two to 20 (average 10) weeks after bronchoscopy. Resolution of the pulmonary infiltrates with discharge from hospital occurred in 10 of 14 pulmonary infections (71%) (Table 5).

Discussion

This study confirms that fiberoptic bronchoscopy using brush and forceps biopsy can be performed in immunocompromised hosts with an excellent diagnostic yield and with acceptable safety even when abnormal clotting factors, thrombocytopenia, and arterial hypoxaemia are present. The immunocompromised host frequently presents special problems which may increase the risk of lung biopsy procedures (Greenman *et al.*, 1975; Hanson *et al.*, 1976; Cunningham *et al.*, 1977). Arterial hypoxaemia and thrombocytopenia represent significant risk factors encountered in immunocompromised patients undergoing fiberoptic bronchoscopy (Hanson *et al.*, 1976). Supplemental oxygen, found to be useful by others (Albertini *et al.*, 1975; Zavala, 1975) to protect against severe hypoxaemia during bronchoscopy, appeared to protect hypoxaemic patients in this study. Platelet transfusions administered during and immediately after bronchoscopy in severely thrombocytopenic patients appeared to prevent severe pulmonary haemorrhage in our study. The low incidence of bleeding (8%) in this series may be related to the fact that only two of 19 patients had renal failure. It is well known that patients with renal failure have a tendency to develop bleeding (Kazatchkine *et al.*, 1976), and recently Cunningham *et al.* (1977) have emphasised that uraemic patients in their series had a high incidence of pulmonary haemorrhage after transbronchial biopsy (45%).

In addition to thrombocytopenia, Greenman *et al.* (1975) have indicated that a prolonged prothrombin time predisposes immunocompromised hosts to pulmonary haemorrhage during lung biopsy procedures. In the current study only three patients had abnormal prothrombin times and none developed pulmonary haemorrhage. Our results suggest that with proper precautions, including platelet transfusions for thrombocytopenia and continuous supplemental oxygen, diagnostic

fiberoptic bronchoscopy can be performed safely in immunocompromised patients.

The low incidence of pneumothorax observed in our series may be due in part to the use of fluoroscopy to guide biopsy procedures. Several investigators (Levin *et al.*, 1974; Ellis, 1975; Zavala, 1975; Hanson *et al.*, 1976) have indicated that fluoroscopic guidance should be used for transbronchial lung biopsy procedures with the fiberoptic bronchoscope. A blind transbronchial lung biopsy may result in perforation of the visceral pleura and an increased incidence of pneumothorax. In addition, the use of fluoroscopy assists in confirming the location of the biopsy instrument in focal lesions, increasing the chance of obtaining a diagnosis.

The high diagnostic yield obtained by us in this study of immunocompromised hosts is comparable to that achieved by others performing transbronchial lung biopsy in both immunocompromised and non immunocompromised patients (Andersen and Fontana, 1972; Levin *et al.*, 1974; Ellis, 1975; Zavala, 1975; Hanson *et al.*, 1976; Cunningham *et al.*, 1977). Cunningham *et al.* (1977) evaluated fiberoptic bronchoscopy specifically in immunosuppressed patients, obtaining a 74% diagnostic yield (23 of 31 procedures) with forceps transbronchial biopsy and a 28% yield (9 of 31 procedures) with bronchial brush biopsy. In the present study brush biopsy and transbronchial forceps biopsy evaluated individually provided similar diagnostic yields of 63 and 68% respectively. However, the diagnostic yield was increased to 84% by combining the two procedures. Therefore, we recommend that both brush and forceps biopsies be performed in immunocompromised hosts with pulmonary infiltrates who are undergoing fiberoptic bronchoscopy.

References

- Albertini, R. E., Harrell, J. H., and Moser, K. M. (1975). Management of arterial hypoxemia induced by fiberoptic bronchoscopy. *Chest*, **67**, 134-136.
- Amikam, B., Landa, J., West, J., and Sackner, M. A. (1972). Bronchofiberscopic observations of the tracheobronchial tree during intubation. *American Review of Respiratory Disease*, **105**, 747-755.
- Andersen, H. A., and Fontana, R. S. (1972). Transbronchoscopic lung biopsy for diffuse pulmonary diseases: technique and results in 450 cases. *Chest*, **62**, 125-128.
- Cunningham, J. H., Zavala, D. C., Corry, R. J., and Keim, L. W. (1977). Trephine air drill, bronchial brush and fiberoptic transbronchial lung biopsies in immunosuppressed patients. *American Review of Respiratory Disease*, **115**, 213-220.

- Ellis, J. H., Jr. (1975). Transbronchial lung biopsy via the fiberoptic bronchoscope: experience with 107 consecutive cases and comparison with bronchial brushing. *Chest*, **68**, 524-532.
- Fennessey, J. J. (1966). A technique for the selective catheterization of segmental bronchi using arterial catheters. *American Journal of Roentgenology*, **96**, 936-943.
- Finley, R., Kieff, E., Thomsen, S., Fennessy, J., Beem, M., Lerner, S., Morello, J. (1974). Bronchial brushing in the diagnosis of pulmonary disease in patients at risk for opportunistic infection. *American Review of Respiratory Disease*, **109**, 379-387.
- Fry, W. A., and Manalo-Estrella, P. (1970). Bronchial brushing. *Surgery, Gynecology and Obstetrics*, **130**, 67-71.
- Greenman, R. L., Goodall, P. T., and King, D. (1975). Lung biopsy in immunocompromised hosts. *American Journal of Medicine*, **59**, 488-496.
- Hanson, R. R., Zavala, D. C., Rhodes, M. L., Keim, L. W., and Smith, J. D. (1976). Transbronchial biopsy via flexible fiberoptic bronchoscope: Results in 164 patients. *American Review of Respiratory Disease*, **114**, 67-72.
- Kazatchkine, M., Sultan, Y., Caen, J. P., and Bariety, J. (1976). Bleeding in renal failure: A possible cause. *British Medical Journal*, **2**, 612-615.
- Khan, M. A., Whitcomb, M. E., and Snider, G. L. (1976). Flexible fiberoptic bronchoscopy. *American Journal of Medicine*, **61**, 151-155.
- Levin, D. C., Wicks, A. B., and Ellis, J. H., Jr. (1974). Transbronchial lung biopsy via the fiberoptic bronchoscope. *American Review of Respiratory Disease*, **110**, 4-12.
- Petty, T. L., Nett, L. M., and Lakshminarayan, S. (1973). A single nasal prong for continuous oxygen therapy. *Respiratory Therapy*, **18**, 421.
- Repsher, L. H., Schröter, G., and Hammond, W. S. (1972). Diagnosis of *Pneumocystis carinii* pneumonia by means of endobronchial biopsy. *New England Journal of Medicine*, **287**, 340-341.
- Ries, K., Levison, M. E., and Kaye, D. (1974). Trans-tracheal aspiration in pulmonary infection. *Archives of Internal Medicine*, **133**, 453-458.
- Smiddy, J. F., Ruth, W. E., Kerby, G. R., Renz, L. E., and Raucher, C. (1971). Flexible fiberoptic bronchoscope (letter). *Annals of Internal Medicine*, **75**, 971.
- Zavala, D. C. (1975). Diagnostic fiberoptic bronchoscopy: techniques and results of biopsy in 600 patients. *Chest*, **68**, 12-19.

Requests for reprints to: Dr. R. A. Matthay, Division of Pulmonary Medicine, Department of Medicine, Yale University School of Medicine, 333 Cedar Street, New Haven, Connecticut 06510, USA.