

Primary mediastinal trophoblastic teratomas

P. A. M. WALDEN, R. L. WOODS, B. FOX, AND K. D. BAGSHAWE

From the Departments of Medical Oncology and Histopathology, Charing Cross Hospital, London W6, UK

Walden, P. A. M., Woods, R. L., Fox, B., and Bagshawe, K. D. (1977). *Thorax*, **32**, 752–758. **Primary mediastinal trophoblastic teratomas.** Three cases of primary mediastinal trophoblastic teratoma are described. One patient died from respiratory failure during the initial chemotherapy. Another patient with advanced disease is now apparently free from disease after multiple-drug chemotherapy. The third patient is alive and well four years after a combination of surgery, radiotherapy, and multiple-drug chemotherapy. In the diagnosis and assessment of response to treatment in these tumours emphasis is placed on the measurement of the tumour cell markers, chorionic gonadotrophin and alpha-fetoprotein, by radioimmunoassay. The efficacy of multiple-drug regimens is discussed together with a review of the literature.

Primary trophoblastic teratoma arising in the mediastinum is rare (Bennington *et al.*, 1964; Macgovern and Blades, 1958; Yurick and Ottoman, 1960). In an extensive review of 109 reported cases, only 19 were wholly acceptable as being primarily extragonadal in origin (Fine *et al.*, 1962). Fine and his associates and several other workers (Prym, 1927; Azzopardi *et al.*, 1961; Rather *et al.*, 1954) have suggested that in many cases mediastinal trophoblastic teratoma may be secondary to a primary testicular tumour. Careful examination of the testes is essential before the diagnosis is attributed to a primary mediastinal lesion.

We report three cases of primary mediastinal trophoblastic teratoma together with a review of the literature.

Case reports

CASE 1

An 11-year-old schoolboy with a past history of bronchial asthma first presented in September 1971 with increasing dyspnoea. This was attributed to an exacerbation of asthma. His symptoms worsened and a chest radiograph in March 1972 revealed a large anterior mediastinal tumour which extended into the left hemithorax (Fig. 1). At thoracotomy on 7 March a massive, solid, vascular mediastinal tumour attached to the pericardium and bronchovascular structures was found to be unresectable.

A biopsy showed a malignant teratoma (Figs 2

and 3) composed of cysts lined by ciliated columnar, cuboidal, and mucus-secreting columnar epithelium and islands of keratinised squamous epithelium. There was fibrovascular tissue, smooth muscle, cartilage, and areas of primitive mesenchymal tissue. There were no trophoblastic elements.

He was treated with a course of vinblastine, actinomycin D, and methotrexate and on 21 March he was transferred to Charing Cross Hospital. Examination at that time revealed marked facial acne and precocious development of secondary sexual characteristics but no gynaecomastia. He was febrile (38°C) and markedly tachypnoeic (40/min). The trachea was deviated to the right and the left hemithorax was deformed and showed prominent veins over the upper chest. The testes were normal to palpation. The initial urinary chorionic gonadotrophin (HCG) excretion rate was 1.4×10^3 IU/l (normal range 10–50 IU/l). He was treated with a course of 6 azauridine, methotrexate, and folic acid followed by a course of treatment with vincristine and cyclophosphamide. Apart from some evidence of myelosuppression there was relatively little toxicity and marked clinical improvement. Further chemotherapy with a multiple-drug regimen (Macamoll) (Table 1) was given, and after completion of five such courses over a period of four months the urinary HCG excretion rate had become normal. The radiological appearance of the chest had not changed and a course of radiotherapy with 2700 rads was

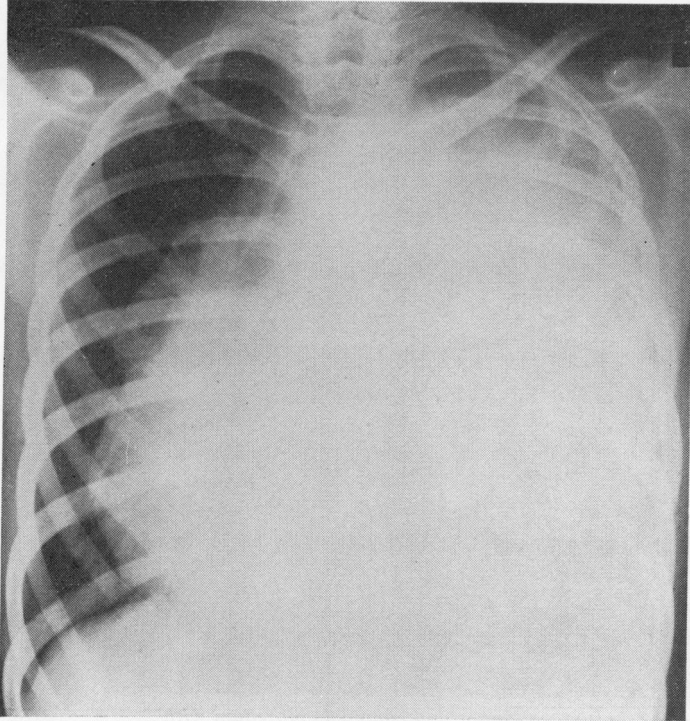


Fig. 1 *Case 1. Initial radiograph showing large anterior mediastinal tumour extending into the left hemithorax.*

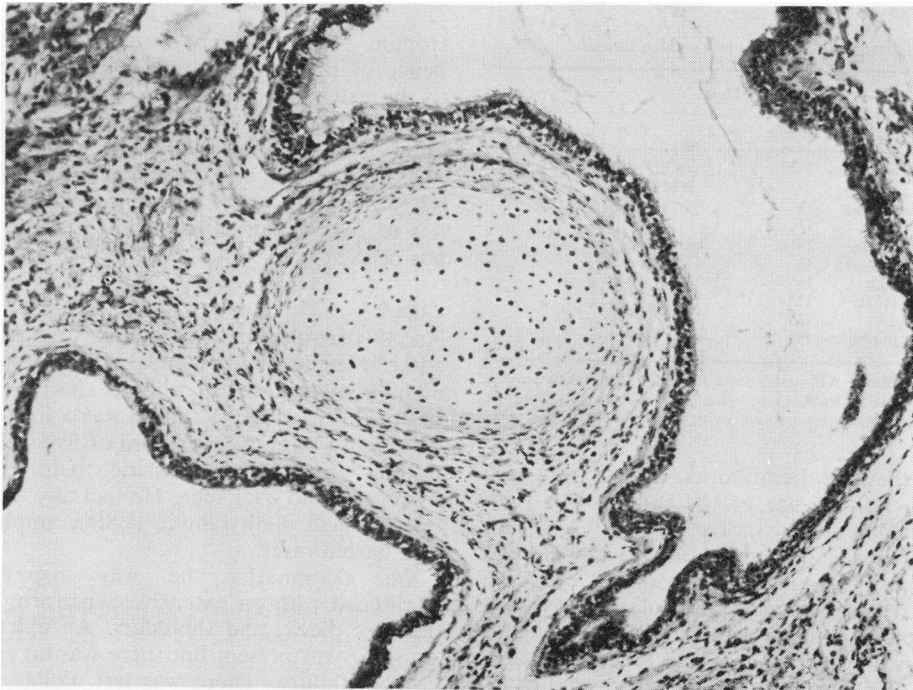


Fig. 2 *Case 1. Cartilage and cysts lined by ciliated columnar epithelium (Haematoxylin and eosin $\times 100$).*

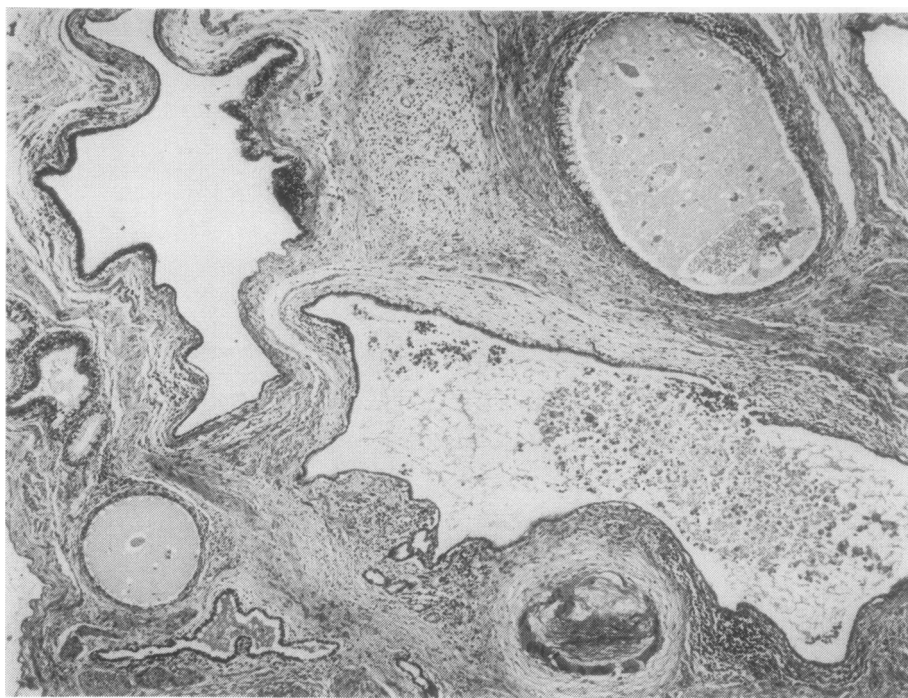


Fig. 3 Case 1. Cysts lined by mucus-secreting columnar and cuboidal epithelium with areas of undifferentiated mesenchymal tissue (Haematoxylin and eosin $\times 40$).

Table 1 Multiple drug regimen—Macamoll

Drug*	Dose	Route	Day											
			1	2	3	4	5	6	7	8	9			
6-AZ	500 mg/kg	PO	↓	↓	16 h WM									
AD	0.01 mg/kg	IV				↓	↓	↓	↓					
MITH	50 μ g/kg	IV				↓	↓	↓	↓					
MTX	0.8 mg/kg	IV				↓	↓	↓	↓					
VCR	0.025 mg/kg	IV				↓	↓	↓	↓					
CTX	5 mg/kg	IV				↓	↓	↓	↓					
L-ASP	10,000 IU	IM				↓	↓	↓	↓	↓	↓	↓	↓	↓
FA	6 mg	IM				↓	↓	↓	↓	↓	↓	↓	↓	↓
Chlor	200 mg bd	PO				↓	↓	↓	↓	↓	↓	↓	↓	↓

*6-AZ=6-azauridine; AD=actinomycin D; MITH=mithramycin; MTX=methotrexate; VCR=vincristine; CTX=cyclophosphamide; L-ASP=L-asparaginase; FA=folinic acid; Chlor=chloroquine

given to the left hemithorax. There was only slight reduction in size of the tumour but HCG titres remained in the normal range. A second thoracotomy was performed in November 1972 and a large (3.5 kg) well-encapsulated cystic tumour was removed by intracapsular enucleation. Macroscopic examination at this stage showed no involvement of the left lung and other structures. Histology of the tumour was similar to that of the original biopsy. Since that time this patient has remained free from disease with normal gonado-

trophin titres. The chest radiograph shows evidence of mediastinal displacement, probably due to the extensive pleural fibrosis found at thoracotomy and considerable reduction in the size of the anterior mediastinal lesion. This has not increased in size since 1972 and is thought to represent fibrosis rather than active neoplasm. The facial acne has regressed and subsequent sexual development has been normal.

CASE 2

An 18-year-old boy was found to have a large anterior mediastinal tumour with widespread pulmonary metastases on routine chest radiography in June 1975 (Fig. 4). There was a history of loss of weight (4 kg) over a period of five weeks, intermittent right-sided pleuritic pain, exertional dyspnoea, and backache. He had also been taking lysergic acid diethylamine (LSD), amphetamines, and barbiturates.

On examination he was aggressive and frightened with an extensive acneiform rash over the face, back, and shoulders. An apical systolic murmur was present but there was no evidence of cardiac failure. There was left axillary node enlargement but the testes were small with no clinical evidence of tumour. The initial urinary HCG

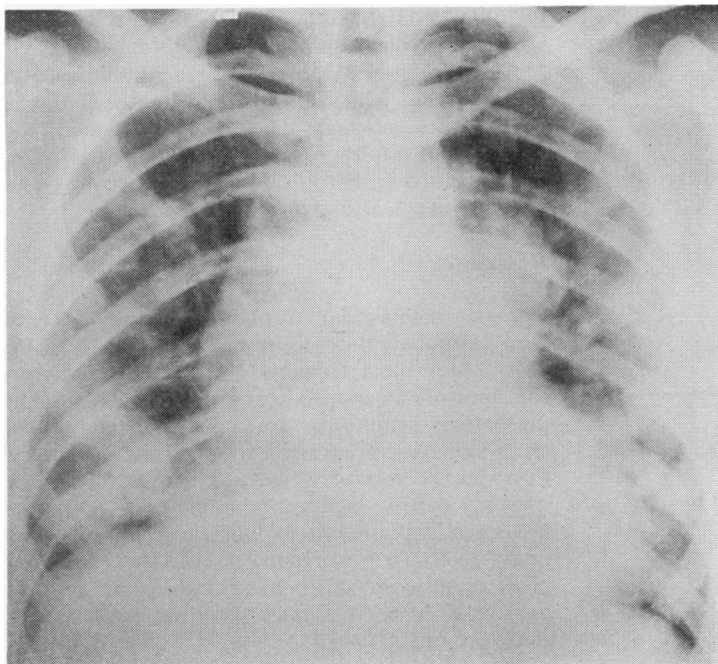


Fig. 4 Case 2. Initial radiographic appearances of a large anterior mediastinal tumour with widespread metastases.

excretion rate was 2×10^6 IU/l with a plasma HCG concentration of 4.4×10^4 IU/l (normal < 2.5 IU/l): the AFP concentration was normal. The plasma testosterone was 33 nmol/l (normal < 21 nmol/l). There was no evidence of para-aortic node involvement and a liver scan was normal.

Treatment was started with a multi-drug regimen (Chamoma, Table 2). There was a rapid fall in the concentration of HCG after two courses of this treatment (Fig. 5). Toxicity was confined to myelosuppression with thrombocytopenia and leucopenia, the nadir of WBC being reached seven to eight days after completion of each course. After three courses of Chamoma at two-week intervals the HCG values were normal and further treatment with three courses consisting of vinblastine and bleomycin was given, also at intervals of two weeks. Toxicity consisted of myelosuppression with a fall in the WBC to < 1000 /cm seven days after completion of the bleomycin infusion. Other toxic features with this regimen included mucositis and severe back pain. At the present time the patient remains free from disease with a normal gonadotrophin titre and normal chest radiograph 30 months after first presentation.

CASE 3

A 33-year-old Negro barrister from Guyana was admitted on 6 November 1975 with a six-month history of malaise, dyspnoea, intermittent right-

Table 2 Multiple drug regimen—Chamoma

Drug*	Dose	Route	Day												
			1	2	3	4	5	6	7	8	9	10			
HYD	500 mg bd	PO	■	■											
VCR	100 mg/m ²	IV start			100	↓									
MTX	200 mg/m ²	infusion over 12 h				■									
FA	18 mg/m ²	IM					↓								
	8 mg/m ²	IM						↓	↓	↓					
CTX	600 mg/m ²	IV						↓	↓	↓					
AD	0.5 mg	IV							↓	↓					
ADR	30 mg/m ²	IV													
ME	6 mg/m ²	IV													↓

*HYD = hydroxyurea; VCR = vincristine; MTX = methotrexate; FA = folic acid; AD = actinomycin D; ADR = adriamycin; ME = melphalan; CTX = cyclophosphamide

sided pleuritic pain, and discomfort in the right nipple. There was a history of filariasis and heavy drinking (half-bottle of rum per day) resulting in hepatomegaly in August 1974; he was also a heavy cigarette smoker (3 packets/day).

On admission he was febrile (39°C) and icteric with palmar erythema and a few small spider naevi. He was grossly tachypnoeic (40/min) with prominent bilateral gynecomastia. There was a large right-sided pleural effusion and a tender enlarged liver 5 cm below the right costal margin and enlarged left posterior cervical nodes. Both testes were normal to palpation. He had a right

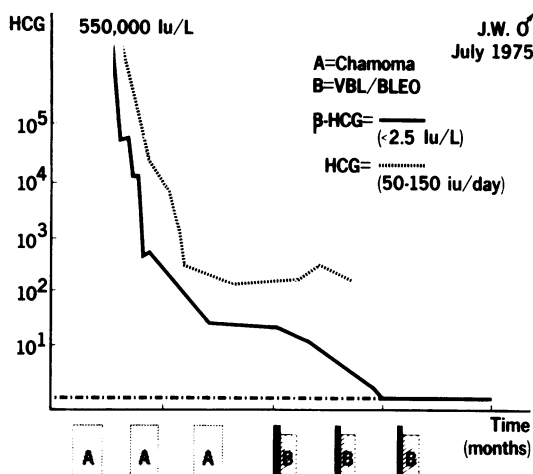


Fig. 5 Case 2. Levels of HCG in relation to treatment.

hemiparesis without papilloedema. Investigations revealed serum bilirubin 29 mg/l, alkaline phosphatase 40 KA units, and a raised urinary bilirubin. A liver scan was normal and liver biopsy revealed non-caseating granulomata. The alpha-fetoprotein (AFP) concentration was 1900 μ g/l (normal <50 μ g/l) and the urinary HCG excretion rate 1.3×10^6 IU/l (normal range 50–150 IU/l).

Intensive chemotherapy was started with multiple drug regimen Chamoma but he deteriorated soon after the beginning of intensive treatment and developed severe respiratory embarrassment. The blood gases at that time showed a PCO_2 of 27 mmHg, a PO_2 of 60 mmHg, a bicarbonate of 19 mEq/l, and pH 7.46. He was given oxygen and a course of co-trimoxazole was started. Myelosuppression and thrombocytopenia developed, the PO_2 fell to 40 mmHg, he was intubated, and intermittent positive pressure ventilation was started. He developed a pneumothorax and his respiratory function deteriorated further: he died on 27 November.

At necropsy there was a lobulated, greyish, haemorrhagic, partly cystic tumour, $15 \times 14 \times 12$ cm, in the right side of the mediastinum, compressing and infiltrating the right lung.

Sections showed mainly necrotic tissue with occasional foci of recognisable bone and undifferentiated malignant cells but no recognisable trophoblastic tissue. There were necrotic deposits in which no recognisable tumour tissue was seen in the brain, lung, kidney, and liver. Numerous sections from both testes showed no evidence of tumour. In both lungs there was a severe organis-

ing interstitial pneumonia and many of the air spaces were lined by hyaline membrane.

Although there were widespread metastases in the left lung, liver, kidneys, and peritoneum, the testes were normal. Histology confirmed the presence of multiple tissues including cartilage, glandular tissue, fibrous and muscular tissues, and multiple areas of malignant trophoblast.

Discussion

Primary mediastinal trophoblastic tumours are rare. Although they occur in both sexes (Peison, 1970), they most frequently afflict men between the ages of 20 and 40 years. The most common presenting symptoms are cough, haemoptysis, chest pain, and progressive dyspnoea accompanied by anorexia, loss of weight, and fever. Gynaecomastia, usually bilateral, completes the clinical picture and is present in half the cases (Wenger *et al.*, 1968). In most recorded series these tumours grow rapidly and death has occurred within days or weeks from the date of initial presentation (Sickles *et al.*, 1974).

The exclusion of a primary testicular lesion is always difficult (Sickles *et al.*, 1974; Wacksman *et al.*, 1975). Although some authorities recommend multiple testicular sections (Sickles *et al.*, 1974; Kantrowitz, 1934; Asif and Vehling, 1968; Greenwood *et al.*, 1971), others contend that these procedures are unnecessary since the number of cases revealing microscopic foci of malignant tissue in the testes are small (Utz and Buscemi, 1971; Martini *et al.*, 1974). In a recent study, out of a total of 13 extragonadal germ-cell tumours there was no evidence of malignancy in the testes of 11 cases at necropsy although two showed a well-defined scar (Johnson *et al.*, 1973). In 1927 Prym and, more recently, others (Rather *et al.*, 1954) have inferred that the finding of a scar in the testes of such cases is suggestive of regression of a primary testicular tumour. Conversely, Lynch and Blewett (1953) consider that the testicular scar may be the result of a high chorionic gonadotrophin secretion from a primary extragonadal tumour.

The use of lymphography to demonstrate retroperitoneal lymph node enlargement (Wilkinson and MacDonald, 1975; Safer *et al.*, 1975) may help to differentiate between mediastinal teratoma and secondary metastases from primary testicular tumours. The absence of retroperitoneal lymph node involvement and normal testes on palpation strengthens the suspicion of a primary mediastinal teratoma.

The measurement of HCG and AFP in the

serum of these patients may allow the diagnosis to be established without major surgery and also plays a central role in the assessment of response to treatment (Fine *et al.*, 1962; Pachter and Lattes, 1964; Belliveau *et al.*, 1973). When all clinical evidence of disease has resolved, raised concentrations of HCG and AFP indicate persistent tumour activity. Treatment should be continued for two to three months after tumour markers have become undetectable by a sensitive radioimmunoassay.

Reports on the treatment of these tumours are sparse (Goldstein and Piro, 1972; Silvay *et al.*, 1973), no doubt because of their rarity. Curative surgical resection is rarely possible because of involvement of adjacent vital structures (Das *et al.*, 1975). Similarly, radiotherapy used as the primary mode of treatment, despite isolated reports indicating significant tumour regression (Schäfer, 1959), is seldom effective when used alone because metastatic spread occurs early. The treatment of choice at the present time appears to be combination chemotherapy (Sickles *et al.*, 1974).

The three cases reported here all had advanced disease. In the third case respiratory failure proved fatal despite intensive chemotherapy. Deterioration of respiratory function is not infrequent in our experience in patients with extensive pulmonary disease during the early stages of chemotherapy, and interstitial pneumonias may be caused by cytotoxic drugs (Rosenow, 1972).

However, in this case the rapid deterioration in respiratory function was intensified after oxygen therapy. It is now well recognised that oxygen, particularly in high concentrations, can cause diffuse alveolar damage which results in interstitial pneumonia similar to that found in this case (Katzenstein *et al.*, 1976).

The multiple-drug regimens described here have been effective in some cases of testicular teratoma (Woods *et al.*, 1977), and, of the two regimens listed (Tables I and II) Chemoma has been found to be the less toxic and the more effective. Myelosuppression and alopecia constituted the chief side-effects. Although rare, these tumours are potentially curable with multiple-drug chemotherapy and there is a case for their treatment to be carried out in specialised units.

We thank Mr. Andrew Kardana and Mrs. Marilyn Squires for HCG and AFP measurements and we are grateful to Professor A. E. Claireaux, Hospital for Sick Children, Great Ormond Street, for allowing us to see the histological material from case 1.

References

Asif, S., and Vehling, D. T. (1968). Microscopic

- tumour foci in testes. *Journal of Urology*, **99**, 776-779.
- Azzopardi, J. G., Mostofi, F. K., and Theiss, E. A. (1961). Lesions of testes observed in certain patients with widespread choriocarcinoma and related tumours. *American Journal of Pathology*, **38**, 207-225.
- Belliveau, R. E., Wiernik, P. H., and Sickles, E. A. (1973). Blood carcinoembryonic antigen, regan isoenzyme, and human chorionic gonadotrophin in a man with primary mediastinal choriocarcinoma. *Lancet*, **1**, 22-24.
- Bennington, J. L., Haber, S. L., and Schweid, A. (1964). Primary mediastinal choriocarcinoma—a report of a case. *Diseases of the Chest*, **46**, 623-626.
- Das, P. B., Bhaktaviziam, A., Gupta, R. P., Kanhere, M. H., Jairaj, P. S., Ray, D., and John, S. (1975). Primary malignant tumours of the mediastinum and their management. *Australian and New Zealand Journal of Surgery*, **45**, 42-48.
- Fine, G., Smith, R. W., Jr., and Pachter, M. R. (1962). Primary extragenital choriocarcinoma in the male subject. *American Journal of Medicine*, **32**, 776-794.
- Goldstein, D. P., and Piro, A. J. (1972). Combination chemotherapy in the treatment of germ cell tumors containing choriocarcinoma in males and females. *Surgery, Gynaecology and Obstetrics*, **134**, 61-66.
- Greenwood, S. M., Goodman, J. R., Schneider, G., Forman, B. H., Kress, S. C., and Gelb, A. F. (1971). Choriocarcinoma in a man. *American Journal of Medicine*, **51**, 416-422.
- Johnson, D. E., Laneri, J. P., Mountain, C. F., and Luna, M. (1973). Extragenital germ cell tumors. *Surgery*, **73**, 85-90.
- Kantrowitz, A. R. (1934). Extragenital chorionepithelioma in a male. *American Journal of Pathology*, **10**, 531-543.
- Katzenstein, A. L. A., Bloor, C. M., and Leibow, A. A. (1976). Diffuse alveolar damage—the role of oxygen, shock, and related factors. *American Journal of Pathology*, **85**, 210-228.
- Li, M. C., Whitmore, W. F., Jr., Golbey, R., and Grabstald, H. (1960). Effects of combined drug therapy on metastatic cancer of the testis. *Journal of the American Medical Association*, **174**, 1291-1299.
- Lynch, M. J. G., and Blewett, G. L. (1953). Choriocarcinoma arising in the male mediastinum. *Thorax*, **8**, 157-163.
- Macgovern, G. J., and Blades, B. (1958). Primary extragenital chorionepithelioma in the male mediastinum. *Journal of Thoracic Surgery*, **35**, 378-383.
- Martini, N., Golbey, R. B., Hajdu, S. I., Whitmore, W. F., and Beattie, E. J. Jr. (1974). Primary mediastinal germ cell tumors. *Cancer*, **33**, 763-769.
- Pachter, M. R., and Lattes, R. (1964). 'Germinal' tumors of the mediastinum: a clinicopathological study of adult teratomas, teratocarcinomas, choriocarcinomas, and seminomas. *Diseases of the Chest*, **45**, 301-310.
- Peison, B. (1970). Embryonal teratocarcinoma of the mediastinum in a woman with foci of anaplastic

- cells stimulating chorioepithelioma. *Chest*, **58**, 169–172.
- Prym, P. (1927). Spontanheilung eines bösartigen, wahrscheinlich chorionepitheliomatösen Gewächses im Hoden. *Virchows Archiv für Pathologische Anatomie und Physiologie und für klinische Medizin*, **265**, 239–258.
- Rather, L. J., Gardiner, W. R., and Frerichs, J. B. (1954). Regression and naturation of primary testicular tumors with progressive growth of metastases. *Stanford Medical Bulletin*, **12**, 12–25.
- Rosenow, E. C. III. (1972). The spectrum of drug induced pulmonary disease. *Annals of Internal Medicine*, **77**, 977–991.
- Safer, M. L., Green, J. P., Crews, Q. E., Jr., and Hill, D. R. (1975). Lymphangiographic accuracy in the staging of testicular tumours. *Cancer*, **35**, 1603–1605.
- Schäfer, H. (1959). Extragenitales chorionepitheliom bei einem Mann. *Strahlentherapie*, **108**, 283–287.
- Sickles, E. A., Belliveau, R. E., and Wiernik, P. H. (1974). Primary mediastinal choriocarcinoma in the male. *Cancer*, **33**, 1196–1203.
- Silvay, O., Yagoda, A., Wittes, R., Whitmore, W., and Golbey, R. (1973). Treatment of germ cell carcinomas with a combination of actinomycin D, vinblastine and bleomycin (Abstract). *Proceedings of the American Association for Cancer Research*, **14**, 271.
- Utz, D. C., and Buscemi, M. F. (1971). Extragonadal testicular tumors. *Journal of Urology*, **105**, 271–274.
- Wacksman, J., Case, G., and Glenn, J. F. (1975). Extragenital gonadal-neoplasia and metastatic testicular tumor. *Urology*, **5**, 221–223.
- Wenger, M. E., Dines, D. E., Ahmann, D. L., and Good, C. A. (1968). Primary mediastinal choriocarcinoma. *Mayo Clinical Proceedings*, **43**, 570–575.
- Wilkinson, D. J., and MacDonald, J. S. (1975). A review of the role of lymphography in the management of testicular tumours. *Clinical Radiology*, **26**, 89–98.
- Woods, R. L., Walden, P. A. M., and Bagshawe, K. D. (1977). The treatment of advanced testicular teratomas. In Press.
- Yurick, B. S., and Ottoman, R. E. (1960). Primary mediastinal choriocarcinoma. *Radiology*, **75**, 901–907.

Requests for reprints to: Professor K. D. Bagshawe, Department of Medical Oncology, Charing Cross Hospital, London W6, UK.