

Chronic cor pulmonale in pulmonary sarcoidosis

J. P. BATTESTI, R. GEORGES, F. BASSET, AND G. SAUMON

From CHU Bobigny—Paris 13, Service de Pneumologie and INSERM, Groupe de Recherches U 82, Paris, France

Battesti, J. P., Georges, R., Basset, F., and Saumon, G. (1978). Thorax, 33, 76-84. Chronic cor pulmonale in pulmonary sarcoidosis. Right-heart overload happens relatively rarely in sarcoidosis, even with fibroemphysematous changes. Of 21 cases that we studied, six (28%) had clinical and/or electrocardiographic features of cor pulmonale. The cause of cor pulmonale often evoked is an invasion of the walls of pulmonary vessels by sarcoid granulomas or their compression by the fibrotic process. Pathological studies in one patient showed compression of large pulmonary arteries associated with specific sarcoid lesions in small and medium-sized arteries.

The development of chronic cor pulmonale due to pulmonary hypertension has rarely been described in pulmonary sarcoidosis, even in chronic fibroemphysematous forms. The mechanisms often evoked to explain the occurrence of pulmonary hypertension are based on histological findings, the perivascular occurrence of granulomas with the fibrosis which sometimes results, and the possibility of thrombosis or invasion of arterial and vein walls by granulomas.

Material and methods

Twenty-one cases of chronic sarcoidosis were studied.

The diagnosis was made using clinical, radiological, pathological (bronchial biopsy), and immunological (Kveim test, tuberculin anergy) findings. Such a diagnosis was confirmed in life by these methods even in the two cases (2 and 5) where no definite evidence of sarcoidosis was found at necropsy many years later.

The radiographic classification was based on postero-anterior and lateral views, occasionally confirmed by tomography.

Evidence of right-sided heart involvement was based upon clinical examination and six electrocardiographic criteria (Schaub, 1966):

- 1 QRS vector angle in the frontal plane (angle α) $\geq +90^\circ$.
- 2 Negative T wave in S_2 and S_3 or S_3 and $\alpha \geq +90^\circ$.
- 3 S wave in V_5 and $V_6 \geq 0.7$ mV.
- 4 R wave in $V_1 + S$ wave in $V_5 > 1$ mV.

- 5 QRS direction to the right and posterior: rS of V_1 to V_4 , sometimes rS or Qs of V_1 to V_6 with positive or flattened T waves.

- 6 Incomplete right bundle-branch block: rS R' in V_1 with R' in $V_1 \geq 10$ mV.

Radiological measurement of the size of the right heart chambers and the diameter of the pulmonary arteries was in most cases impossible because of the perihilar pulmonary opacities which obscured the cardiac and arterial contours. Thus radiological criteria were not taken into account.

Results

ANALYSIS OF THE 21 CASES

The main results are shown in the Table. Three radiological groups may be distinguished:

Type I (5 cases) Very dense perihilar 'pseudo-tumour' shadows (with or without cavities); retraction of the upper lobes and transradiancy without bullous formation of the lower lobes (Fig. 1)

Type II (11 cases) Diffuse reticulonodulation. Two subgroups can be formed:

IIa (6 cases) Reticulation of either micronodular or honeycomb types evenly distributed throughout both lungs (Fig. 2).

IIb (5 cases) Irregular pulmonary reticulation with dense linear opacities scattered throughout the lungs.

Type III (5 cases) Thin-walled transradiancies and dense linear opacities, suggesting bullous emphysema associated with linear fibrosis (Fig. 3).

In all patients, the radiographic abnormalities remained unchanged for several years in spite of

Table Radiographic and cardiac features

Case	Radiological group	Frontal QRS vector (a)	Electrocardiographic criteria	Clinical right heart failure
1	I	+ 90	C2	+
2	I	+ 60		
3	I	+ 30		
4	I	+ 30		
5	I	+ 160	C1+C2+C3+C4+C6	+
6	IIa	+ 70		
7	IIa	- 80	C1+C2+C3+C4+C5	+
8	IIa	+ 20		
9	IIa	+ 120	C1+C2+C3+C4+C6	+
10	IIa	+ 10		
11	IIa	+ 90	C2+C3	
12	IIb	+ 30		
13	IIb	0		
14	IIb	+ 120	C1	
15	IIb	0		
16	IIb	+ 30		
17	III	- 30		
18	III	+ 60		
19	III	+ 30		
20	III	+ 60		
21	III	+ 30		

prolonged corticosteroid therapy. Clinical right-sided heart failure was observed in four cases and electrocardiographic patterns suggestive of cor pulmonale were noted in six cases. All cases with clinical right heart failure showed electrocardiographic abnormalities, usually with the association of several criteria. Electrocardiographic changes

were observed in radiological groups I and IIa 5 times out of 11.

ANALYSIS OF CASE 7

A 49-year-old white woman was admitted to hospital in January 1975. She had isolated pulmonary sarcoidosis with dyspnoea on exertion and a bilateral diffuse nodulo-infiltrative appearance on chest radiography with a massive lingular infiltrate; the diagnosis was made by bronchial biopsy and immunological findings. The electrocardiogram showed signs of cor pulmonale (Table). Worsening of her dyspnoea and the rapid onset of clinical heart failure suggested pulmonary embolism. Angiography (Fig. 4) through a venous catheter revealed complete obstruction of the left upper lobe artery and stenosis with secondary recanalisation of the right lower and upper lobe arteries. Death occurred in March 1975.

Necropsy showed numerous calcified paratracheal and interbronchial nodes, which compressed the proximal pulmonary arteries (Fig. 5). The lungs showed fibrotic areas in the upper lobes and a subpleural infarct in the right lower lobe.

Several types of lesion were observed in histological sections. There was severe congestion, the alveolar exudates showing oedema, haemorrhage, and macrophages. On this background two types of focal lesions stood out. The first consisted of

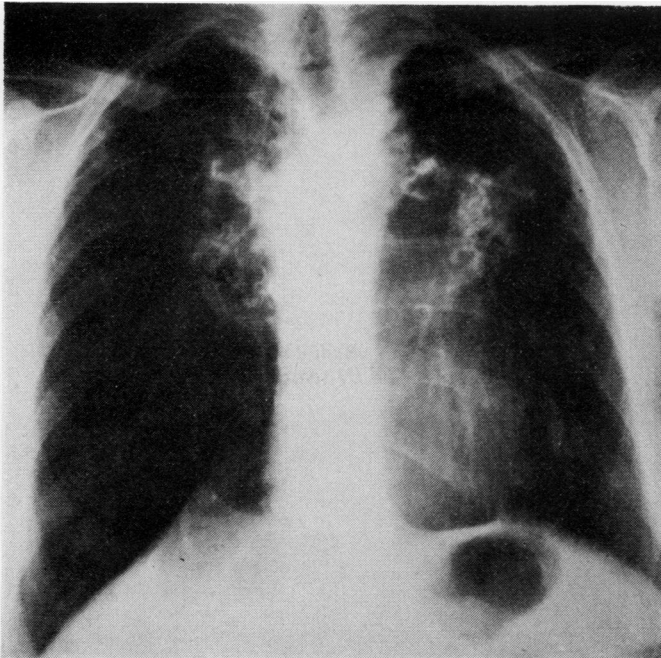


Fig. 1 Radiological picture characteristic of type I (case 2).

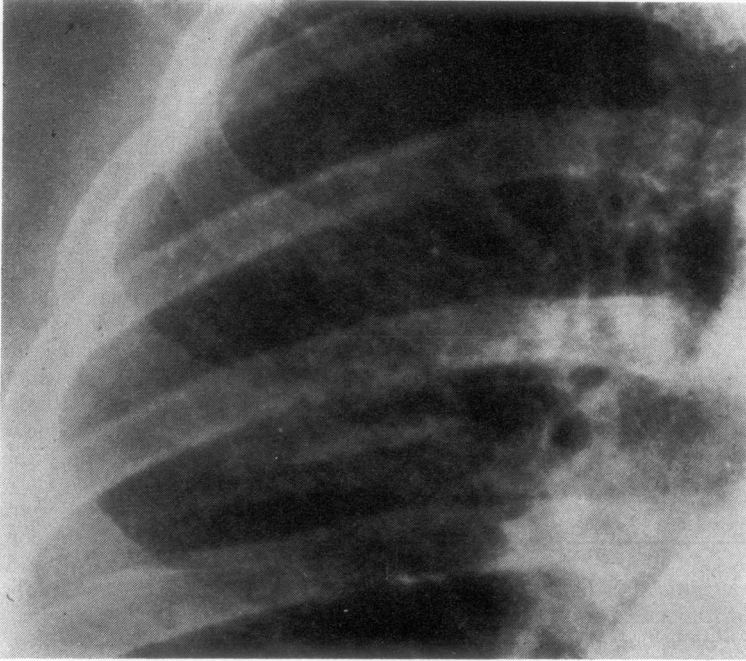


Fig. 2 *Radiological picture characteristic of type II: enlarged detail of diffuse reticulomicro-nodular infiltrates (case 9).*

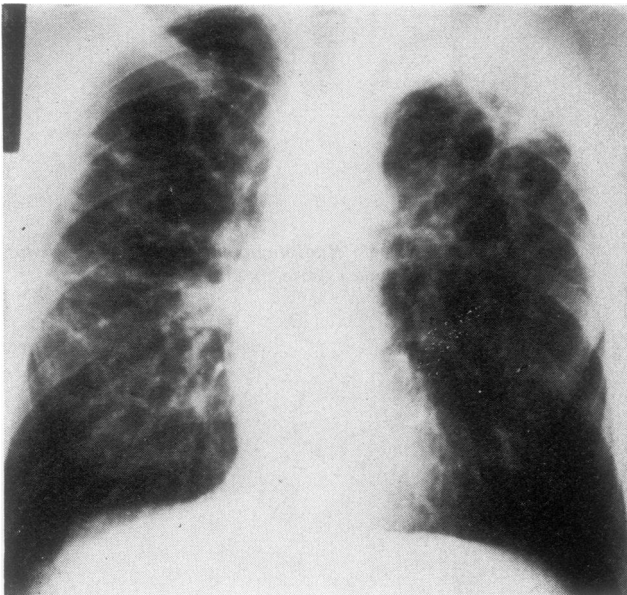


Fig. 3 *Radiological picture characteristic of type III (case 19).*

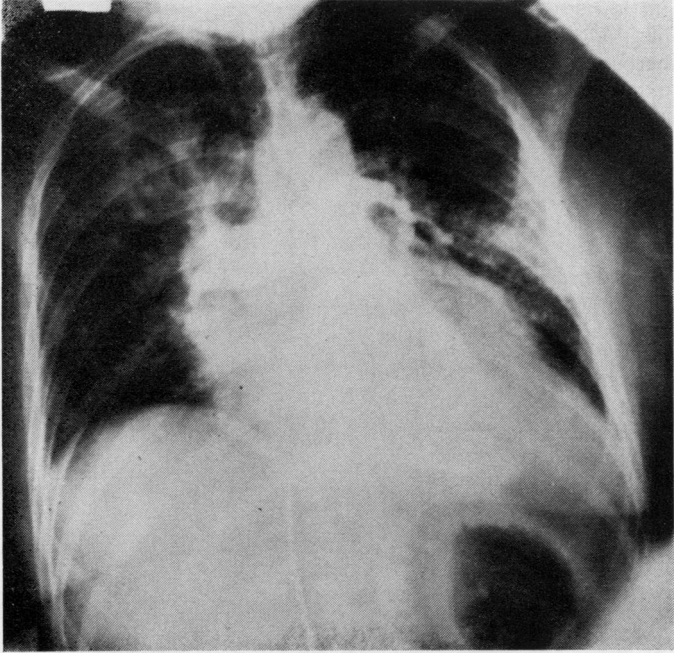


Fig. 4 *Pulmonary arteriogram (postero-anterior view) showing obstruction of pulmonary vessels (case 7).*

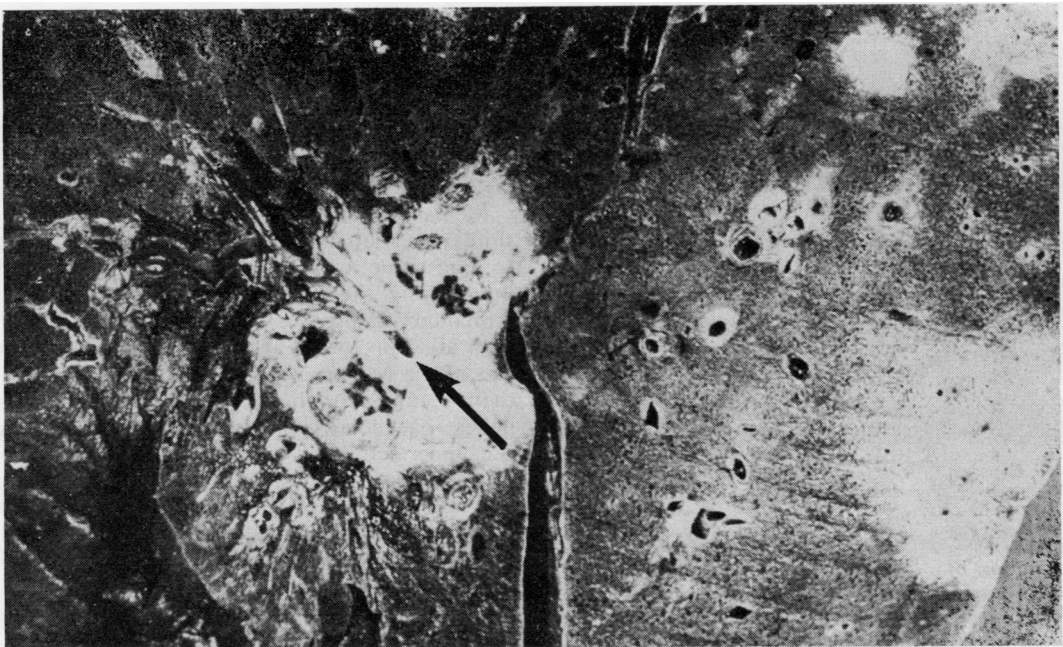

Fig. 5 *Gross section of left lung showing white fibrotic areas with tiny arterial lumina, one of which (arrow) is especially narrowed.*

infarcts, not only the large one in the right lower lobe, but also smaller, more recent ones. The other type of lesion consisted of tuberculoid granulomas without necrosis. They were usually found along the bronchovascular sheaths, invading the bronchial and, to a lesser degree, the vascular walls. They were also numerous at the edges of large fibrotic areas, apparently in pulmonary tissue. However, their proximity to large bronchi and vessels and the presence of a hyalinised border and central anthracotic pigmentation led us to interpret these fibrous areas as hyalinised lymph nodes.

In the walls of large bronchi, follicular lesions at every stage, without any signs of caseous necrosis, were associated with shrinkage of adjoining bronchial lumina with disruption of the bronchial cartilage.

Most vessels exhibited important changes. Their walls were thickened by fibrosis, either loose and cellular, or compact (Fig. 6). The lumen was narrow when present, or was replaced by tiny recanalisation channels (Fig. 7). Embedded in the

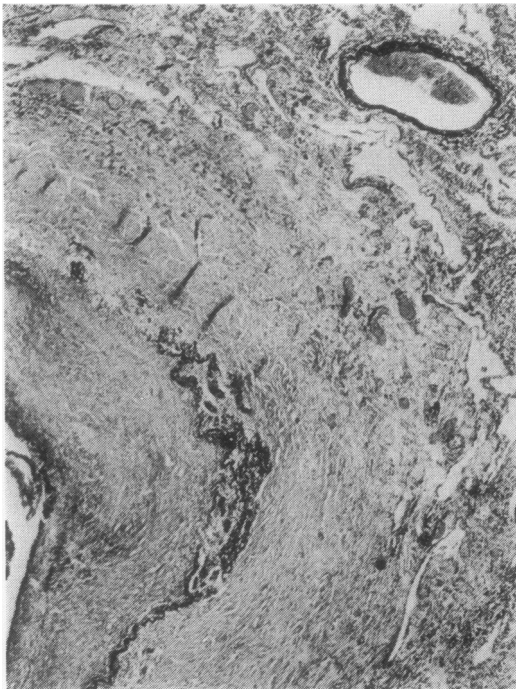


Fig. 6 Part of a large pulmonary artery: the narrow lumen is visible on the left of the picture, with a partially occluding thrombus. The arterial wall is fibrous and thickened, and the black-stained elastic lamina is disrupted by cell aggregates with giant cells (Verhoeff's stain $\times 15$).

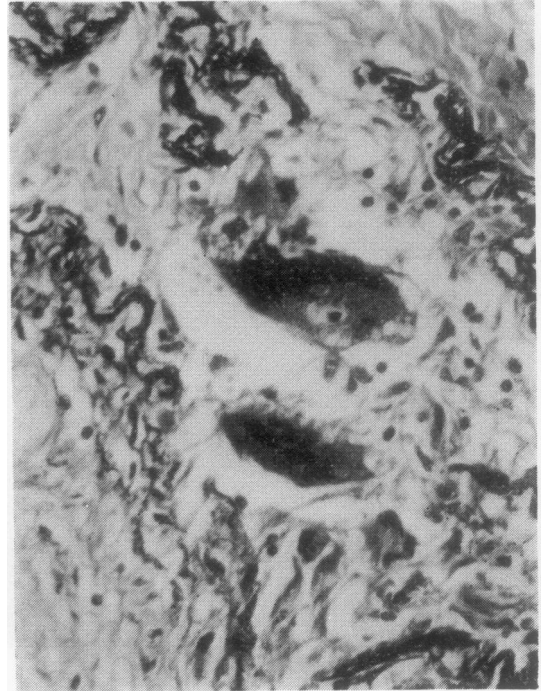


Fig. 7 Higher magnification of Fig. 6, showing recanalisation ($\times 295$).

wall, follicular lesions sometimes disrupted the elastic laminae (Figs 8 to 10).

In larger arteries, there were thrombi of varying age and size adhering to the wall (Fig. 6). In small arteries, lesions were plexiform with several narrow lumina and a disorganised smooth muscle layer (Figs 11 and 12).

Mediastinal lymph nodes had an appearance similar to that of the hyalinised masses attached to lung tissue, which was an additional reason for interpreting the latter as lymph nodes fused to pulmonary tissue.

In addition to the above vascular lesions, there was also a reduction in size of the arteries due to their compression by the hyalinised hilar lymph nodes (particularly the left main pulmonary and the upper left lobe arteries). This vascular compression was further increased by the contractural fibrosis of all this region, causing bronchial distortion and the blending of lymph nodes into neighbouring pulmonary tissue.

Discussion

Clinical manifestations of cor pulmonale are rarely reported in fixed fibro-emphysematous forms of

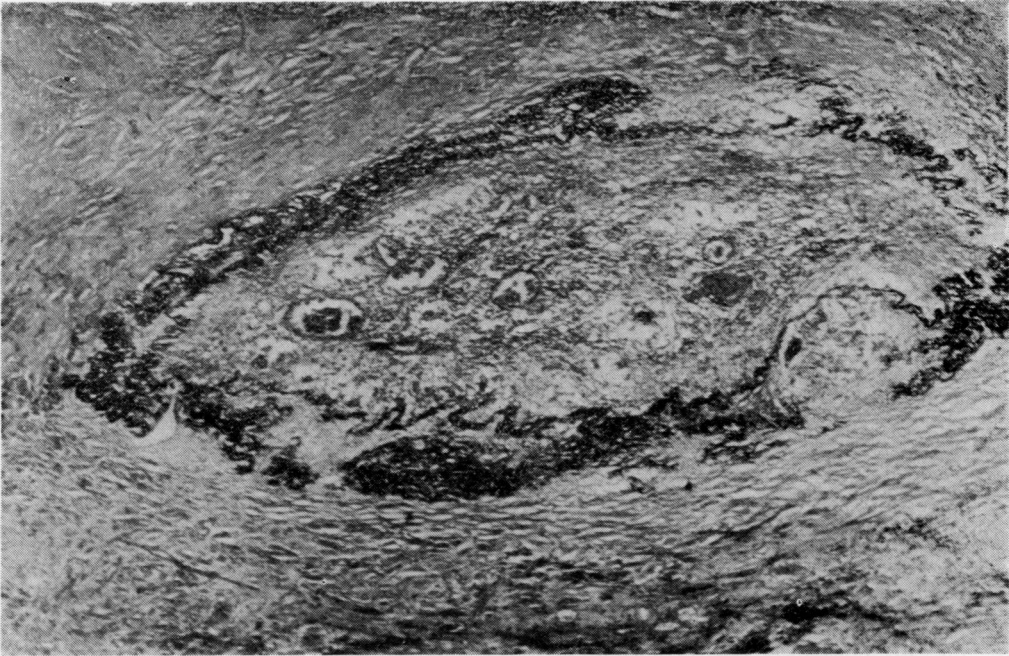


Fig. 8 *Close to a hyalinised area, an arterial lesion with intimal fibrosis and a few recanalisation vessels. Several epithelioid and giant-cell granulomas disrupt or distort the elastic lamina (Verhoeff's stain $\times 40$).*

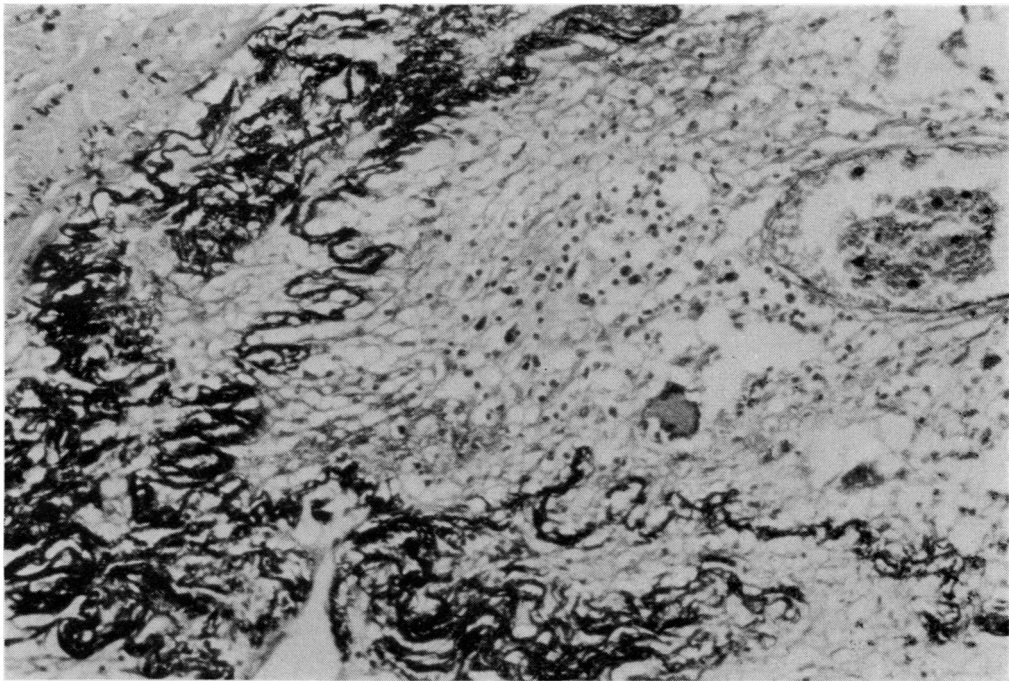


Fig. 9 *Higher magnification of Fig. 8, showing loose cellular infiltrates, giant cells, and changes in the elastic lamina ($\times 165$).*

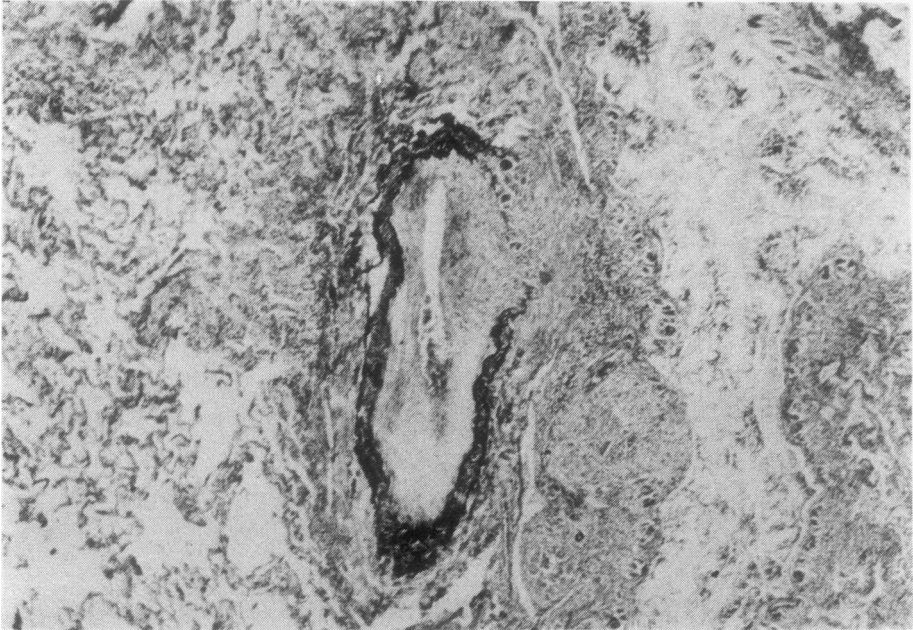


Fig. 10 *Low-power view of a group of follicular lesions involving a bronchus (cut lengthwise, on the right side of the picture) and a narrow artery with a disrupted elastic lamina (Verhoeff's stain $\times 16.5$).*

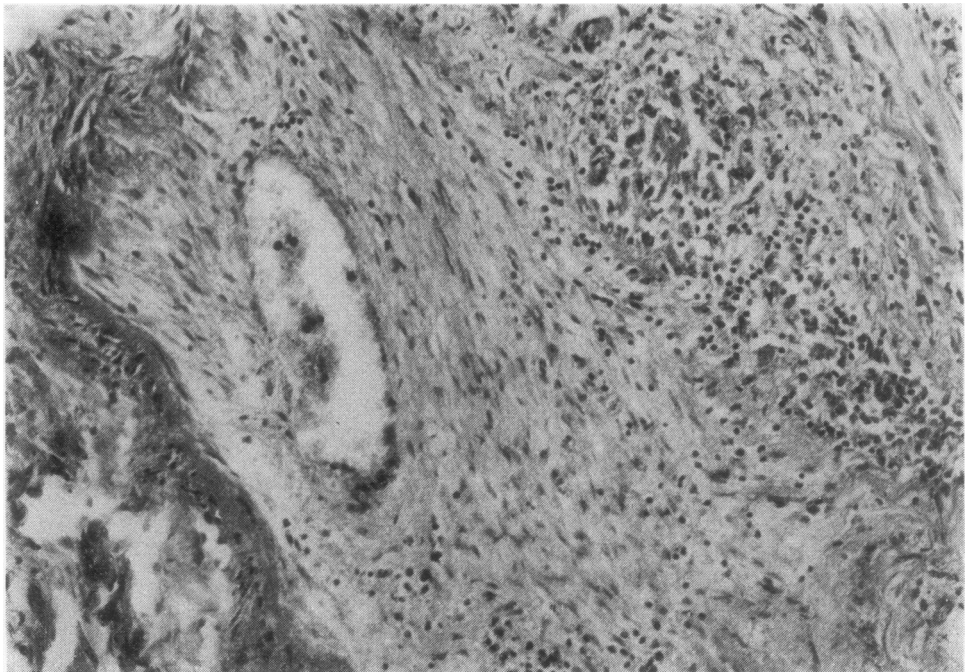


Fig. 11 *Obliquely cut vessel, the wall of which is in close contact with a granuloma (Haematoxylin and eosin $\times 135$).*

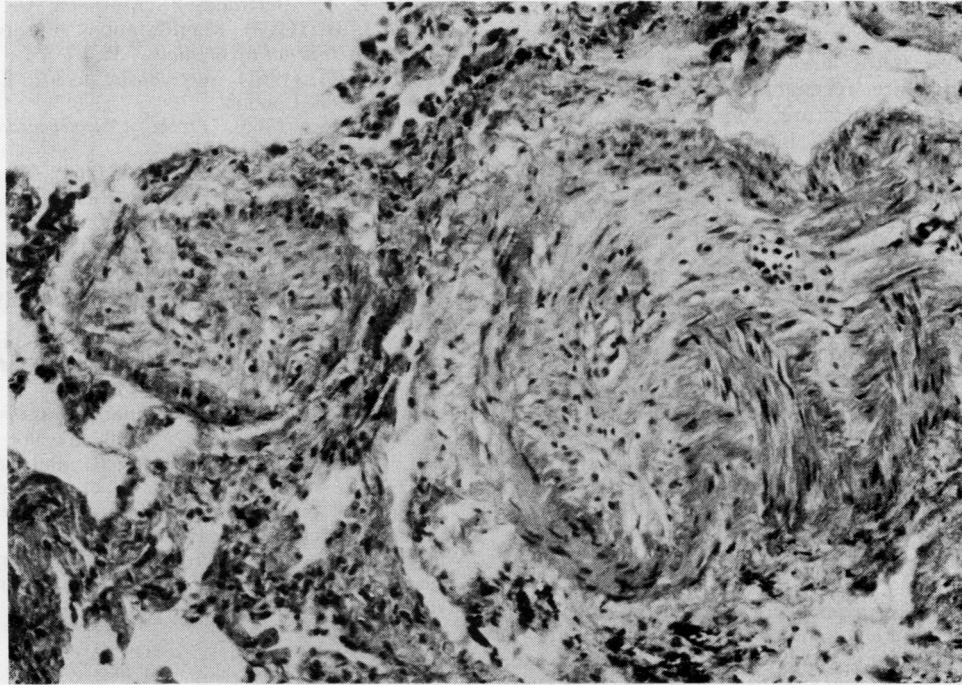


Fig. 12 Plexiform lesion (Haematoxylin and eosin $\times 135$).

pulmonary sarcoidosis. Among 13 patients who died from sarcoid pulmonary fibrosis, Scadding (1967) observed three with clinical right ventricular failure and one with isolated electrocardiographic right ventricular hypertrophy, thus finding evidence of chronic cor pulmonale in 30% of cases. According to this author, the association with chronic bronchitis is an important aetiological factor. Out of 11 necropsies of sarcoid fibrosis, Sones and Israel (1960) observed four cases of chronic cor pulmonale (36%); Mayock *et al.* (1963) noted three cases out of nine deaths. In our group, chronic cor pulmonale manifestations with or without right heart failure were observed in six out of 21 cases (28.6%).

Studies of the pathology of pulmonary hypertension in sarcoidosis have shown in the majority of cases only the small and medium-sized arteries to be clearly affected. Lesions consist of generally incomplete thrombosis provoked by either peribronchovascular fibrosis or granulomatous invasion of the vascular walls (Mallory, 1948; Longcope and Freiman, 1952; Thompson, 1966; Turiaf *et al.*, 1973). Thromboembolism may be superimposed in some cases. On the other hand, involvement of the large branches of the pulmonary artery is exceptional. Schermuly and Behrend (1968) performed pulmonary angiography

on 150 subjects suffering from sarcoidosis and observed modifications in the orientation of the proximal arteries. These modifications were attributed to the fibrosis, but no change in size of the pulmonary vessels provoked by lymph-node compression was noted. The authors did not specify the stage of evolution of the illness (in particular, the presence or absence of mediastinal adenopathies).

Shibel *et al.* (1969) studied 31 subjects suffering from sarcoidosis and noticed abnormalities in peripheral perfusion detected by scintigraphy in two cases where isolated mediastinal adenopathy was present. The authors postulated either the existence of pulmonary impairment undetected by radiography or a decrease in the diameter of the proximal vessels. Westcott and de Graff (1973) reported the case of a 29-year-old coloured man with mediastinal lymph adenopathy. Scintigraphy revealed a perfusion defect of the upper right lobe, suggesting pulmonary embolism. A right pulmonary arteriogram showed compression of the right upper lobe artery by hilar nodes. Eleven months later, the chest radiograph and scintigraphy spontaneously returned to normal. Gordonson *et al.* (1973) reported a case of compression by an enlarged right paratracheal node of the superior vena cava. This was completely

asymptomatic and diagnosed by venacavagram.

Enlarged sarcoid mediastinal lymph nodes can thus compress the large pulmonary vessels. When such nodes are recent and have an essentially granulomatous structure, compression is certainly very exceptional and, in any case, reversible. At the fibroemphysematous stage, when the enlarged nodes have undergone fibrohyaline transformation and are sometimes the site of calcification, irreversible compression of the large pulmonary vessels can be more easily explained. Its frequency is difficult to assess in the absence of angiographic information. In our case 7, the role of lymph nodes in compression and obstruction of the large vessels is particularly evident, but the presence of sarcoid lesions in vascular walls appears to occur also throughout the whole vascular tree.

We are grateful to Mrs. Mazin and Miss Jarland for their skilful technical assistance.

References

- Gordonson, J., Trachtenberg, S., and Sargent, E. N. (1973). Superior vena cava obstruction due to sarcoidosis. *Chest*, **63**, 292-293.
- Longcope, W. T., and Freiman, D. G. (1952). A study of sarcoidosis. *Medicine*, **31**, 1-32.
- Mallory, T. B. (1948). Pathology of pulmonary fibrosis including chronic pulmonary sarcoidosis. *Radiology*, **51**, 468-476.
- Mayock, R. L., Bertrand, P., Morisson, C. E., and Scott, J. H. (1963). Manifestations of sarcoidosis. *American Journal of Medicine*, **35**, 67-89.
- Scadding, J. G. (1967). *Sarcoidosis*, p. 302. Eyre and Spottiswoode, London.
- Schaub, F. A. (1966). *Précis d'Électrocardiographie Clinique*. J. R. Geigy. Bâle.
- Schermuly, W., and Behrend, H. (1968). Die Angiographie der Lungensarkoidose. *Radiologe*, **8**, 116-123.
- Shibel, E. M., Tisi, G. M., and Moser, K. M. (1969). Pulmonary photocoagulation roentgenographic comparisons in sarcoidosis. *American Journal of Roentgenology*, **106**, 770-777.
- Sones, M., and Israel, H. L. (1960). Course and prognosis of sarcoidosis. *American Journal of Medicine*, **29**, 84-93.
- Thompson, J. R. (1966). Vascular changes in sarcoidosis. *Diseases of the Chest*, **50**, 357-361.
- Turiaf, J., Battesti, J. P., Georges, R., and Basset, F. (1973). Le stade III ou stade de fibrose de la sarcoidose pulmonaire. *Revue Française des Maladies Respiratoires*, **1**, 1089-1108.
- Westcott, J. L., and de Graff, C. (1973). Sarcoidosis hilar adenopathy and pulmonary artery narrowing. *Radiology*, **108**, 585-586.

Requests for reprints to: Professor J. P. Battesti, Service de Pneumologie, Hôpital Franco-Musulman, 125 rue de Stalingrad, F 93009 Bobigny, France.