

# Single primitive ventricle with normally related great arteries and atresia of the left A-V valve

E OTERO COTO, J M CAFFARENA RAGGIO, P MALO, C SAINZ, R APARISI, AND J M GOMEZ-ULLATE

*From the Clinica Infantil de la C S "La Fe," Valencia, Spain*

**Otero Coto, E, Caffarena Raggio, J M, Malo, P, Sainz, C, Aparisi, R, and Gomez-Ullate, J M (1978).** *Thorax*, 33, 619-624. **Single primitive ventricle with normally related great arteries and atresia of the left A-V valve.** A child aged 2 years and 9 months was angiocardigraphically diagnosed to have a single ventricle with normally related great arteries and atresia of the left A-V valve. A Blalock-Hanlon procedure and division of a large patent ductus arteriosus were followed by reduction in pulmonary artery pressure, but after operation the patient showed signs of left ventricular failure unresponsive to medical treatment, necessitating pulmonary artery banding. We have found only three similar published cases, and this is the only one with full angiographic documentation.

Common or single ventricle is, according to Macartney *et al* (1976), "that condition in which both A-V valves, or a common A-V valve, are anatomically related to, and communicate actually or potentially with, a single ventricular chamber. If an outlet chamber is present, neither A-V valve annulus is anatomically related to, or communicates actually or potentially with, this chamber." Such a definition is, therefore, applicable to cases of A-V valve atresia in which the atretic valve is anatomically related to, and therefore communicates potentially with, the same common ventricular chamber as the patent A-V valve.

The coexistence of atresia of one A-V valve and single ventricle was reported by Quero in 1970, in a case with normally related great arteries. In that paper the author stated the theoretical basis (the concept of the "topographically homologous ventricle") that supports the real existence of such cases.

Previously, Quero, in 1972, and Cabrera *et al*, in 1974, had reported similar anomalies in cases with l-transposition and d-transposition.

We have found only three cases of single ventricle with outlet chamber and normally related great arteries with atresia of the left A-V valve—the original description by Quero in 1970 and two cases angiographically diagnosed by Macartney *et al* (1976). We found no full angiographic documentation of this anomaly in our review of published work.

## Case report

A girl, aged 2 years and 9 months, was seen for the first time at our institution. There were no known potentially teratogenic factors during pregnancy, and her birth was normal at term. Birth weight was 3600 g. During infancy the patient had frequent episodes of bronchitis, dyspnoea and cyanosis on slight effort, and physical underdevelopment with failure to gain weight.

On examination she was underdeveloped (weight under second percentile; height under tenth percentile), with mild cyanosis when she was crying. Peripheral arterial pulses were normal. The thorax was deformed, with left-sided chest prominence. On auscultation, there was a grade 2/6 systolic murmur maximal at the left fourth intercostal space, followed by a loud single second sound. The liver was palpated 2 cm below the costal margin.

The ECG (fig 1) showed sinus rhythm, a mean frontal QRS axis of  $-105^\circ$ , and combined biatrial and biventricular hypertrophy. Chest radiography showed cardiac enlargement and signs of active and passive pulmonary vascular engorgement. The haematocrit was 42%.

At cardiac catheterisation the heart was studied from the right saphenous vein. The catheter passed through the right atrium to enter a ventricular cavity from which both great vessels were easily catheterised; a patent ductus arteriosus was

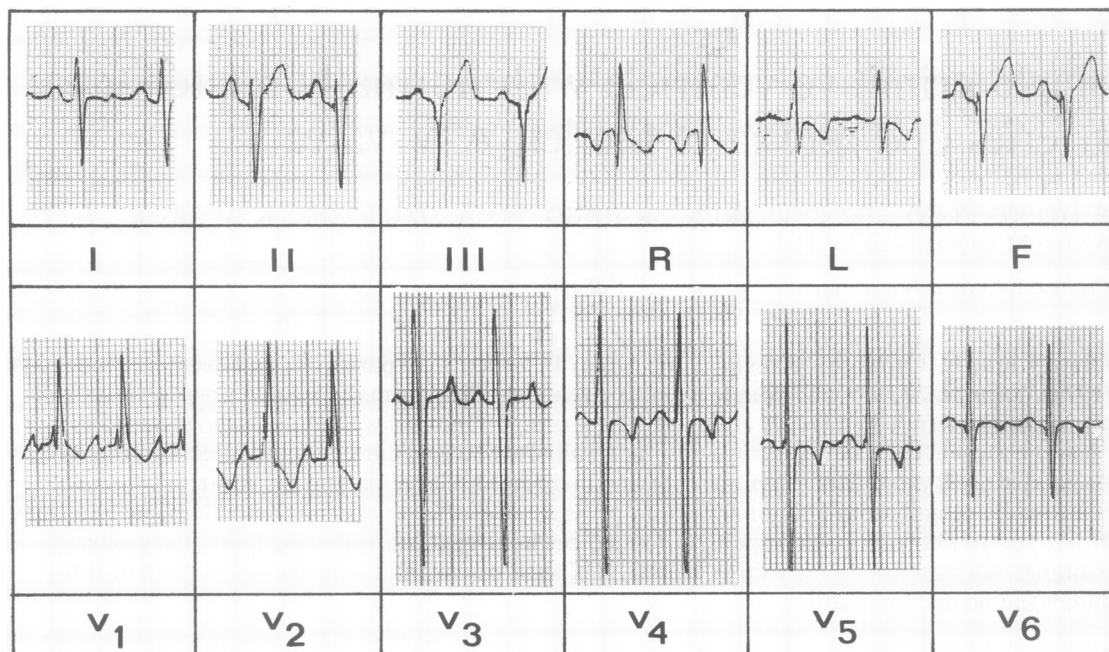


Fig 1 *Electrocardiogram showing abnormal frontal QRS axis and combined biatrial and biventricular hypertrophy.*

traversed. From the right atrium the catheter crossed a patent foramen ovale or small atrial septal defect to enter the left atrium; no ventricle could be reached from this cavity. The pressures and oxygen saturations obtained are shown in table 1. A large rise in oxygen saturation was apparent in the right atrium with similar levels in all other cavities, except in the left atrium. Most outstanding were the high pressures recorded in the pulmonary artery and in the left atrium, as well as the important gradient between both atria.

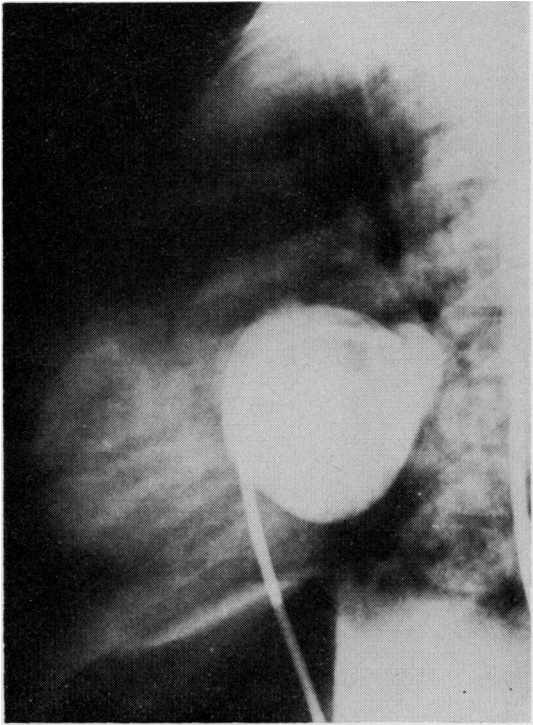
Table 1 *Preoperative haemodynamic data*

Site	Pressure (mmHg)	Oxygen saturation (%)
Superior vena cava		65
Right atrium	20/12 (16)	90
Left atrium	48/24 (34)	96
Ventricle	108/04 (55)	90
Pulmonary artery	104/62 (81)	92
Aorta	102/50 (72)	90
Pulmonary vein	50/26 (38)	98

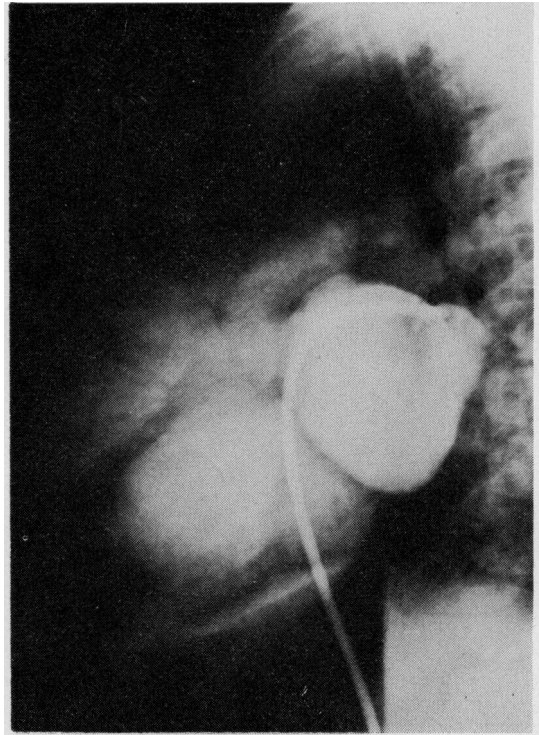
Serial biplane angiocardigrams were performed with injections of contrast material in both atria, the main ventricular chamber, the outlet chamber, pulmonary artery, and aorta. The left atrial injection showed the absence of communication of this

cavity with any ventricle (fig 2a); in later frames the contrast material spilt over into the right atrium and, from this cavity, into a ventricular chamber that was directly related to the left atrium (fig 2b), although there was no communication between them. From the ventricular chamber the contrast medium passed to the aorta and into a large outlet chamber, from which the pulmonary artery arose. Selective main ventricular chamber opacification showed its smooth contour and the origin of the aorta. It was impossible to ascertain the existence of aortic-A-V valve fibrous continuity (fig 3); nevertheless, the aortic valve lay to the right, inferiorly and posteriorly in relation to the pulmonary valve. The outlet chamber was placed in a superoanterior position (figs 4a and b) and showed no apparent relation of this chamber with any A-V valve. It appeared to be separated from both. The aortogram showed a left-sided aortic arch and the presence of a large ductus arteriosus. Injection in the pulmonary artery showed delayed passage of the contrast medium.

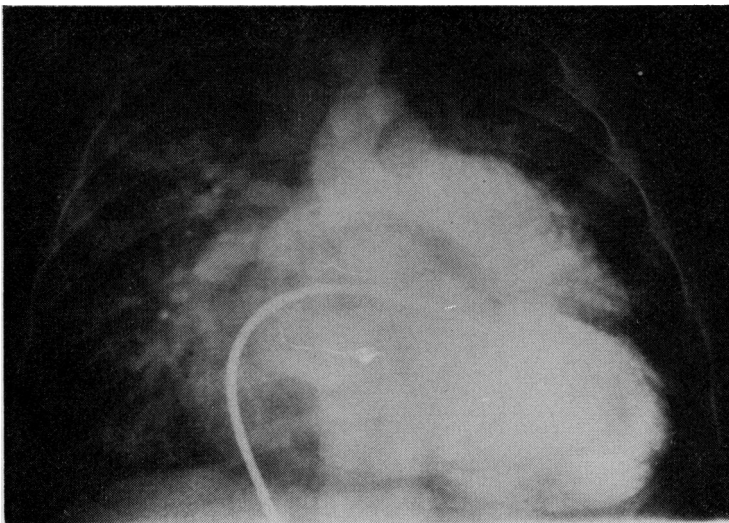
The final catheter diagnosis was primitive ventricle with outlet chamber and normally related great arteries; atresia of the left A-V valve; large patent ductus arteriosus; atrial septal defect; and pulmonary hypertension.



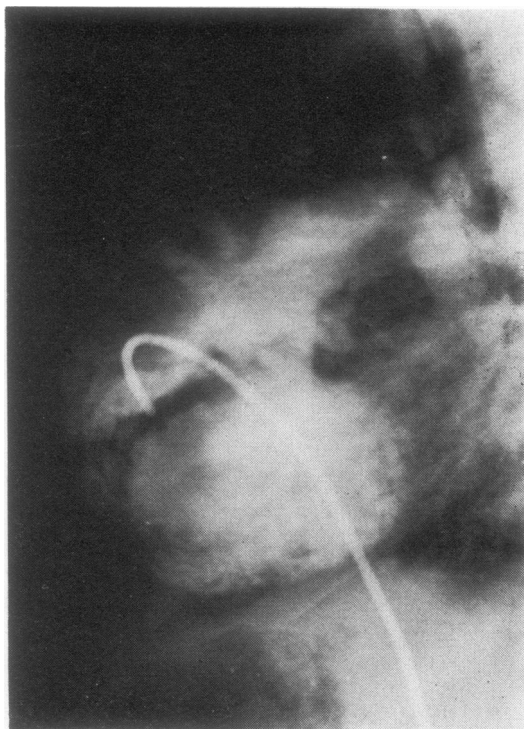
**Fig 2(a)** *Left atrial injection showed absence of communication of this cavity with any ventricle.*



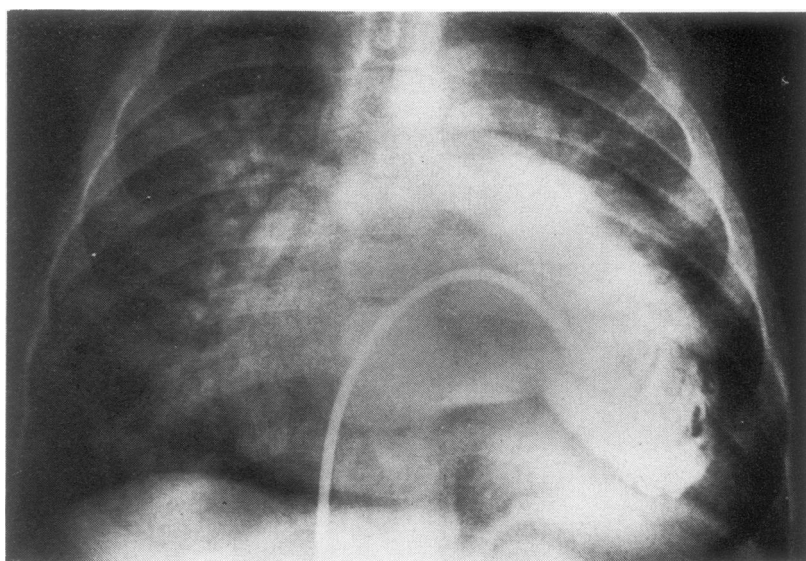
**Fig 2(b)** *But this left atrium was directly related to the main ventricular chamber, opacified through the right atrium.*



**Fig 3** *Selective main ventricular chamber opacification shows :smooth contour of this chamber and its connection with aorta, while pulmonary artery is connected to outlet chamber.*



**Fig 4(a)** *Outlet chamber selective opacification shows its anterior position, without apparent relation with any A-V valve. Great arteries are seen normally related. In contrast to cases with l-looping, the interventricular septum is best seen in profile in this projection.*



**Fig 4(b)** *Outlet chamber selective opacification shows its connection with pulmonary artery. Main chamber, posterior and inferior, clearly extends further to left than outlet chamber, which is anterior, superior, and slightly rightwards.*

A palliative procedure, including division of the ductus and a Blalock-Hanlon atrioseptectomy, was performed. The surgical anatomy was interpreted as supporting the previous diagnosis. Intraoperative pressures after the completion of the procedure showed a fall in pulmonary pressure (systolic 65 mmHg, whereas the systemic was 95 mmHg).

The postoperative course was complicated by signs of left ventricular failure, unresponsive to medical treatment. A second cardiac catheterisation was performed three weeks after the operation. The pressures and oxygen saturations obtained are shown in table 2. The angiocardio-gram suggested pulmonary plethora with a large left-to-right shunt. Pulmonary artery banding was done two days later, leaving a distal pulmonary artery pressure of 40 mmHg. The patient's postoperative course was uneventful, and she was discharged ten days after the second operation. Three months later the child was asymptomatic and had gained 2 kg in weight.

Table 2 Postoperative (pre-banding) haemodynamic data

Site	Pressure (mmHg)	Oxygen saturation (%)
Superior vena cava		67
Right atrium	(10)	94
Left atrium	(10)	95
Ventricle	105/0 (45)	94
Pulmonary artery	85/24 (50)	94
Aorta	105/70 (85)	93

## Discussion

In a heart with atresia of either A-V valve, Quero (1970) considered that the topographically homologous ventricle is the one that would be expected to be situated beneath the atretic valve. With d-loop and left A-V valve atresia, as in the case reported, this ventricle is the left one. Cases in which this ventricle is small and the other ventricle is completely present are not seen as cases of true single ventricle. Nevertheless, cases in which the left ventricle is completely present and the other ventricle is absent or incomplete, are very probably cases of true single ventricle in which atresia of the A-V valve coexists (Quero, 1970).

In our case the position of the rudimentary chamber could be the subject of controversy. Macartney *et al* (1976), reported that in cases of l-transposition, in which l-looping has occurred, this chamber was lateral, while with normally related great vessels, and almost certain d-loop, the

outlet chamber was anterior. According to this statement cases of isolated ventricular inversion with double inlet left ventricle (Freedom *et al*, 1977), which should be differentiated from our case, show good visualisation of the plane of the interventricular septum in the AP plane, while both chambers (main and outlet chamber) are superimposed in the lateral projection. In contrast, our case showed good visualisation of the interventricular septum in the lateral projection, and both chambers were superimposed in the AP projection with the main chamber extending further to the left than the outlet chamber. Thus the anterior, superior, and slightly rightwards position of the outlet chamber, along with the normal relationship of the great arteries and the surgical examination of the external morphology of the heart, suggested the existence of infundibular non-inversion (d-looping) in this case.

The report by Dunkman *et al* (1977) of a case of ventricular inversion without transposition of the great arteries and atresia of the left A-V valve has to be distinguished from the present case. The only useful rule, presented by Macartney *et al* (1976), is that in cases with single ventricle the bulboventricular septum lies largely anterior to the atrioventricular canal and the outlet chamber is remote from both A-V valves, which are only related with the main ventricular chamber; while in the case reported by Dunkman *et al* (1977) the left A-V valve (atretic) was related to the right ventricle and the right A-V valve was related to the left ventricle.

Intraoperative decision of the need for banding can be difficult, because of the particular haemodynamic behaviour of these patients. In our case we believed that the division of the large ductus and the relief of the left atrial obstruction would diminish the pulmonary overload, as was suggested by the intraoperative fall in pulmonary pressures. The fall in pulmonary resistance and pressure increased the left-to-right shunt, however. This led to pulmonary oedema, which necessitated pulmonary artery banding in a second operation.

This case has interesting connotations regarding nomenclature and classification of congenital heart malformations. Previous communications (Otero Coto *et al*, 1976; Otero Coto, 1977; Otero Coto and Quero Jimenez, 1977; Shinebourne *et al*, 1977) have shown the necessity of describing both connections and relations when applying the segmental approach (Van Praagh, 1972) to the study of congenital heart anomalies. We considered that atresia of either A-V valve should be classified as a "potential" (Shinebourne *et al*, 1976) form of one basic type of A-V connection

(concordant, discordant, and double inlet left and right being the basic types), the main anomaly (tricuspid or mitral atresia) being specifically considered as an associated lesion. Obviously, in cases of imperforate atrioventricular valve, this alternative is perfectly reasonable, as the potential connection is easily established. Shinebourne *et al* (1977) and Anderson (1977, personal communication) however, have pointed out that in some cases of A-V valve atresia the potential connection of the affected cavities is not easily established, and thus they created the term absent atrioventricular connection. While thinking that our description has the advantage of being simpler, we think that the use of the term "absent connection" is more accurate from an anatomical viewpoint. This type of connection, however, should be expanded to consider both right and left types of atrioventricular absent connection and, similarly, must be applied to the study of ventriculoarterial connections (Otero Coto and Quero Jimenez, to be published). This can make the proposed method even more complex, and this, we think, should be avoided.

#### References

- Cabrera, A, Azcuna, J I, and Bilbao, F (1974). Single primitive ventricle with D-transposition of the great vessels and atresia of the left A-V valve. *American Heart Journal*, **88**, 225-228.
- Dunkman, W B, Perloff, J K, and Roberts, W C (1977). Ventricular inversion without transposition of the great arteries. A rarity found in association with atresia of the left-sided (tricuspid) atrioventricular valve. *American Journal of Cardiology*, **39**, 226-231.
- Freedom, R M, Nanton, M, and Dische, M R (1977). Isolated ventricular inversion with double inlet left ventricle. *European Journal of Cardiology*, **5**, 63-86.
- Macartney, F J, Partridge, J B, Scott, O, and Deverall, P B (1976). Common or single ventricle. An angiographic and haemodynamic study of 42 patients. *Circulation*, **53**, 543-554.
- Otero Coto, E, Caffarena, J M, Gomez, J M, Peris, J J, and Concha, M. Cirugia de las malposiciones. III Congreso Nacional de Cirugia Cardiovascular, Santiago de Compostela, June 1976.
- Otero Coto, E. *Levoposiciones aorticas sin inversion ventricular*. Tesis Doctoral. Oviedo, 1977.
- Otero Coto, E, and Quero Jimenez, M (1977). Aproximación segmentaria al diagnóstico y clasificación de las cardiopatías congénitas. Fundamentos y utilidad. *Revista española de cardiología*, **30**, 557-566.
- Quero, M (1970). Atresia of the left atrioventricular orifice associated with a Holmes heart. *Circulation*, **42**, 739-744.
- Quero, M (1972). Coexistence of single ventricle with atresia of one atrioventricular orifice. *Circulation*, **46**, 794-798.
- Shinebourne, E A, Macartney, F J, and Anderson, R H (1976). Sequential chamber localization-logical approach to diagnosis in congenital heart disease. *British Heart Journal*, **38**, 327-340.
- Shinebourne, E A, Anderson, R H, Tynan, M, and Macartney, F J. Terminology and nomenclature. II Symposium of the British Heart Foundation, session 1. London, June 1977. In press.
- Van Praagh, R (1972). The segmental approach to diagnosis in congenital heart disease. *Birth Defects: Original Article Series*, **8**, 4-22.

Requests for reprints to: Eduardo Otero Coto, MD, Servicio de Cirugia Cardiovascular, Ciudad Sanitaria "La Fe," Valencia, Spain.